



## PATIENT

Rilla Clayton

## SPECIES

Canine

## BREED

Cavalier King Charles

## SEX

Spayed female

## AGE

9 years

## WEIGHT

7.2 kg

## INTERPRETED BY

Eric Lindquist, DMV  
DABVP, Cert. IVUSS

## IMAGING PERFORMED BY

Dr. Karkanis

## HOSPITAL NAME

Bay City AH

## REFERRING VET

Dr. Karkanis

## INVOICE

69391

## DATE

12/8/25

## PRESENTING CLINICAL SIGNS

History: Hx CHD preventative ultrasound survey occasional intermittent diarrhea. Currently on Biome for prevention and still has flare ups

## ULTRASONOGRAPHIC EXAMINATION OF THE ABDOMEN

### Urinary System

The **urinary bladder** and visible pelvic urethra were unremarkable for the level of repletion presented. The urine, however, did present some mildly echogenic debris consistent with mucous, exfoliated cells from renal or bladder origin, and/or blood clots as these echogenic changes can all present similarly. This is often related to urinary tract infection but may represent simple evidence of exfoliated debris or sterile inflammation. Cystocentesis, urinalysis, +/- culture would be recommended to rule out and define any UTI.

The **kidneys** revealed largely normal size and structure, corticomedullary definition and ratio (cortex 1/3 of medulla) were essentially maintained with some age-related loss of curvilinear patterns regarding the capsule and C/M junction. The cortices presented largely uniform texture with some increased echogenicity expected for this age patient. Medullary structure differed distinctly from that of the cortex. Slight pyelectasia was noted in the left kidney with echogenic debris. The left kidney measured 5.2 cm and pyelectasia measured 0.62 cm. The right kidney measured 5.4 cm.

### Adrenal Glands

Both **adrenal glands** were visualized and recognized as having normal shape, size, position and echogenicity for this breed. The phrenic vasculature, glandular echogenicity and detail were unremarkable. Capsule, cortex, and medullary definition were normal for this age patient. The right kidney measured 1.3 cm at the cranial pole and 0.8 cm at the caudal pole. The left adrenal gland measured 0.4 cm at the caudal pole and 0.5 cm at the cranial pole.

### Spleen

The **spleen** in this patient was mildly enlarged with uniform parenchyma and was folded upon itself. This is a positional variant and is not pathological. There was no evidence of significant disease.

### Liver

The **liver** images from right and left intercostal as well as subcostal views revealed subjectively normal liver size, contour, and structure. Some age-related parenchymal remodeling was noted but likely not clinically significant at this time. Vascular and biliary tracts were of normal volume and no evidence of congestion was noted. Gallbladder sand was noted.



## PATIENT

Rilla Clayton

## SPECIES

Canine

## BREED

Cavalier King Charles

## SEX

Spayed female

## AGE

9 years

## WEIGHT

7.2 kg

## INTERPRETED BY

Eric Lindquist, DMV  
DABVP, Cert. IVUSS

## IMAGING PERFORMED BY

Dr. Karkanis

## HOSPITAL NAME

Bay City AH

## REFERRING VET

Dr. Karkanis

## INVOICE

69391

## DATE

12/8/25

## Gastrointestinal

There was some residual chyme and gas was noted in the **stomach**, yet not pathological. This is consistent with post prandial presentation. Transit of chyme into the small intestine was normal. Curvilinear patterns were maintained throughout the GI tract. No evidence of pathology. Small and large intestine demonstrated normal luminal chyme and stool consistency respectively. No obstructive or overt infiltrative disease was noted. No associated abnormal lymphatic activity was noted.

## Pancreas

The base and limbs of the **pancreas** were observed to be largely isoechoic to surrounding omental fat. Pancreatic duct and capsular contour were acceptably normal and parenchyma respected normal curvilinear patterns. No overt evidence of active inflammatory or neoplastic disease was noted.

## ULTRASONOGRAPHIC FINDINGS

Structurally normal GI tract with post prandial presentation.

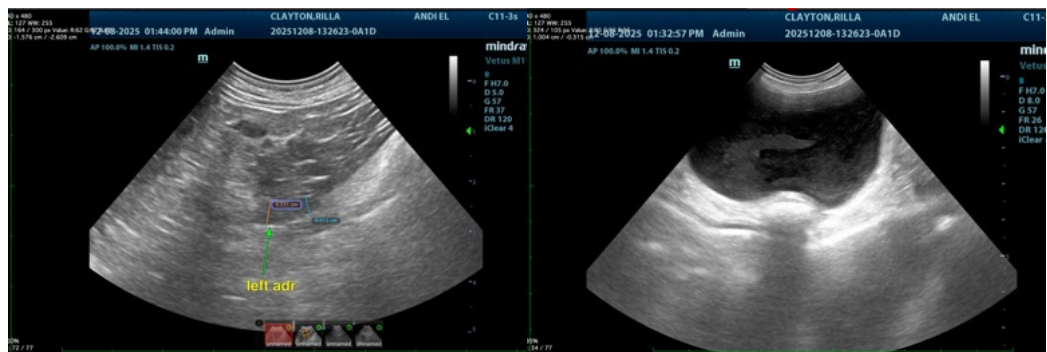
Bladder debris and left renal pyelectasia, potential low-grade pyelonephritis.

Age related abdominal changes were noted otherwise.

## INTERPRETATION OF THE FINDINGS & FURTHER RECOMMENDATIONS

Full urinary work up is warranted. The cause of diarrhea is unclear.

Differentials for diarrhea include occult parasitism. Dietary indiscretion, dietary intolerance, antibiotic responsive colitis, intestinal dysbiosis and occult Addison's should all be considered as causes of diarrhea in this patient. A hydrolyzed diet trial may be in this patient's best interest +/- probiotics. 24-hour NPO and reintroduction of bland diet indicated. I recommend a baseline cortisol or ACTH stimulation test, a fresh fecal smear and fecal floatation analysis if not already performed





**PATIENT**

Rilla Clayton

**SPECIES**

Canine

**BREED**

Cavalier King Charles

**SEX**

Spayed female

**AGE**

9 years

**WEIGHT**

7.2 kg

**INTERPRETED BY**

Eric Lindquist, DMV  
DABVP, Cert. IVUSS

**IMAGING PERFORMED BY**

Dr. Karkanis

**HOSPITAL NAME**

Bay City AH

**REFERRING VET**

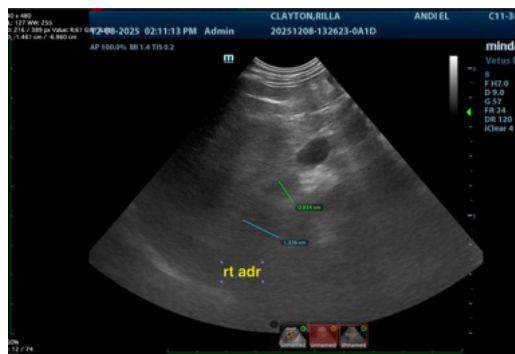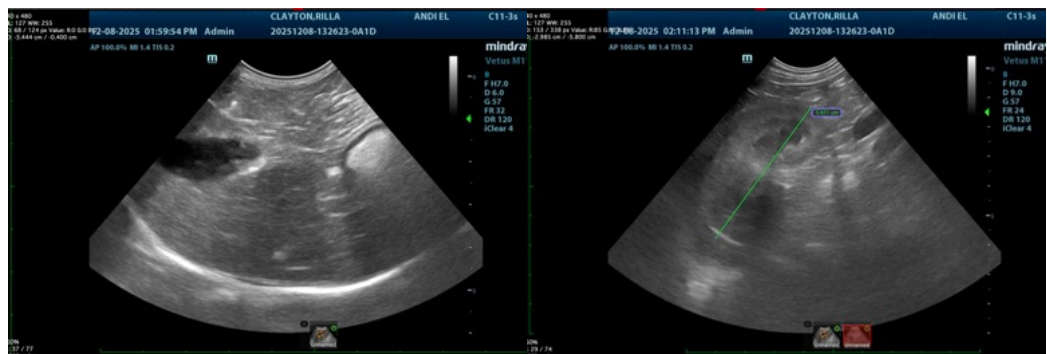
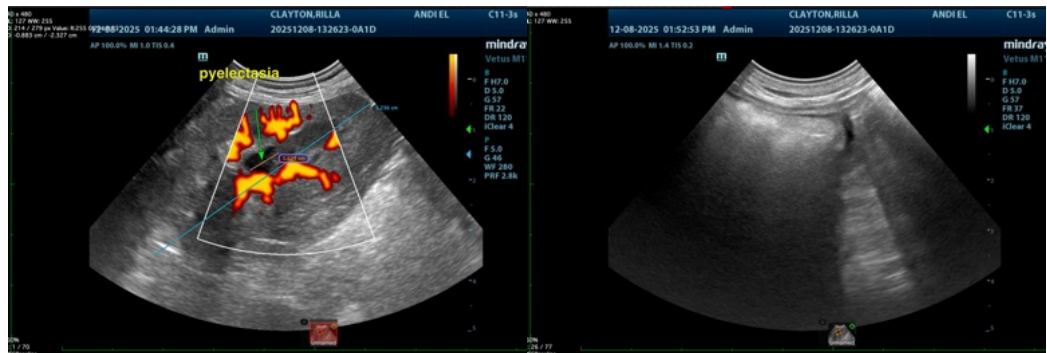
Dr. Karkanis

**INVOICE**

69391

**DATE**

12/8/25



The information and recommendations provided are based on the images presented by the referring veterinarian/sonographer. No evaluation can be communicated regarding pathology that was not visible in the image/video clips provided.

Thank you for this referral. If the clinical or image interpretation does not parallel your findings or if I can be of any further assistance please contact me.

Eric Lindquist, DMV, DABVP (CFM), Cert. IVUSS, CEO of SonoPath.com

[info@SonoPath.com](mailto:info@SonoPath.com)