

**DATE**

12/8/21

**PRESENTING CLINICAL SIGNS**

History: Kidney issues? Urinating abnormally.

Previously diabetic.

**PATIENT**

Current Medications: Clavamox DROPS 1 ML PO BID; Prazosin 0.5 MG 1 TAB PO BID.

Date of Previous IntraPet Ultrasound: No previous IntraPet scans.

Mr. Donkey Weaver

Sedation: Not required to complete full diagnostic ultrasound.

Stat Report: Not requested.

**SPECIES**

Feline

**ULTRASONOGRAPHIC EXAMINATION OF THE ABDOMEN****Urinary System**

The **urinary bladder**, trigone, and pelvic urethra presented normal thicknesses and normal tone. The ureters were not visible which is normal. No uroliths or sediment were visualized and anechoic urine was present. No evidence of inflammatory or neoplastic changes was noted. Ureteral papillae were normal.

**BREED**

Domestic Shorthair

The **kidneys** revealed largely normal size and structure, corticomedullary definition and ratio (cortex 1/3 of medulla) were essentially maintained with some age-related loss of curvilinear patterns regarding the capsule and C/M junction. The cortices presented largely uniform texture with some increased echogenicity expected for this age patient. Medullary structure differed distinctly from that of the cortex. The left kidney measured 3.08 cm with pyelectasia that measured 0.52 cm. The right kidney measured 3.39 cm with pyelectasia that measured 0.64 cm.

**SEX**

Neutered male

**AGE**

7/9/04

**WEIGHT**

7 lbs

**Adrenal Glands**

Both **adrenal glands** were visualized and recognized as having normal shape, size, position and echogenicity for this breed. The phrenic vasculature, glandular echogenicity and detail were unremarkable. Capsule, cortex, and medullary definition were normal for this age patient.

**INTERPRETED BY**Eric Lindquist, DMV  
DABVP, Cert. IVUSS**Spleen**

The **spleen** was irregularly enlarged and mildly irregular in contour measuring up to 1.3 cm in width.

**IMAGING PERFORMED BY**

Rachel Brillhart RDMS

**Liver**

The **liver** images from right and left intercostal as well as subcostal views revealed subjectively normal liver size, contour, and structure. Some age-related parenchymal remodeling was noted but likely not clinically significant at this time. Vascular and biliary tracts were of normal volume and no evidence of congestion was noted. The gallbladder presented some dependent debris with essentially normal contour. The cystic and common bile ducts were normal. No overt evidence of active inflammatory, infiltrative or regenerative pathology was noted but should be paired with current or past LE elevations regarding any clinical significance to this presentation. The hepatic lymph nodes were unremarkable.

**HOSPITAL NAME**

Mt Airy AH

**REFERRING VET**

Dr. Atchley

**Gastrointestinal**

The **gastrointestinal tract** revealed minor variable thickening and echogenic submucosal changes most consistent with low grade end result of chronic GI disease such as IBD and may be related to malassimilation of nutrients if any weight loss is present. No obvious neoplastic patterns were noted and luminal content as unremarkable. The mesenteric lymph nodes were reactive and measured 1.5 x 0.3 cm.

**INVOICE****Pancreas**

The base and limbs of the **pancreas** were observed to be largely isoechoic to surrounding omental fat. Some parenchymal remodeling, however, with mild deviation from curvilinear normalcy was observed. Pancreatic

duct and capsular irregularities were present consistent with age related changes. If pain upon imaging (+ Murphy sign) was present or if the patient is focally painful in subxiphoid palpation then low-grade smoldering chronic pancreatitis should be suspected.

### ULTRASONOGRAPHIC FINDINGS

Moderate degenerative renal changes.

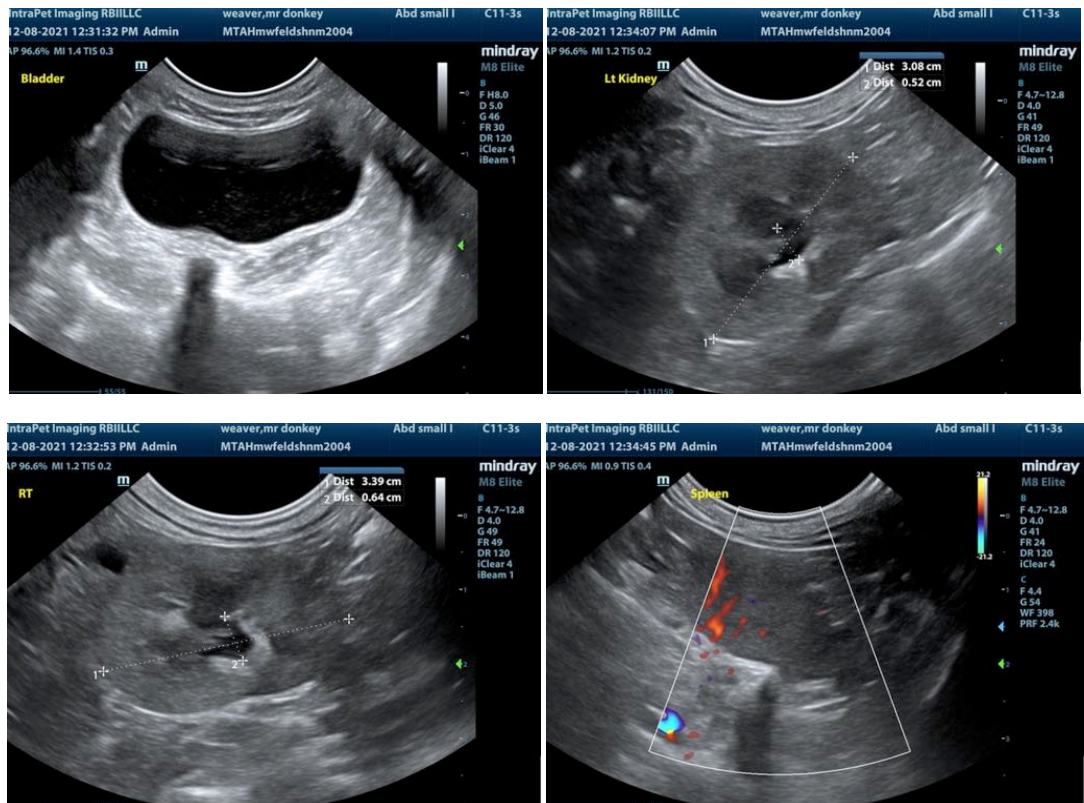
Splenic enlargement. May be owing to early infiltrative disease or potential stable splenic torsion.

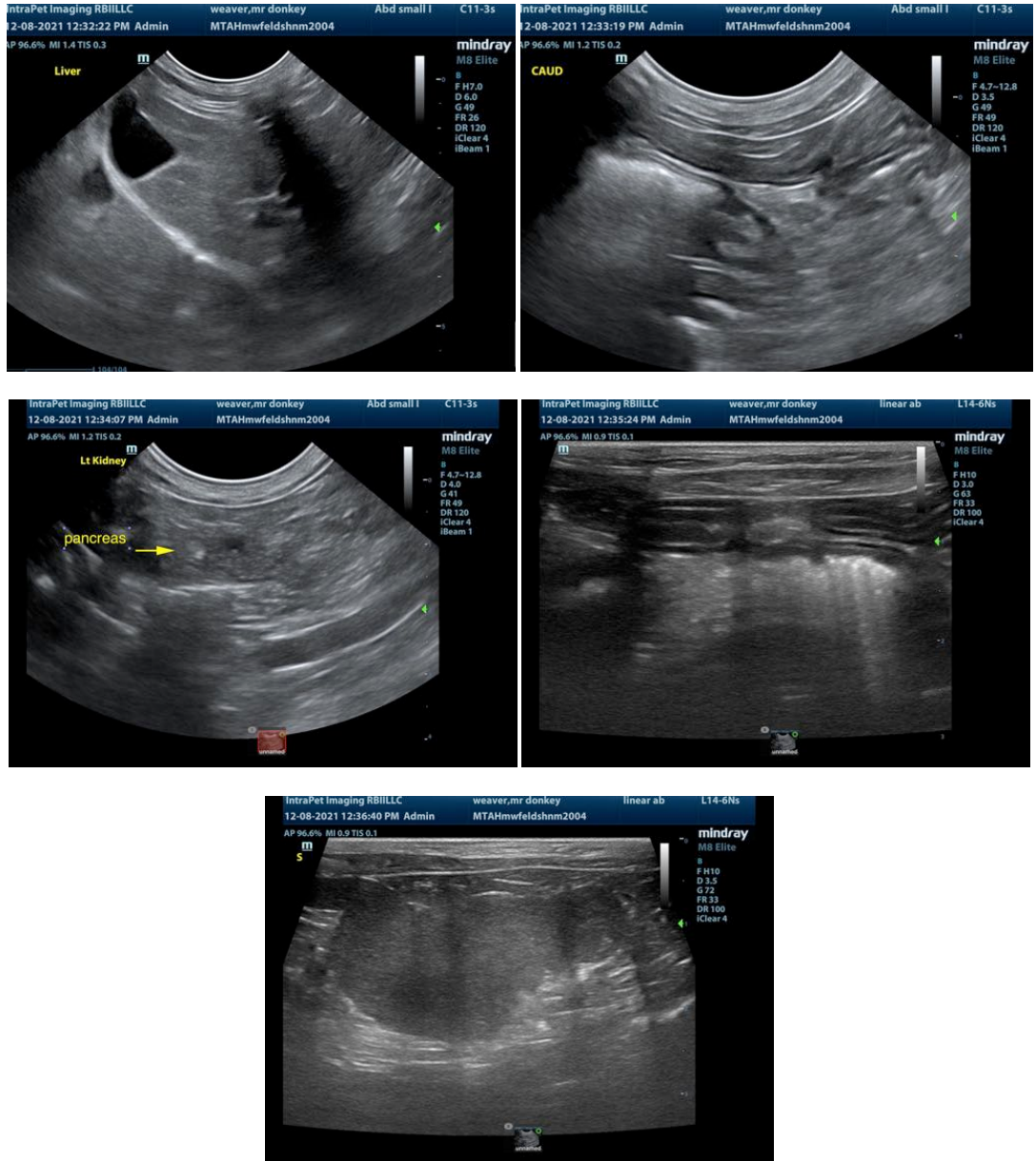
Mild hepatic remodeling.

Enlarged mesenteric lymph nodes.

### INTERPRETATION OF THE FINDINGS & FURTHER RECOMMENDATIONS

If any weight loss is an issue then FNA of the spleen would be indicated. Full urinary work-up is warranted. The changes are largely expected for this age patient. The pyelectasia may be owing to pelvic scarring or possibility of underlying urinary tract infection. Blood flow to the kidneys appeared to be adequate. FNA of the spleen is strongly encouraged or direct splenectomy and GI biopsies could be justified as well.





The information and recommendations provided are based on the images presented by the referring veterinarian. No evaluation can be communicated regarding pathology that was not visible in the image/video clips provided.

Thank you for this referral. If the clinical or image interpretation does not parallel your findings or if I can be of any further assistance please contact me.

Eric Lindquist, DMV, DABVP, Cert. IVUSS, CEO of SonoPath.com  
 Eric.Lindquist@SonoPath.com