



PATIENT PRESENTING CLINICAL SIGNS

Milo Bond History: Has been having vomiting issues and not eating well for about 6 weeks. Has been treated with i/d, Cerenia, and metronidazole and vomiting persists. Chem/CBC/UA-Unremarkable. ACTH Stim test not consistent with Addison's Disease Cobalamin level normal, Folate-Normal; PSL-Normal; TLI >50 (5-35) Fecal exam- No parasites seen

SPECIES

Canine

ULTRASONOGRAPHIC EXAMINATION OF THE ABDOMEN

BREED Urinary System

Shih Tzu The **urinary bladder**, trigone, and pelvic urethra presented normal thicknesses and normal tone. The ureters were not visible which is normal. No uroliths or sediment were visualized and anechoic urine was present. No evidence of inflammatory or neoplastic changes was noted. Ureteral papillae were normal.

SEX

Neutered male

AGE

2 years

The **kidneys** revealed normal size and structure, corticomedullary definition and ratio for this age. The cortices presented largely uniform texture with normal echogenic relationship to liver and spleen. Medullary structure differed distinctly from the cortex and no evidence of pelvic dilation was present. The capsules were acceptably uniform without significant irregularities. The right kidney measured 4.24 cm. The left kidney measured 4.08 cm.

WEIGHT

19.7 lbs

Adrenal Glands

Both **adrenal glands** were visualized and recognized as having normal shape, size, position and echogenicity for this breed. The phrenic vasculature, glandular echogenicity and detail were unremarkable. Capsule, cortex, and medullary definition were normal for this age patient.

INTERPRETED BY

Eric Lindquist, DMV DABVP, Cert. IVUSS

IMAGING PERFORMED BY

Dr. Boley

Spleen

The **spleen** presented a smooth homogeneous parenchyma hyperechoic to liver and renal cortical parenchyma. The capsule was smooth without noticeable expansion or deviation from within the spleen or adjacent pathology. The splenic vasculature demonstrated normal volume without signs of congestion or thrombosis. No sonographic evidence of acute or chronic inflammatory, neoplastic, or infarctual changes was noted.

HOSPITAL NAME

Animal Hospital of Colorado Springs

REFERRING VET

Dr. Boley

Liver

The **liver** images submitted revealed subjectively normal liver size, contour, and structure. Parenchymal echogenicity was naturally coarse and hypoechoic to the spleen. Vascular and biliary tracts were of normal volume with no evidence of congestion. The gallbladder presented acceptably thin walls with primarily anechoic content. The cystic and common bile ducts were normal. No pathological hepatic lymphadenopathy was evident. No overt structural evidence of inflammatory, infiltrative or regenerative pathology was evident.

INVOICE

94427

DATE

12/8/21



PATIENT *Gastrointestinal*

Milo Bond The **stomach** revealed gastric fluid and normal wall thickness. Hyperperistalsis was present. There was some retention of chyme. The small intestine was empty.

SPECIES

Canine *Pancreas*

The base and limbs of the **pancreas** were observed to be largely isoechoic to surrounding omental fat. Pancreatic duct and capsular contour were acceptably normal and parenchyma respected normal curvilinear patterns. No overt evidence of active inflammatory or neoplastic disease was noted.

BREED

Shih Tzu

SEX

ULTRASONOGRAPHIC FINDINGS

Neutered male

Post prandial presentation.

Possible mild gastritis.

AGE

2 years

INTERPRETATION OF THE FINDINGS & FURTHER RECOMMENDATIONS

WEIGHT

19.7 lbs

There was no overt evidence of pancreatitis. However, this cannot be completely ruled out. Given that Addison's has reportedly been completely ruled out in this patient then a clinical trial of the following can be considered. Underlying food intolerance may be an issue.

INTERPRETED BY

Helicobacter/Gastritis protocol

Eric Lindquist, DMV
DABVP, Cert. IVUSS

A clinical trial of **Zithromax (Dogs: 5-10 mg/kg p.o. q24h**. May increase dosing interval to q48h after 3-5 days of treatment), **Metronidazole (10-20 mg/kg p.o. b.i.d.)**, **Sucralfate (0.5-2 g/dog PO)** and **Omeprazole (1 mg/kg p.o. s.i.d.)** over the next 3 weeks along with a **novel-protein or hydrolyzed diet** with slurry feeding b.i.d./t.i.d. over the next 2-4 days and then increase to canned diet bid. Dry food should be avoided over the next 4 weeks. A recheck sonogram to assess GI improvement or progression would be ideal in 4 weeks.

IMAGING PERFORMED BY

Dr. Boley

HOSPITAL NAME

Animal Hospital of
Colorado Springs

REFERRING VET

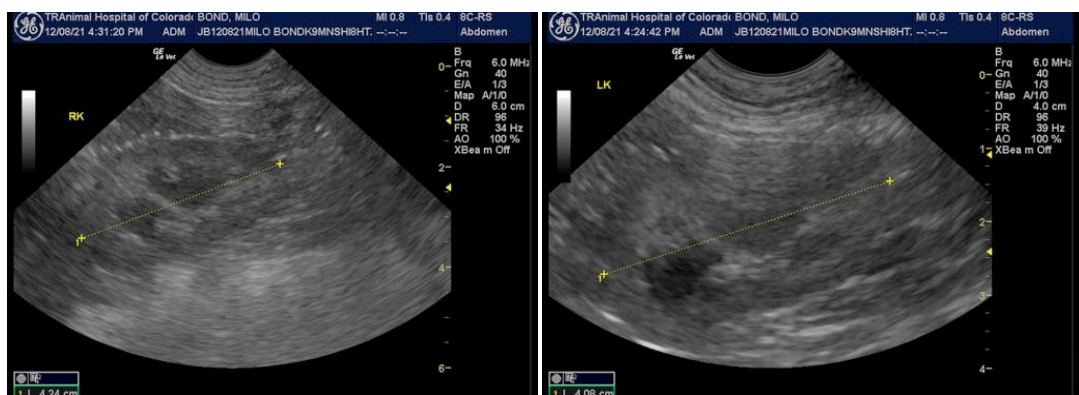
Dr. Boley

INVOICE

94427

DATE

12/8/21





PATIENT

Milo Bond

SPECIES

Canine

BREED

Shih Tzu

SEX

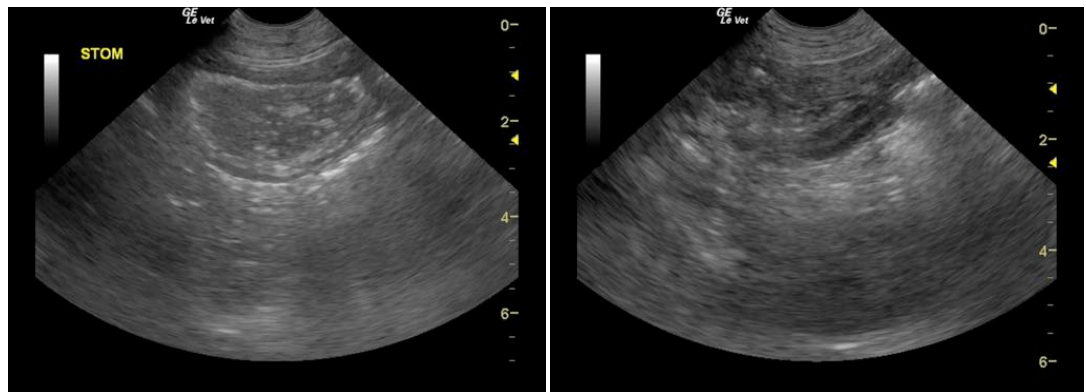
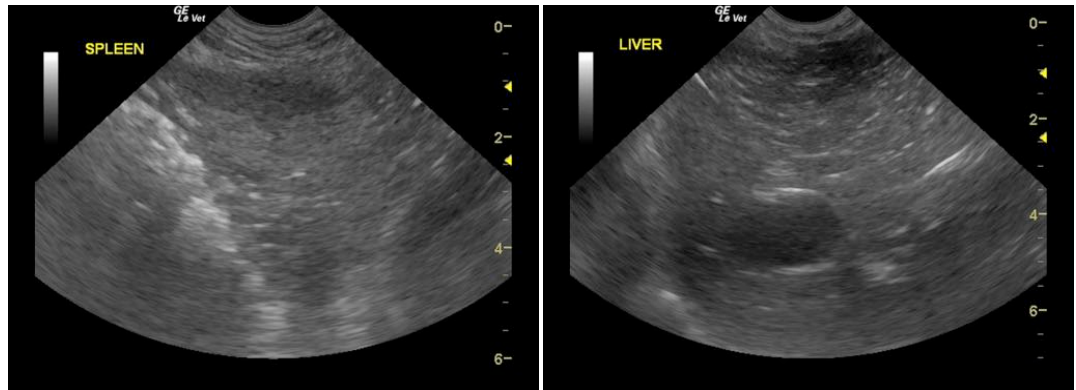
Neutered male

AGE

2 years

WEIGHT

19.7 lbs



INTERPRETED BY

Eric Lindquist, DMV
DABVP, Cert. IVUSS

IMAGING PERFORMED BY

Dr. Boley

HOSPITAL NAME

Animal Hospital of
Colorado Springs

REFERRING VET

Dr. Boley

INVOICE

94427

DATE

12/8/21

The information and recommendations provided are based on the images presented by the referring veterinarian. No evaluation can be communicated regarding pathology that was not visible in the image/video clips provided.

Thank you for this referral. If the clinical or image interpretation does not parallel your findings or if I can be of any further assistance please contact me.

Eric Lindquist, DMV, DABVP, Cert. IVUSS, CEO of SonoPath.com
info@SonoPath.com