

**PATIENT**

Luna DeFelice

**PRESENTING CLINICAL SIGNS**

History: just Dx'ed ITP, Rickettsial disease found on CBC pathology. Chronically elevated WBC. On prednisone, atopica  
Abnormal PE/Chem/CBC/UA Results: decreased platelets

**SPECIES**

Canine

**ULTRASONOGRAPHIC EXAMINATION OF THE ABDOMEN**

**Urinary System**

**BREED**

French Bulldog

The **urinary bladder**, trigone, and pelvic urethra presented normal thicknesses and normal tone. The pelvic urethra was imaged 2.0 cm beyond the cystourethral junction. The ureters were not visible which is normal. No uroliths or sediment were visualized and anechoic urine was present. No evidence of inflammatory or neoplastic changes was noted. Ureteral papillae were normal.

**SEX**

Intact Female

The uterus was mildly thickened. This may be owing to active heat cycle and measured 0.8 cm.

**AGE**

10 months

The **kidneys** revealed normal size and structure, corticomedullary definition and ratio for this age. The cortices presented largely uniform texture with normal echogenic relationship to liver and spleen. Medullary structure differed distinctly from the cortex and no evidence of pelvic dilation was present. The capsules were acceptably uniform without significant irregularities. The right kidney measured 5.74 cm. The left kidney measured 5.85 cm.

**WEIGHT**

21 lbs

**Adrenal Glands**

Both **adrenal glands** were visualized and recognized as having normal shape, size, position and echogenicity for this breed. The phrenic vasculature, glandular echogenicity and detail were unremarkable. Capsule, cortex, and medullary definition were normal for this age patient. The left adrenal gland measured 1.61 x 0.42 cm at the caudal pole and 0.35 cm at the cranial pole. The right adrenal gland measured 1.74 x 1.18 cm at the cranial pole and 0.62 cm at the caudal pole.

**INTERPRETED BY**

Eric Lindquist, DMV  
DABVP, Cert. IVUSS

**IMAGING PERFORMED BY**

Diane McFadden, RVT

**Spleen**

The **spleen** presented a smooth homogeneous parenchyma hyperechoic to liver and renal cortical parenchyma. The capsule was smooth without noticeable expansion or deviation from within the spleen or adjacent pathology. The splenic vasculature demonstrated normal volume without signs of congestion or thrombosis. No sonographic evidence of acute or chronic inflammatory, neoplastic, or infarctual changes was noted.

**HOSPITAL NAME**

Rockaway

**INVOICE**

94406

**Liver**

The **liver** images submitted revealed subjectively normal liver size, contour, and structure. Parenchymal echogenicity was naturally coarse and hypoechoic to the spleen. Vascular and biliary tracts were of normal volume with no evidence of congestion. The gallbladder presented acceptably thin walls with primarily anechoic content. The cystic and common bile ducts were normal. No pathological hepatic lymphadenopathy was evident. No overt structural evidence of inflammatory, infiltrative or regenerative pathology was evident.

**DATE**

12/8/21



**PATIENT** *Gastrointestinal*

Luna DeFelice The **pylorus** was mildly thickened in this patient with prominent mucosal folds. There was no evidence of foreign body. The small intestines and colon were unremarkable.

**SPECIES**

Canine

*Pancreas*

The base and limbs of the **pancreas** were observed to be largely isoechoic to surrounding omental fat. Pancreatic duct and capsular contour were acceptably normal and parenchyma respected normal curvilinear patterns. No overt evidence of active inflammatory or neoplastic disease was noted.

**BREED**

French Bulldog

**SEX**

**ULTRASONOGRAPHIC FINDINGS**

Intact Female

Pyloric mucosal hypertrophy.

**AGE**

**INTERPRETATION OF THE FINDINGS & FURTHER RECOMMENDATIONS**

10 months

I recommend a fresh fecal smear and fecal floatation analysis. Broad spectrum antiparasitic protocol and b.i.d. canned food feedings is recommended if any GI clinical signs are present. Otherwise, unremarkable abdomen.

**WEIGHT**

21 lbs

**INTERPRETED BY**

Eric Lindquist, DMV  
DABVP, Cert. IVUSS

**IMAGING PERFORMED BY**

Diane McFadden, RVT

**HOSPITAL NAME**

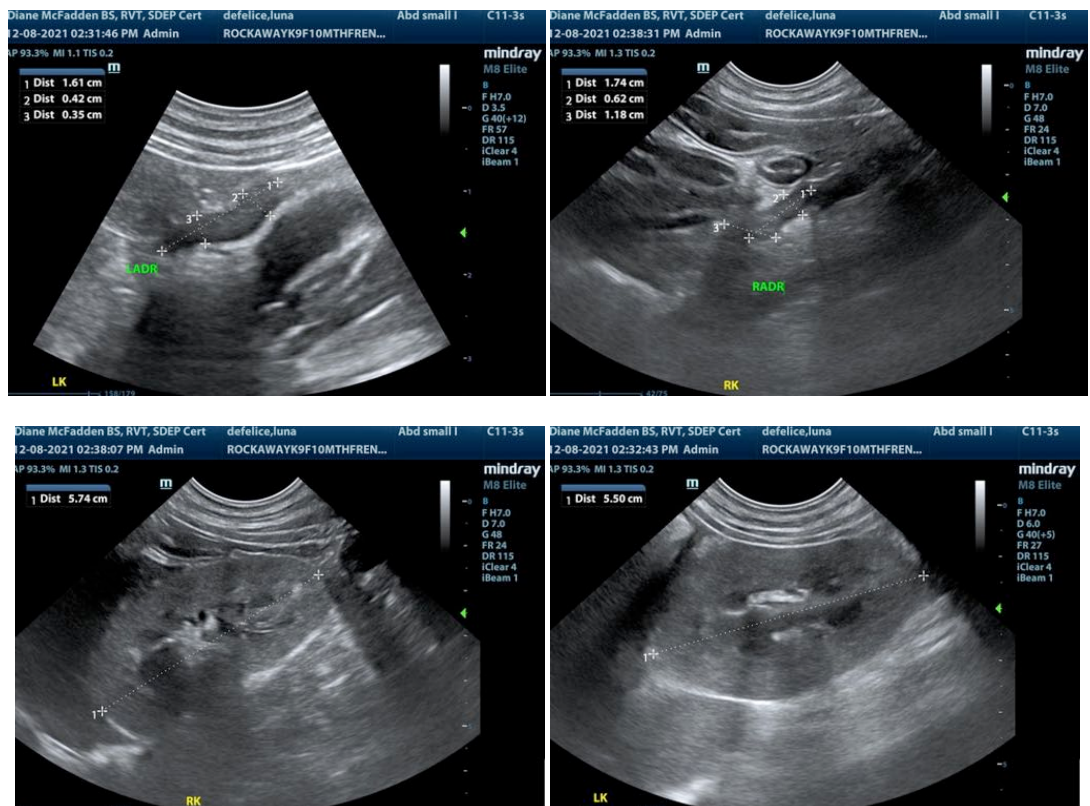
Rockaway

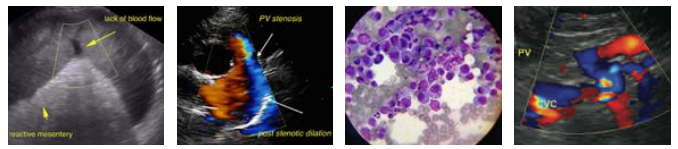
**INVOICE**

94406

**DATE**

12/8/21





**PATIENT**

Luna DeFelice

**SPECIES**

Canine

**BREED**

French Bulldog

**SEX**

Intact Female

**AGE**

10 months

**WEIGHT**

21 lbs

**INTERPRETED BY**

Eric Lindquist, DMV  
DABVP, Cert. IVUSS

**IMAGING PERFORMED BY**

Diane McFadden, RVT

**HOSPITAL NAME**

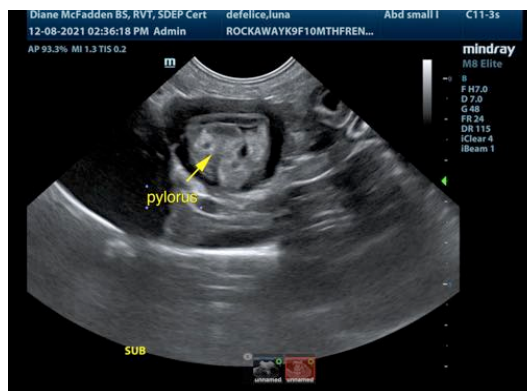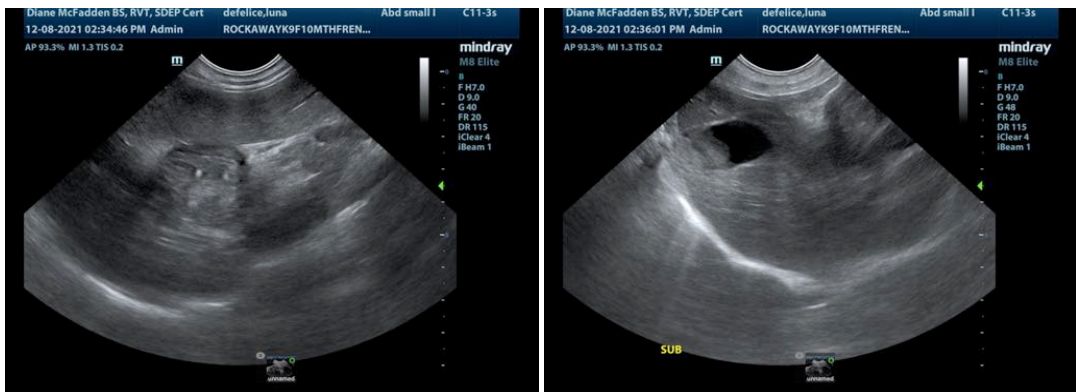
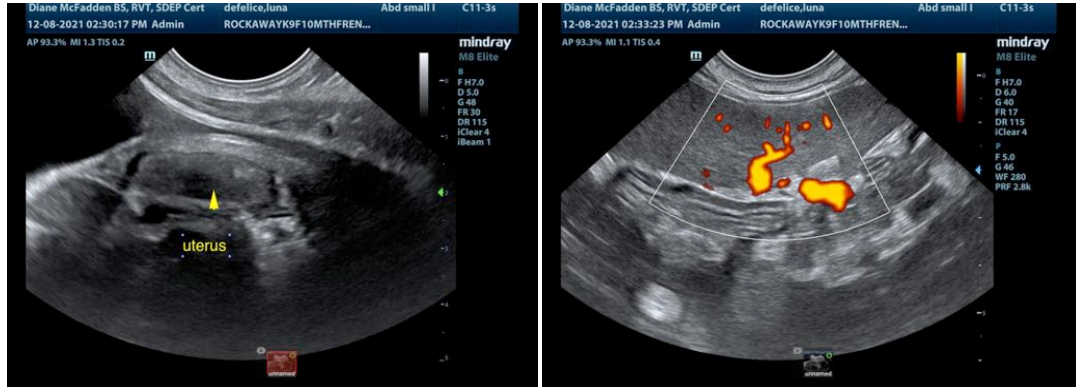
Rockaway

**INVOICE**

94406

**DATE**

12/8/21



The information and recommendations provided are based on the images presented by the referring veterinarian. No evaluation can be communicated regarding pathology that was not visible in the image/video clips provided.

Thank you for this referral. If the clinical or image interpretation does not parallel your findings or if I can be of any further assistance please contact me.

Eric Lindquist, DMV, DABVP, Cert. IVUSS, CEO of SonoPath.com  
Info@SonoPath.com