



PATIENT PRESENTING CLINICAL SIGNS

Teddy Bird History: recheck, checking to see if he still needs the scope or surgical intervention

SPECIES ULTRASONOGRAPHIC EXAMINATION

Canine

Gastrointestinal

BREED

The upper **gastrointestinal tract** revealed 3-4 cm of progressively shadowing material that is partially obstructive with chyme. The small intestine and colon were unremarkable.

Labrador

SEX

ULTRASONOGRAPHIC FINDINGS

Neutered male

Persistent gastric foreign body.

AGE

INTERPRETATION OF THE FINDINGS & FURTHER RECOMMENDATIONS

1 year

Endoscopy or gastrotomy is indicated.

WEIGHT

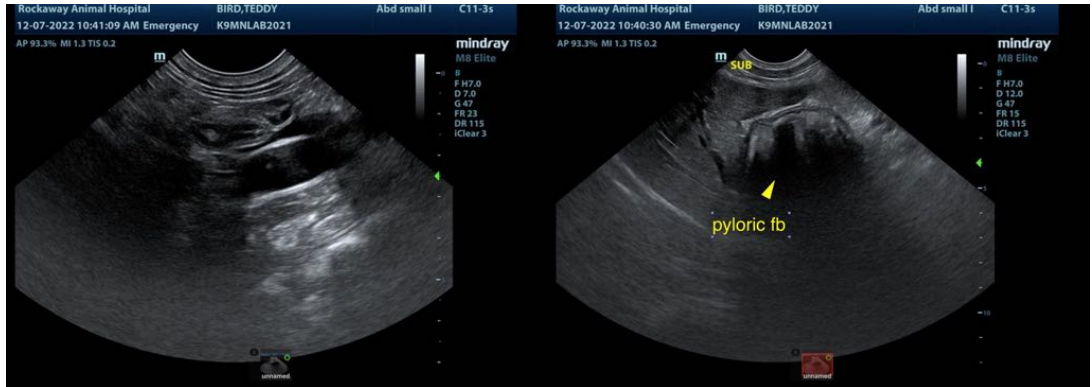
65 lbs

INTERPRETED BY

Eric Lindquist, DMV
DABVP, Cert. IVUSS

IMAGING PERFORMED BY

Jenn



HOSPITAL NAME

Rockaway AH

The information and recommendations provided are based on the images presented by the referring veterinarian/sonographer. No evaluation can be communicated regarding pathology that was not visible in the image/video clips provided.

REFERRING VET

Dr. Maniar

Thank you for this referral. If the clinical or image interpretation does not parallel your findings or if I can be of any further assistance please contact me.

Eric Lindquist, DMV, DABVP, Cert. IVUSS, CEO of SonoPath.com
info@SonoPath.com

INVOICE

42914

DATE

12/7/22