



PATIENT PRESENTING CLINICAL SIGNS

Roxie Callahan History: presented for coughing

SPECIES ULTRASONOGRAPHIC EXAMINATION OF THE HEART

Canine

BREED

Terrier Mix

SEX

Spayed female

AGE

10 years

WEIGHT

19.5 lbs

The echocardiogram in this patient demonstrated enlarged **left atrial** size based on 3 different LA measurement methods. Chamber volumes and echogenicity were normal. The cranial and caudal **mitral** valve leaflets presented vegetative thickening consistent with endocardiosis. Doppler indicated measurable insufficiency. The **left ventricle** presented normal thicknesses with linear contour and was not dilated nor restricted. The **myocardium** presented normal echogenicity without subjective evidence of significant fibrotic or ischemic disease. **Contractility** of the ventricular walls was adequate and in normal range for this patient evidenced by the fractional shortening measurement and subjective evaluation of the different regions of the myocardium. The **left ventricular outflow** tract demonstrated normal laminar flow and subjective structural integrity. The **right atrium** and auricle revealed normal size, structure and content. No evidence of masses was noted or chamber overload. **Tricuspid** valvular assessment demonstrated adequate linear morphology. The **right ventricle** was of normal size (1/3 diameter of LV), chordae structure, myocardial echogenicity and thickness. **Pulmonic** tract assessment revealed normal valve structure, laminar flow, and diameter (approx. 1:1 pa/ao ratio). No visible **pericardial** or free pleura fluid was noted. No echographically detectable evidence of infiltrative disease was visible. The cranial **mediastinum and pericardial regions** were free of masses in the visible window.

INTERPRETED BY

Eric Lindquist, DMV
DABVP, Cert. IVUSS

IMAGING PERFORMED BY

Jenn

HOSPITAL NAME

Rockaway AH

REFERRING VET

Dr. Maniar

CANINE	MR	TR	LA/AO	LA/AO	FS	EF	EPSS
CARDIAC PARAMETERS	VMAX (m/s)	VMAX (m/s)	(Boon method)	(Heart Base; Swe)	(%)	(%)	(cm)
NORMAL PARAMETER	4.5-5.5	<2.7	1.3	<1.6	28-40	40-100	<0.6
PATIENT	NM	NM	1.6	1.7	32	62	NM
CANINE	HR	AV	PV	BODY WEIGHT	LA	LVIDd	LVIDs
CARDIAC PARAMETERS	(BPM)	VMAX (m/s)	MAX (m/s)		2D short axis Base view (cm)	Avg; 2D and m-mode short axis (cm)	Avg; 2D and m-mode short axis (cm)
NORMAL PARAMETER	50-100	0.7-1.7	0.7-1.6	BELOW	BELOW	BELOW	BELOW
PATIENT	123	1.3	0.9	19.5 lbs	3.5 max	3.21	

INVOICE ULTRASONOGRAPHIC FINDINGS

42915 Advanced stage B2 to early C1 valvular disease.

DATE

12/7/22



PATIENT

Roxie Callahan

SPECIES

Canine

BREED

Terrier Mix

SEX

Spayed female

AGE

10 years

WEIGHT

19.5 lbs

INTERPRETED BY

Eric Lindquist, DMV
DABVP, Cert. IVUSS

IMAGING PERFORMED BY

Jenn

HOSPITAL NAME

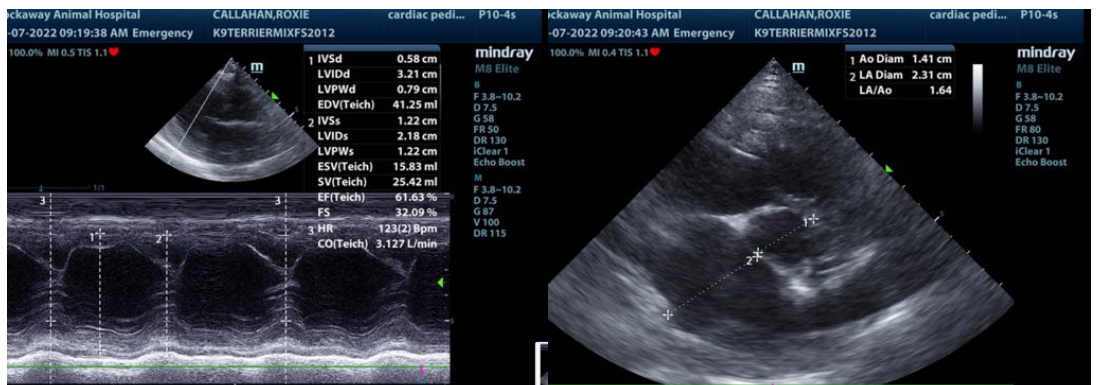
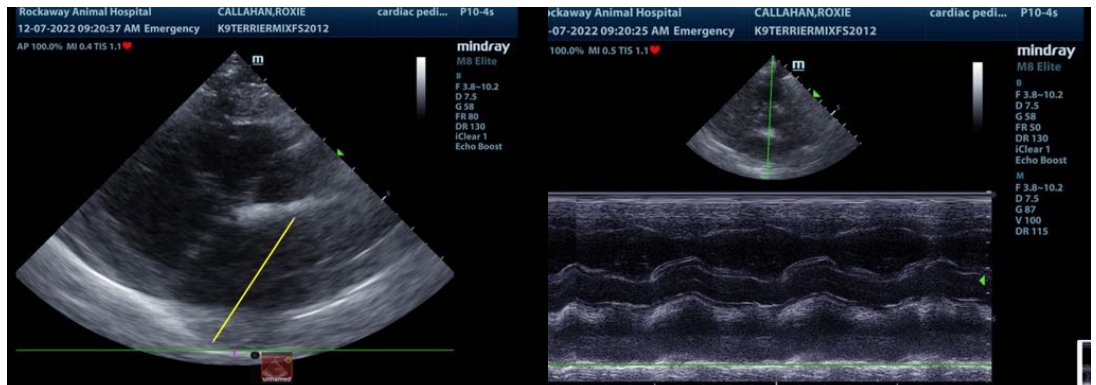
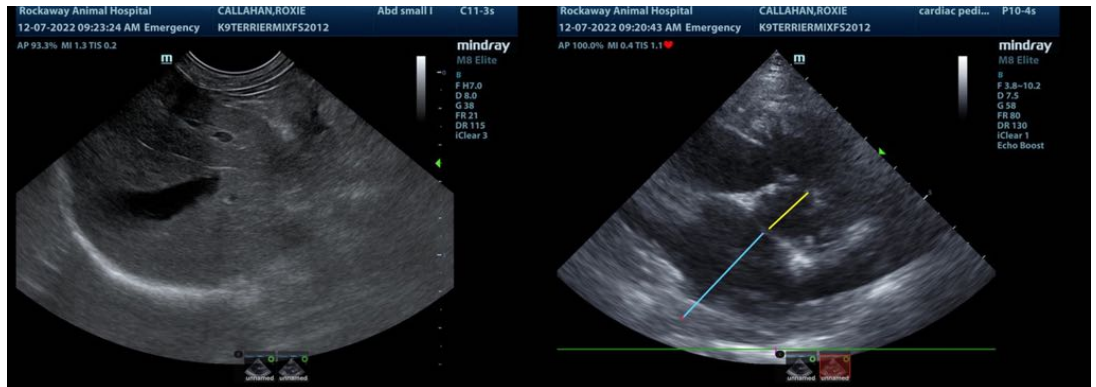
Rockaway AH

REFERRING VET

Dr. Maniar

INTERPRETATION OF THE FINDINGS & FURTHER RECOMMENDATIONS

I recommend triple therapy in this patient with Pimobendan at 0.3 mg/kg b.i.d., ace inhibitor at 0.5 mg/kg s.i.d. progressing to b.i.d. and Spironolactone at 1-2 mg/kg b.i.d. If coughing is still an issue then low-dose Lasix can be considered. Recheck echocardiogram is recommended in 1-3 months.



INVOICE

42915

DATE

12/7/22

The information and recommendations provided are based on the images presented by the referring veterinarian/sonographer. No evaluation can be communicated regarding pathology that was not visible in the image/video clips provided.

Thank you for this referral. If the clinical or image interpretation does not parallel your findings or if I can be of any further assistance please contact me.

Eric Lindquist, DMV, DABVP, Cert. IVUSS, CEO of SonoPath.com
info@SonoPath.com