



PATIENT

Raji Linzenberg

PRESENTING CLINICAL SIGNS

Weight loss, vomiting/diarrhea, ascites, murmur.

SPECIES

Feline

ULTRASONOGRAPHIC EXAMINATION OF THE ABDOMEN

Urinary System

BREED

Domestic Longhair

The **urinary bladder**, trigone, and pelvic urethra presented normal thicknesses and normal tone. The ureters were not visible which is normal. No uroliths or sediment were visualized and anechoic urine was present. No evidence of inflammatory or neoplastic changes was noted. Ureteral papillae were normal.

SEX

Neutered male

The **kidneys** presented bilateral interstitial nephrosis pattern with mild renomegaly. The right kidney measured 5.26 cm. The left kidney measured 5.0 cm. Blood flow to the kidneys was mildly subnormal.

AGE

8 years

Adrenal Glands

INTERPRETED BY

Eric Lindquist, DMV
DABVP, Cert. IVUSS

Both **adrenal glands** were visualized and recognized as having normal shape, size, position and echogenicity for this breed. The phrenic vasculature, glandular echogenicity and detail were unremarkable. Capsule, cortex, and medullary definition were normal for this age patient. Both adrenal glands measured 0.5 cm.

IMAGING PERFORMED BY

Eric Lindquist, DMV
DABVP, Cert. IVUSS

Spleen

The **spleen** in this patient was uniform, yet volume contracted. Hydration status should be assessed.

HOSPITAL NAME

Ramapo Valley AH

Liver

The **liver** was uniform with mild tortuous cystic duct and uniform enlargement. The parenchyma was uniform. The gallbladder and common and common bile duct were unremarkable.

REFERRING VET

Dr. Walker

Gastrointestinal

Examination of the **gastrointestinal tract** revealed a stomach and intestine free of stasis, of normal wall thickness, acceptable curvilinear mural detail, and peristaltic activity. Small and large intestine demonstrated normal luminal chyme and stool consistency respectively. No obstructive or overt infiltrative disease was noted. No associated abnormal lymphatic activity was noted.

INVOICE

94335

DATE

12/7/21

Pancreas

The base and limbs of the **pancreas** were observed to be largely isoechoic to surrounding omental fat. Some parenchymal remodeling, however, with mild deviation from curvilinear normalcy was observed. Pancreatic duct and capsular irregularities were present consistent with age related changes. If pain upon imaging (+ Murphy sign) was present or if the patient is focally painful in subxiphoid palpation then low-grade smoldering chronic pancreatitis should be suspected.



PATIENT

Raji Linzenberg

SPECIES

Feline

BREED

Domestic Longhair

SEX

Neutered male

AGE

8 years

INTERPRETED BY

Eric Lindquist, DMV
DABVP, Cert. IVUSS

IMAGING PERFORMED BY

Eric Lindquist, DMV
DABVP, Cert. IVUSS

HOSPITAL NAME

Ramapo Valley AH

REFERRING VET

Dr. Walker

INVOICE

94335

DATE

12/7/21

ULTRASONOGRAPHIC EXAMINATION OF THE HEART

Minimal echocardiogram was performed owing to poor acoustic window and patient demeanor. This patient demonstrated normal **left atrial** size based on 3 separate LA measurements. The cranial and caudal **mitral valve** leaflets presented normal linear structure and kinetics. The **left ventricle** presented normal thicknesses with linear contour and was not dilated nor restricted. The **myocardium** presented normal echogenicity without subjective evidence of significant fibrotic or ischemic disease. **Contractility** was normal, internal volumes were subnormal likely owing to systemic disease and volume contraction. The **left ventricular outflow** tract demonstrated subjective structural integrity. The **right atrium** and auricle revealed normal size, structure and content. No evidence of masses was noted or chamber overload. **Tricuspid** valvular assessment demonstrated adequate linear morphology and kinetics. The **right ventricle** was of normal size (1/3 diameter of LV), chordae structure, myocardial echogenicity and thickness. **Pulmonic** tract assessment revealed normal valve structure, and diameter (approx. 1:1 pa/ao ratio). No visible **pericardial** or free pleura fluid was noted or extra cardiac pathology in the visible planes. The cranial **mediastinum** and **pericardial regions** were free of masses in the visible window.

FELINE CARDIAC PARAMETERS	BODY WEIGHT (kg)	HR (BPM)	IVSd (cm)	LVIDd (cm)	LVWd (cm)	FS (%)	EF (%)
NORMAL PARAMETER	-----	150-240	0.3-0.6	1.0-2.1	0.25-0.6	35-67	80-100
PATIENT		NM	0.5	0.8	0.5	45	
FELINE CARDIAC PARAMETERS	LA/AO (Boon)	LA/AO HEART BASE (Sisson)	LA 2D 4-chamber long axis AS to FW (Sisson) (cm)	LVOT VEL. (m/s)	RVOT VEL. (m/s)	IVRT (m/)	
NORMAL PARAMETER	<1.5	0.88-1.79	0.7-1.7	<1.6	<1.3	40-60	
PATIENT	1.1		1.1				NM
Adapted from June Boon, Veterinary Echocardiography, 1998 Sisson D et al. JVIM 1991; 5: 232, Jacobs et al. Am J Vet Res 1985; 46:1705							

ULTRASONOGRAPHIC FINDINGS

Interstitial nephrosis renal pattern with mild uniform hepatomegaly.

Minimal echocardiogram owing to poor acoustic window and patient demeanor. However, there was no evidence of cardiac pathology present other than minor pseudo hypertrophy of the left ventricle.

INTERPRETATION OF THE FINDINGS & FURTHER RECOMMENDATIONS

There was no evidence of neoplasia. Emerging renal lymphoma cannot be completely ruled out. However, the architecture is well conserved. There is a mild potential for dry form FIP.

Maldigestion panel, three view chest radiographs and full CNS examination is recommended to examine for occult disease that could be responsible for the weight loss. Evaluation for competitive eating environments should also be considered.



PATIENT

Raji Linzenberg

SPECIES

Feline

BREED

Domestic Longhair

SEX

Neutered male

AGE

8 years

INTERPRETED BY

Eric Lindquist, DMV
DABVP, Cert. IVUSS

IMAGING PERFORMED BY

Eric Lindquist, DMV
DABVP, Cert. IVUSS

HOSPITAL NAME

Ramapo Valley AH

REFERRING VET

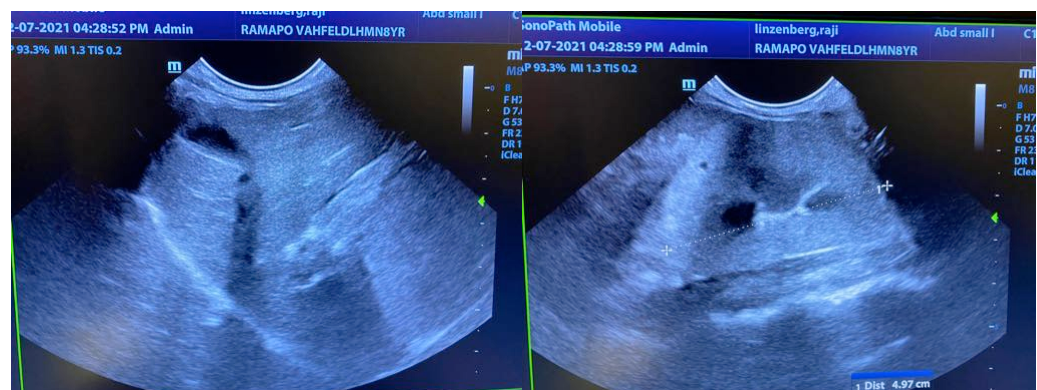
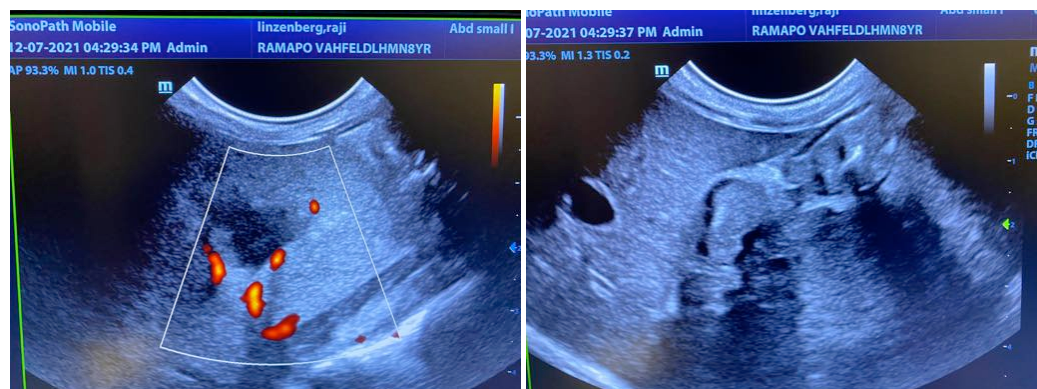
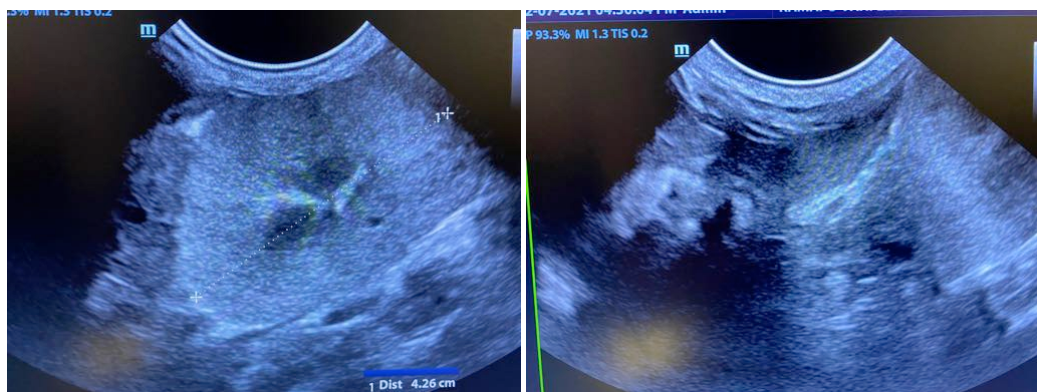
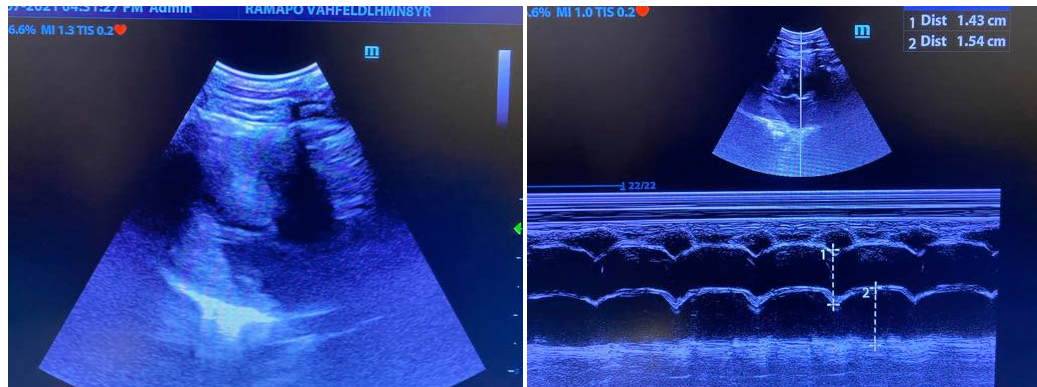
Dr. Walker

INVOICE

94335

DATE

12/7/21





PATIENT

Raji Linzenberg

veterinarian. No evaluation can be communicated regarding pathology that was not visible in the image/video clips provided.

Thank you for this referral. If the clinical or image interpretation does not parallel your findings or if I can be of any further assistance please contact me.

SPECIES

Feline

Eric Lindquist, DMV, DABVP, Cert. IVUSS, CEO of SonoPath.com
Info@SonoPath.com

BREED

Domestic Longhair

SEX

Neutered male

AGE

8 years

INTERPRETED BY

Eric Lindquist, DMV
DABVP, Cert. IVUSS

**IMAGING
PERFORMED BY**

Eric Lindquist, DMV
DABVP, Cert. IVUSS

HOSPITAL NAME

Ramapo Valley AH

REFERRING VET

Dr. Walker

INVOICE

94335

DATE

12/7/21