



**PATIENT**

**PRESENTING CLINICAL SIGNS**

Lyra Demarest

Recheck gastric foreign body.

**SPECIES**

**ULTRASONOGRAPHIC EXAMINATION OF THE ABDOMEN**

Canine

**Urinary System**

**BREED**

The **urinary bladder**, trigone, and pelvic urethra presented normal thicknesses and normal tone. The pelvic urethra was imaged 2.0 cm beyond the cystourethral junction. The ureters were not visible which is normal. No uroliths or sediment were visualized and anechoic urine was present. No evidence of inflammatory or neoplastic changes was noted. Ureteral papillae were normal.

Poodle

**SEX**

The **kidneys** revealed normal size and structure, corticomedullary definition and ratio for this age. The cortices presented largely uniform texture with normal echogenic relationship to liver and spleen. Medullary structure differed distinctly from the cortex and no evidence of pelvic dilation was present. The capsules were acceptably uniform without significant irregularities. The left kidney measured 5.66 cm.

Spayed Female

**AGE**

7 months

**INTERPRETED BY**

**Adrenal Glands**

Eric Lindquist, DMV  
DABVP, Cert. IVUSS

Both **adrenal glands** were visualized and recognized as having normal shape, size, position and echogenicity for this breed. The phrenic vasculature, glandular echogenicity and detail were unremarkable. Capsule, cortex, and medullary definition were normal for this age patient. The right adrenal gland measured 1.68 x 0.82 cm. The left adrenal gland measured 2.0 x 0.5 cm.

**IMAGING PERFORMED BY**

Eric Lindquist, DMV  
DABVP, Cert. IVUSS

**Spleen**

**HOSPITAL NAME**

The **spleen** presented a smooth homogeneous parenchyma hyperechoic to liver and renal cortical parenchyma. The capsule was smooth without noticeable expansion or deviation from within the spleen or adjacent pathology. The splenic vasculature demonstrated normal volume without signs of congestion or thrombosis. No sonographic evidence of acute or chronic inflammatory, neoplastic, or infarctual changes was noted.

Rockaway AH

**REFERRING VET**

Dr. Maniar

**Liver**

**INVOICE**

The **liver** images submitted revealed subjectively normal liver size, contour, and structure. Parenchymal echogenicity was naturally coarse and hypoechoic to the spleen. Vascular and biliary tracts were of normal volume with no evidence of congestion. The gallbladder presented acceptably thin walls with primarily anechoic content. The cystic and common bile ducts were normal. No pathological hepatic lymphadenopathy was evident. No overt structural evidence of inflammatory, infiltrative or regenerative pathology was evident.

94343

**DATE**

12/7/21



**PATIENT**

**Gastrointestinal**

Lyra Demarest

The **gastric** foreign body was persistently present and measured 5.3 cm. This is consistent with fabric accumulation. The small intestine and colon was unremarkable.

**SPECIES**

Canine

**Pancreas**

The base and limbs of the **pancreas** were observed to be largely isoechoic to surrounding omental fat. Pancreatic duct and capsular contour were acceptably normal and parenchyma respected normal curvilinear patterns. No overt evidence of active inflammatory or neoplastic disease was noted.

**BREED**

Poodle

**SEX**

**ULTRASONOGRAPHIC FINDINGS**

Spayed Female

Persistent gastric foreign body.

**AGE**

**INTERPRETATION OF THE FINDINGS & FURTHER RECOMMENDATIONS**

7 months

Gastrotomy is indicated. GI biopsies are warranted. According to Sonopath research presented at ECVIM 2016 (Stockholm, Sweden), Advances in Small Animal Medicine and Surgery (May 2017), and EVDI 2017 (Verona, Italy), concurrent underlying chronic inflammatory neoplastic intestinal disease can often reside in PICA patients. Therefore, surgical biopsies are essential in this case regardless of the exploratory findings.

**INTERPRETED BY**

Eric Lindquist, DMV  
DABVP, Cert. IVUS

**IMAGING PERFORMED BY**

Eric Lindquist, DMV  
DABVP, Cert. IVUS

**HOSPITAL NAME**

Rockaway AH

**REFERRING VET**

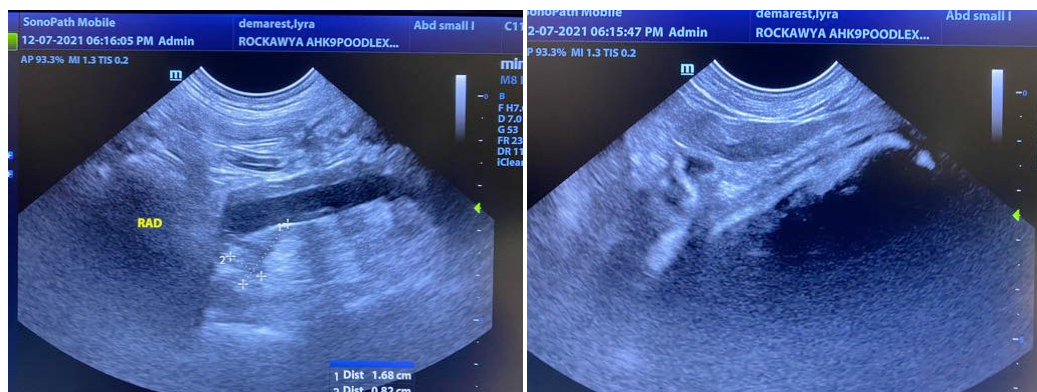Dr. Maniar

**INVOICE**

94343

**DATE**

12/7/21





**PATIENT**

Lyra Demarest

**SPECIES**

Canine

**BREED**

Poodle

**SEX**

Spayed Female

**AGE**

7 months

**INTERPRETED BY**

Eric Lindquist, DMV  
DABVP, Cert. IVUSS

**IMAGING PERFORMED BY**

Eric Lindquist, DMV  
DABVP, Cert. IVUSS

**HOSPITAL NAME**

Rockaway AH

**REFERRING VET**

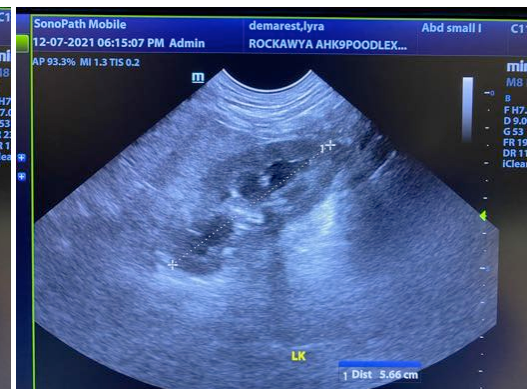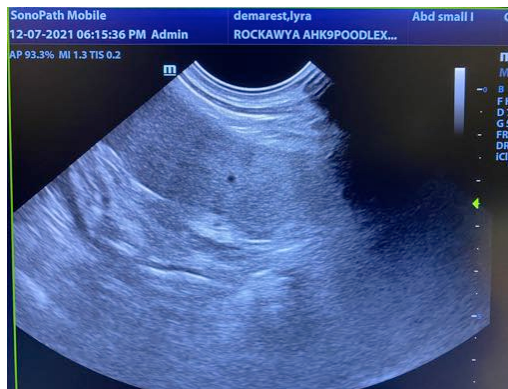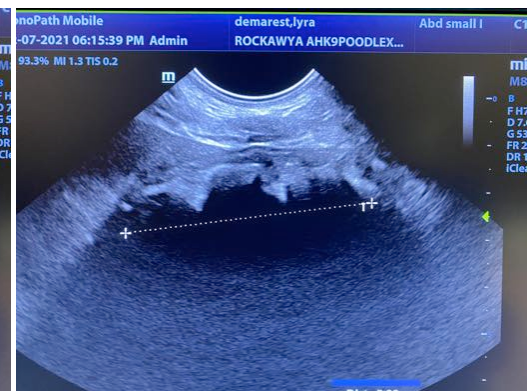
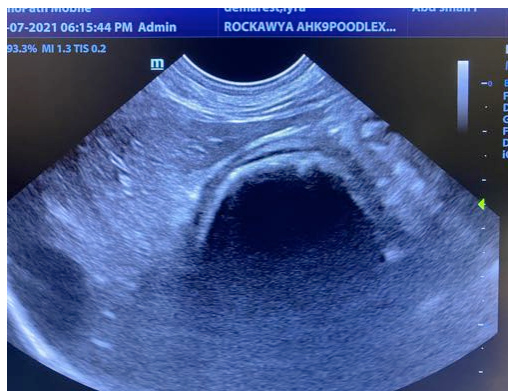Dr. Maniar

**INVOICE**

94343

**DATE**

12/7/21



The information and recommendations provided are based on the images presented by the referring veterinarian. No evaluation can be communicated regarding pathology that was not visible in the image/video clips provided.

Thank you for this referral. If the clinical or image interpretation does not parallel your findings or if I can be of any further assistance please contact me.

**Eric Lindquist**, DMV, DABVP, Cert. IVUSS, CEO of SonoPath.com  
Info@SonoPath.com