



PATIENT

Lulu Xiong

SPECIES

Canine

BREED

Dachshund Mix

SEX

Female

AGE

2 years

WEIGHT

18 lbs

INTERPRETED BY

Eric Lindquist, DMV
DABVP, Cert. IVUSS

IMAGING PERFORMED BY

M Kermendy CVT

HOSPITAL NAME

Wauwatusoa

REFERRING VET

Dr. Binor

INVOICE

94375

DATE

12/7/21

PRESENTING CLINICAL SIGNS

History: History of drooling, nausea, and vomiting for approximately 2 weeks. Seems ok, then vomits in the morning. On a bland diet of chicken and rice. Appetite normal. Stool is green and soft. Acting normal last 48 hours, owner is now reporting that she is acting unstable/not herself. Concern for structural GI disease. Check status of GI tract/stomach.

ULTRASONOGRAPHIC EXAMINATION OF THE ABDOMEN

Urinary System

The **urinary bladder**, trigone, and pelvic urethra presented normal thicknesses and normal tone. The ureters were not visible which is normal. No uroliths or sediment were visualized and anechoic urine was present. No evidence of inflammatory or neoplastic changes was noted. Ureteral papillae were normal.

The **left kidney** was normal in size and contour. The left kidney measured 4.41 cm. The right kidney measured 3.76 cm with increased cortical echogenicity with irregular contour.

Adrenal Glands

Both **adrenal glands** were visualized and recognized as having normal shape, size, position and echogenicity for this breed. The phrenic vasculature, glandular echogenicity and detail were unremarkable. Capsule, cortex, and medullary definition were normal for this age patient. The left adrenal gland measured 0.4 cm.

Spleen

The **spleen** in this patient was mildly enlarged with uniform parenchyma and was folded upon itself cranially. This is a positional variant and is not pathological. There was no evidence of significant disease.

Liver

The **liver** revealed increased portal markings with coarse architecture. The gallbladder presented acceptably thin walls with primarily anechoic content. The cystic and common bile ducts were normal. No pathological hepatic lymphadenopathy was evident. No overt structural evidence of inflammatory, infiltrative or regenerative pathology was evident.

Gastrointestinal

Excessive GI gas was noted in the **stomach**. This is a non-obstructive pattern. The lumen was empty and the curvilinear patterns were maintained. The small intestine and colon were unremarkable.



PATIENT

Pancreas

Lulu Xiong

The base and limbs of the **pancreas** were observed to be largely isoechoic to surrounding omental fat. Pancreatic duct and capsular contour were acceptably normal and parenchyma respected normal curvilinear patterns. No overt evidence of active inflammatory or neoplastic disease was noted.

SPECIES

Canine

ULTRASONOGRAPHIC FINDINGS

BREED

Mild hepatic remodeling.

Dachshund Mix

Degenerative cortical changes in the right kidney.

Otherwise, unremarkable abdomen.

SEX

Female

INTERPRETATION OF THE FINDINGS & FURTHER RECOMMENDATIONS

AGE

Dietary indiscretion, food intolerance/indiscretion, structurally insignificant inflammatory bowel or occult parasitism and occult Addison's are all potentials.

2 years

WEIGHT

18 lbs

INTERPRETED BY

Eric Lindquist, DMV
DABVP, Cert. IVUSS

IMAGING PERFORMED BY

M Kermendy CVT

HOSPITAL NAME

Wauwatusoa

REFERRING VET

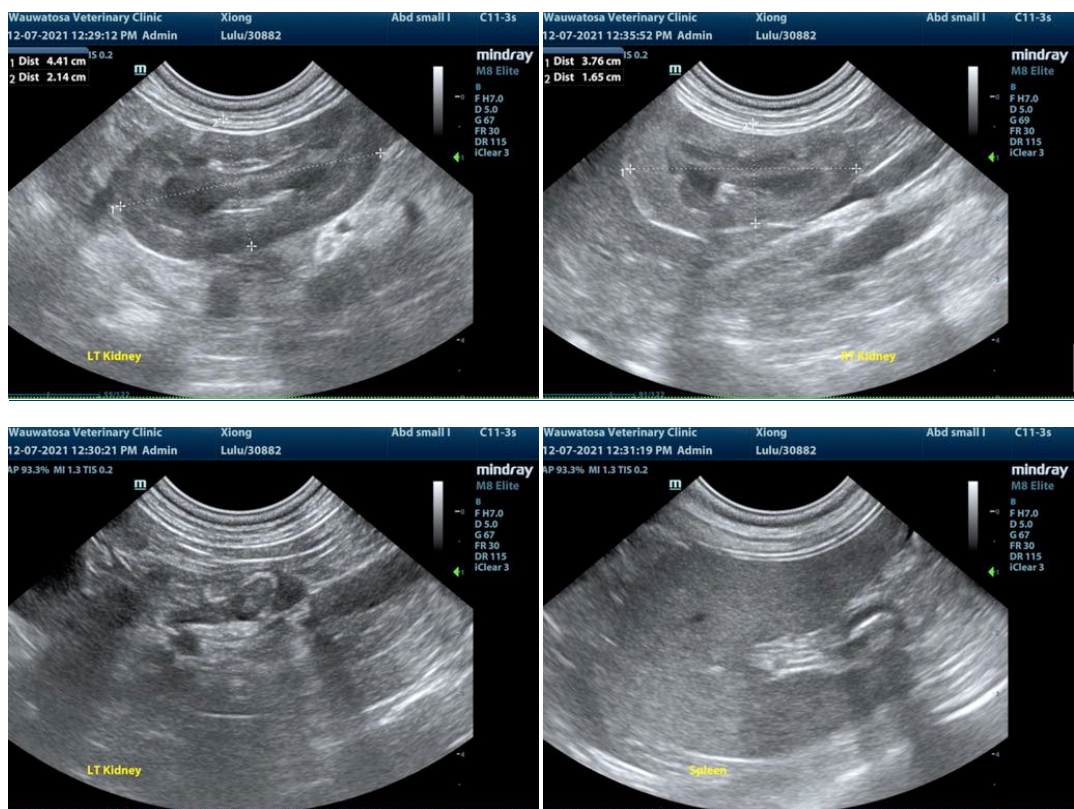
Dr. Binor

INVOICE

94375

DATE

12/7/21





PATIENT

Lulu Xiong

SPECIES

Canine

BREED

Dachshund Mix

SEX

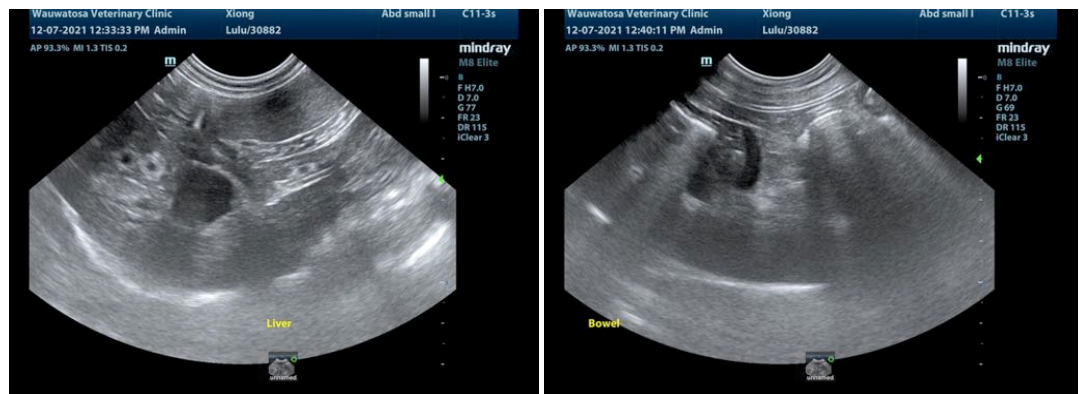
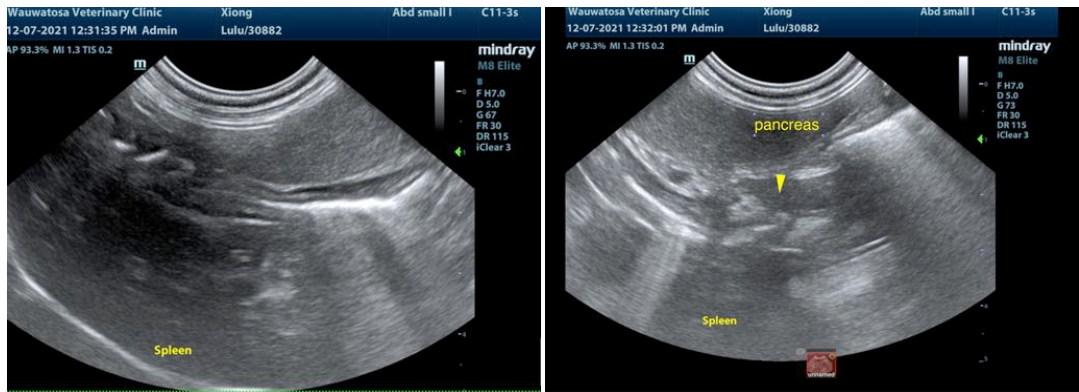
Female

AGE

2 years

WEIGHT

18 lbs



INTERPRETED BY

Eric Lindquist, DMV
DABVP, Cert. IVUSS

IMAGING PERFORMED BY

M Kermendy CVT

HOSPITAL NAME

Wauwatosa

REFERRING VET

Dr. Binor

INVOICE

94375

DATE

12/7/21

The information and recommendations provided are based on the images presented by the referring veterinarian. No evaluation can be communicated regarding pathology that was not visible in the image/video clips provided.

Thank you for this referral. If the clinical or image interpretation does not parallel your findings or if I can be of any further assistance please contact me.

Eric Lindquist, DMV, DABVP, Cert. IVUSS, CEO of SonoPath.com
info@SonoPath.com