



PATIENT

Jack Yeager

PRESENTING CLINICAL SIGNS

History: Prior splenic nodule (3.7 mm) seen at ventral aspect of splenic tail. Reassess today for change. Prior scan 6 mo. ago.

SPECIES

Feline

ULTRASONOGRAPHIC EXAMINATION OF THE ABDOMEN

Urinary System

BREED

Domestic Longhair

The **urinary bladder**, trigone, and pelvic urethra presented normal thicknesses and normal tone. The ureters were not visible which is normal. A minor amount of suspended debris was noted. No evidence of inflammatory or neoplastic changes was noted. Ureteral papillae were normal.

SEX

Neutered male

The **kidneys** revealed largely normal size and structure, corticomedullary definition and ratio (cortex 1/3 of medulla) were essentially maintained with some age-related loss of curvilinear patterns regarding the capsule and C/M junction. The cortices presented largely uniform texture with some increased echogenicity expected for this age patient. Medullary structure differed distinctly from that of the cortex and no evidence of pelvic dilation was present. The left kidney measured 4.44 cm.

AGE

9 years

WEIGHT

5.2 kg

Adrenal Glands

Both **adrenal glands** were visualized and recognized as having normal shape, size, position and echogenicity for this breed. The phrenic vasculature, glandular echogenicity and detail were unremarkable. Capsule, cortex, and medullary definition were normal for this age patient. The left adrenal gland measured 0.4 cm.

INTERPRETED BY

Eric Lindquist, DMV
DABVP, Cert. IVUSS

Spleen

IMAGING PERFORMED BY

Dave Stasiuk Rdms,
RDCS

The **spleen** was mildly enlarged with scalloping contour. The spleen was folded upon itself caudally. Focal, hypoechoic nodule was persistently present and measured 0.68 cm. It appears to have doubled in size compared to the prior sonogram.

HOSPITAL NAME

Resolution Veterinary
Ultrasound

Liver

REFERRING VET

Signal Hill AC

The **liver** images submitted revealed subjectively normal liver size, contour, and structure. Parenchymal echogenicity was naturally coarse and hypoechoic to the spleen. Vascular and biliary tracts were of normal volume with no evidence of congestion. The gallbladder presented acceptably thin walls with primarily anechoic content. The cystic and common bile ducts were normal. No pathological hepatic lymphadenopathy was evident. No overt structural evidence of inflammatory, infiltrative or regenerative pathology was evident.

INVOICE

94379

Gastrointestinal

DATE

12/7/21

Examination of the **gastrointestinal tract** revealed a stomach and intestine free of stasis, of normal wall thickness, acceptable curvilinear mural detail, and peristaltic activity. Small and large intestine



PATIENT

demonstrated normal luminal chyme and stool consistency respectively. No obstructive or overt infiltrative disease was noted. No associated abnormal lymphatic activity was noted.

Jack Yeager

SPECIES

Pancreas

Feline

The base and limbs of the **pancreas** were observed to be largely isoechoic to surrounding omental fat. Pancreatic duct and capsular contour were acceptably normal and parenchyma respected normal curvilinear patterns. No overt evidence of active inflammatory or neoplastic disease was noted.

BREED

Domestic Longhair

ULTRASONOGRAPHIC FINDINGS

SEX

Mild splenic enlargement with focal, nodule, progressing in size.

Neutered male

INTERPRETATION OF THE FINDINGS & FURTHER RECOMMENDATIONS

AGE

General FNA of the spleen is warranted as well as FNA of the nodule for further definition and would be strongly recommended if any weight loss is present. Nodular hyperplasia versus emerging round cell neoplasia with a minor potential for hemangiosarcoma.

9 years

WEIGHT

5.2 kg

INTERPRETED BY

Eric Lindquist, DMV
DABVP, Cert. IVUSS

IMAGING PERFORMED BY

Dave Stasiuk Rdms,
RDCS

HOSPITAL NAME

Resolution Veterinary
Ultrasound

REFERRING VET

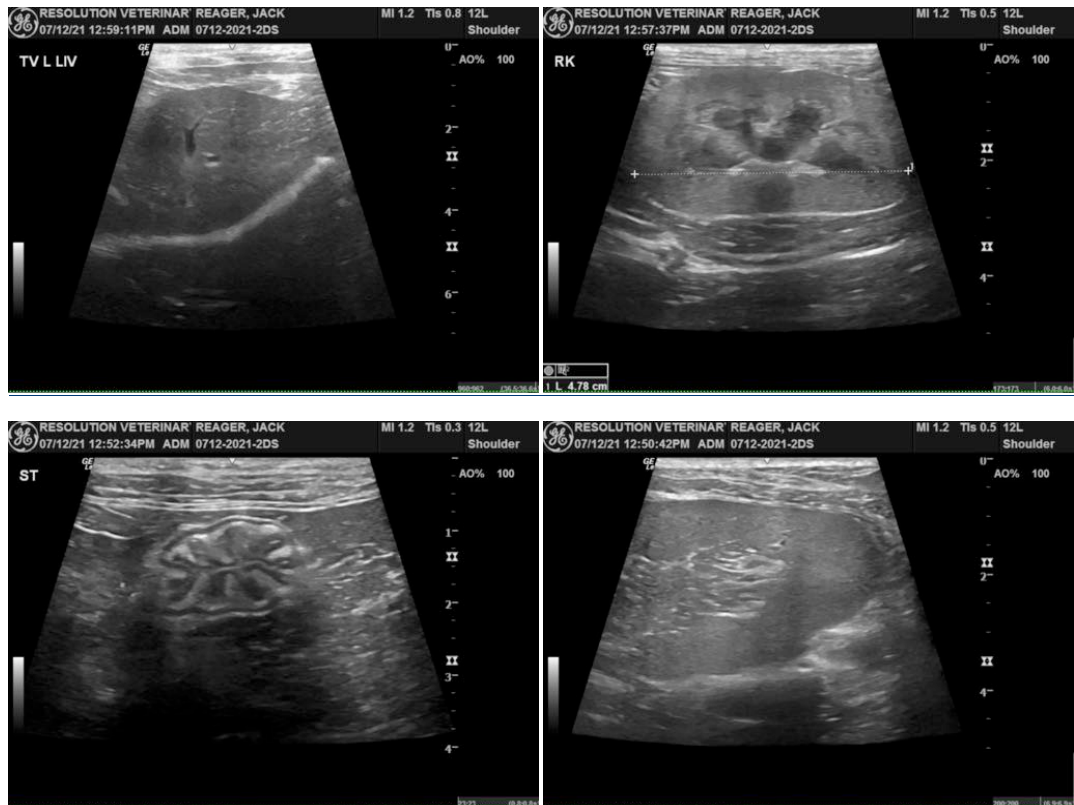
Signal Hill AC

INVOICE

94379

DATE

12/7/21





PATIENT

Jack Yeager

SPECIES

Feline

BREED

Domestic Longhair

SEX

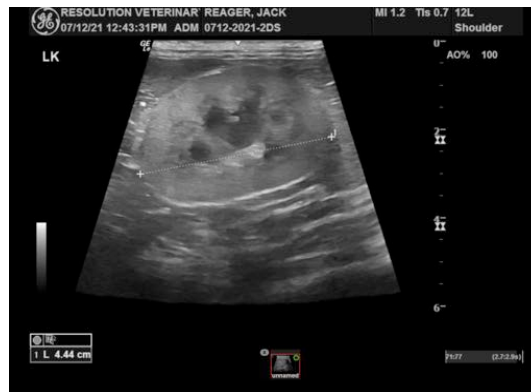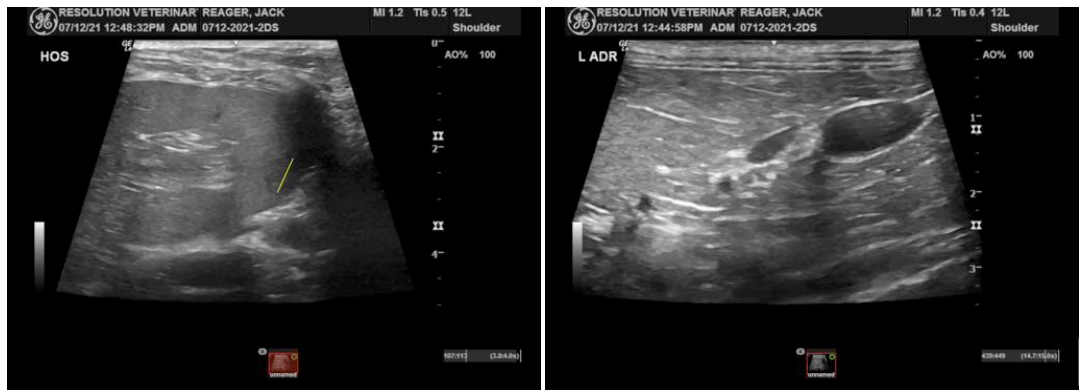
Neutered male

AGE

9 years

WEIGHT

5.2 kg



INTERPRETED BY

Eric Lindquist, DMV
DABVP, Cert. IVUSS

IMAGING PERFORMED BY

Dave Stasiuk Rdms,
RDCS

HOSPITAL NAME

Resolution Veterinary
Ultrasound

REFERRING VET

Signal Hill AC

INVOICE

94379

DATE

12/7/21

The information and recommendations provided are based on the images presented by the referring veterinarian. No evaluation can be communicated regarding pathology that was not visible in the image/video clips provided.

Thank you for this referral. If the clinical or image interpretation does not parallel your findings or if I can be of any further assistance please contact me.

Eric Lindquist, DMV, DABVP, Cert. IVUSS, CEO of SonoPath.com
info@SonoPath.com