



**PATIENT PRESENTING CLINICAL SIGNS**

Fenway Dodyk Elevated T4 and free T4.

**SPECIES ULTRASONOGRAPHIC EXAMINATION OF THE THYROID**

Canine **Thyroid**

**BREED** The thyroid region was imaged in this patient. Both thyroid lobes measured 0.45 cm in width. The salivary glands, regional tissue and trachea were unremarkable. The parathyroids were also imaged. The largest of which measured 0.28 cm. Both thyroid lobes were uniform with no evidence of masses.

Poodle Mix

**SEX ULTRASONOGRAPHIC FINDINGS**

Neutered male Normal thyroid and parathyroids and regional tissues.

**AGE INTERPRETATION OF THE FINDINGS & FURTHER RECOMMENDATIONS**

3 years There was no evidence of pathology. Given the elevated thyroid levels, assessment of dietary ingestion of neck meat or ectopic thyroid production should be considered. However, the thyroid itself was unremarkable.

**INTERPRETED BY**

Eric Lindquist, DMV  
DABVP, Cert. IVUSS

**IMAGING PERFORMED BY**

Eric Lindquist, DMV  
DABVP, Cert. IVUSS

**HOSPITAL NAME**

Rockaway AH

**REFERRING VET**

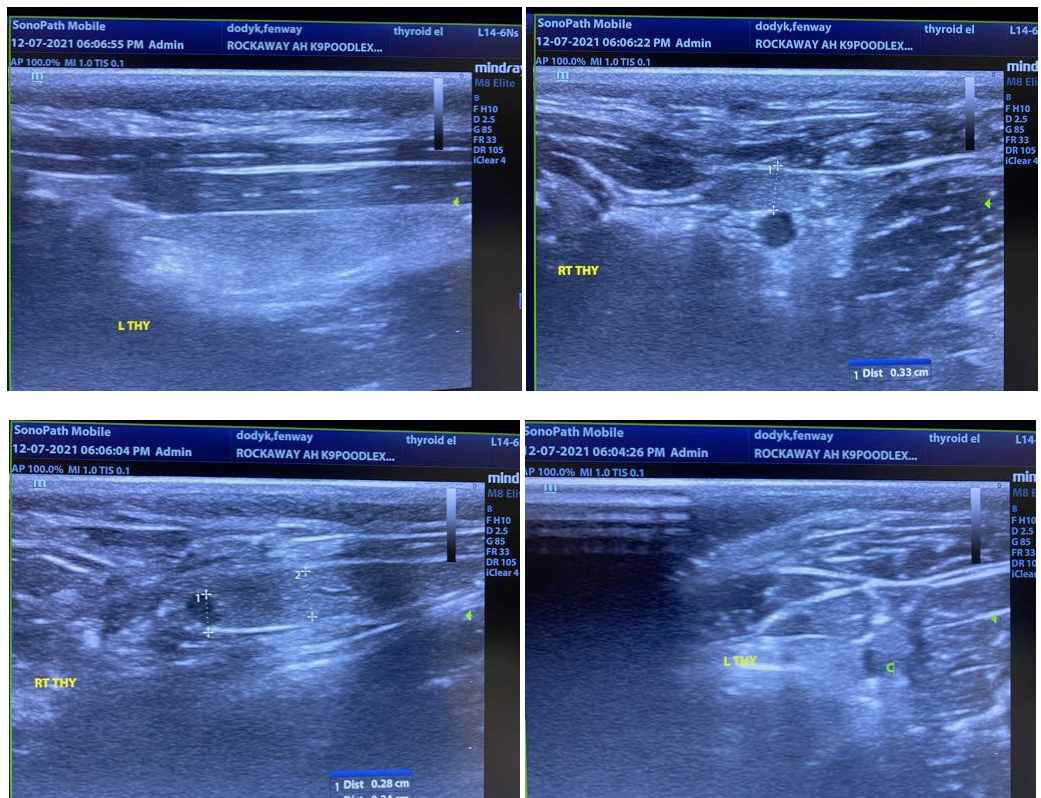
Dr. Maniar

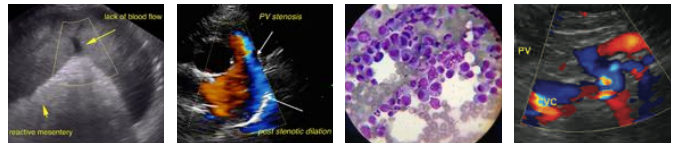
**INVOICE**

94341

**DATE**

12/7/21





**PATIENT**

Fenway Dodyk

**SPECIES**

Canine

**BREED**

Poodle Mix

**SEX**

Neutered male

**AGE**

3 years

**INTERPRETED BY**

Eric Lindquist, DMV  
DABVP, Cert. IVUSS

**IMAGING  
PERFORMED BY**

Eric Lindquist, DMV  
DABVP, Cert. IVUSS

**HOSPITAL NAME**

Rockaway AH

**REFERRING VET**

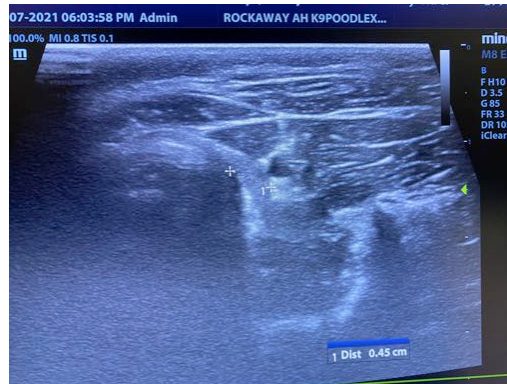Dr. Maniar

**INVOICE**

94341

**DATE**

12/7/21



The information and recommendations provided are based on the images presented by the referring veterinarian. No evaluation can be communicated regarding pathology that was not visible in the image/video clips provided.

Thank you for this referral. If the clinical or image interpretation does not parallel your findings or if I can be of any further assistance please contact me.

Eric Lindquist, DMV, DABVP, Cert. IVUSS, CEO of SonoPath.com  
Info@SonoPath.com