

PATIENT

Rory Deruiter

PRESENTING CLINICAL SIGNS

History: HEMATURIA OVER 1 MONTH NO SYMPTOMS CAT ON PROZAC FOR INTERCAT AGGRESSION URINE CULTURE PENDING R/O FIC VS OTHER

SPECIES

Feline

ULTRASONOGRAPHIC EXAMINATION OF THE ABDOMEN
Urinary System

The **urinary bladder** and visible pelvic urethra were unremarkable for the level of repletion presented. The urine, however, did present some mildly echogenic debris consistent with mucous, exfoliated cells from renal or bladder origin, and/or blood clots as these echogenic changes can all present similarly. This is often related to urinary tract infection but may represent simple evidence of exfoliated debris or sterile inflammation. Cystocentesis, urinalysis, +/- culture would be recommended to rule out and define any UTI.

BREED

Domestic Shorthair

SEX

Neutered male

The **kidneys** revealed normal size and structure, corticomedullary definition and ratio for this age. The cortices presented largely uniform texture with normal echogenic relationship to liver and spleen. Medullary structure differed distinctly from the cortex and no evidence of pelvic dilation was present. The capsules were acceptably uniform without significant irregularities. Hyperechoic medullary rim sign was noted in both kidneys with slight cortical infarcts, yet are stable. Medullary rim sign is idiopathic, but can be associated with FIP. The left kidney measured 4.46 cm. The right kidney measured 4.5 cm.

AGE
5 years

WEIGHT
16.4 lbs

ULTRASONOGRAPHIC FINDINGS

Bladder debris.
Medullary rim kidney with slight cortical infarcts.

INTERPRETED BY

Eric Lindquist, DMV
DABVP, Cert. IVUSS

INTERPRETATION OF THE FINDINGS & FURTHER RECOMMENDATIONS

Renal biopsy would be necessary for further definition. Idiopathic cystitis versus primary renal disease and occult UTI are all possible causes. Renal biopsy can be considered to assess for possibility of dry form FIP or confirm suspicion of interstitial nephrosis.

IMAGING PERFORMED BY

Dr. Barnea

HOSPITAL NAME

Tenaflly VC

REFERRING VET

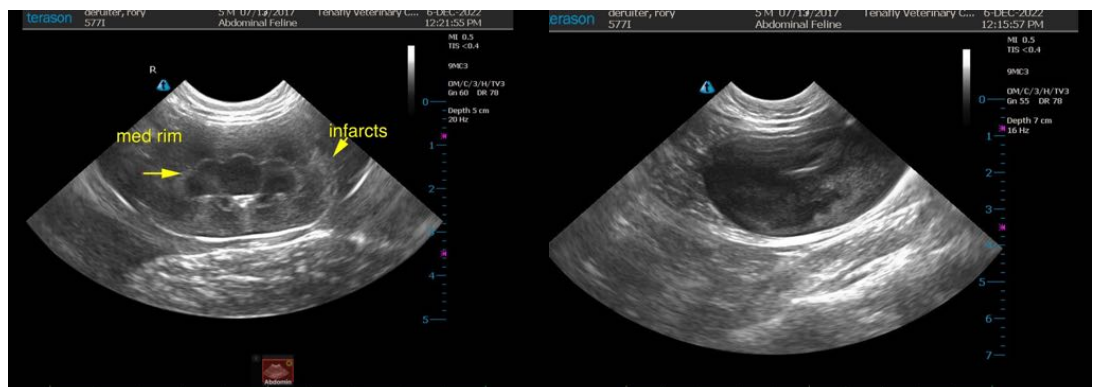
Dr. Barnea

INVOICE

42908

DATE

12/6/22





PATIENT

Rory Deruiter

SPECIES

Feline

BREED

Domestic Shorthair

SEX

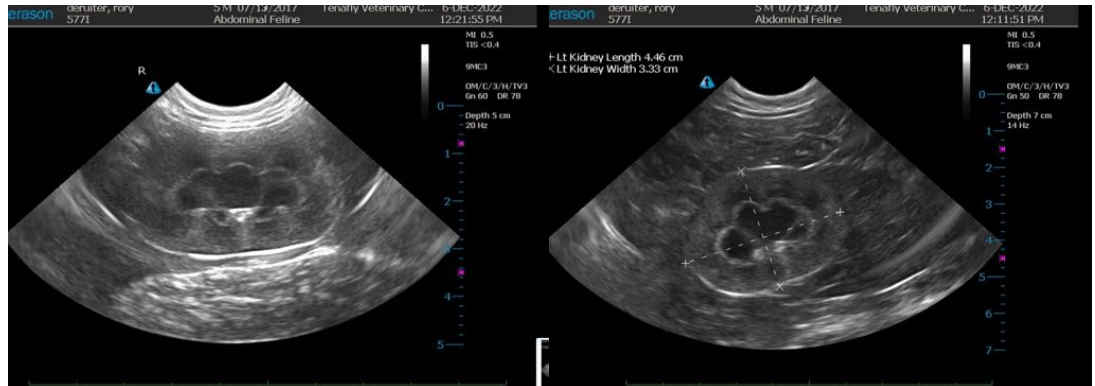
Neutered male

AGE

5 years

WEIGHT

16.4 lbs



The information and recommendations provided are based on the images presented by the referring veterinarian/sonographer. No evaluation can be communicated regarding pathology that was not visible in the image/video clips provided.

Thank you for this referral. If the clinical or image interpretation does not parallel your findings or if I can be of any further assistance please contact me.

Eric Lindquist, DMV, DABVP, Cert. IVUSS, CEO of SonoPath.com
info@SonoPath.com

INTERPRETED BY

Eric Lindquist, DMV
DABVP, Cert. IVUSS

IMAGING PERFORMED BY

Dr. Barnea

HOSPITAL NAME

Tenafly VC

REFERRING VET

Dr. Barnea

INVOICE

42908

DATE

12/6/22