



PATIENT

Kailee Pullen

SPECIES

Canine

BREED

Yorkiepoop

SEX

Canine

AGE

4 Years

WEIGHT

9.68 Pounds

INTERPRETED BY

Eric Lindquist, DMV
DABVP, Cert. IVUSS

IMAGING PERFORMED BY

Marti Williams

HOSPITAL NAME

Limestone VH

REFERRING VET

Marti Williams

INVOICE

19038

DATE

12/6/22

PRESENTING CLINICAL SIGNS

History: Lethargy, inappetence and vomiting x one week. General history of GI indiscretion but nothing known recently. CBC, Chemistry and examination unremarkable other than mild dehydration. P ate a little more than a tbsp of her breakfast this AM but did not vomit afterward. P last vomited last night at 5:30pm.

ULTRASONOGRAPHIC EXAMINATION OF THE ABDOMEN

Urinary System

The **urinary bladder**, trigone, and pelvic urethra presented normal thicknesses and normal tone. The ureters were not visible which is normal. No uroliths or sediment were visualized and anechoic urine was present. No evidence of inflammatory or neoplastic changes were noted. Ureteral papillae were normal.

The **kidneys** revealed normal size and structure, corticomedullary definition and ratio for this age. The cortices presented largely uniform texture with normal echogenic relationship to liver and spleen. Medullary structure differed distinctly from the cortex and no evidence of pelvic dilation was present. The capsules were acceptably uniform without significant irregularities. The right kidney measured 4.5 cm. The left kidney measured 3.6 cm.

Adrenal Glands

Both **adrenal glands** were visualized and recognized as having normal shape, size, position and echogenicity for this breed. The phrenic vasculature, glandular echogenicity and detail were unremarkable. Capsule, cortex, and medullary definition were normal for this age patient. The left adrenal gland measured 0.27 cm. The right adrenal gland measured 0.6 cm at the cranial pole and 0.4 cm at the caudal pole.

Spleen

The **spleen** presented a smooth homogeneous parenchyma hyperechoic to liver and renal cortical parenchyma. The capsule was smooth without noticeable expansion or deviation from within the spleen or adjacent pathology. The splenic vasculature demonstrated normal volume without signs of congestion or thrombosis. No sonographic evidence of acute or chronic inflammatory, neoplastic, or infarctual changes were noted.

Liver

The **liver** revealed minor uniform enlargement with normal contour and structure. Parenchymal echogenicity was naturally coarse and hypoechoic to the spleen. Vascular and biliary tracts were of normal volume with no evidence of congestion. The gallbladder presented acceptably thin walls with primarily anechoic content. The cystic and common bile ducts were normal. No pathological hepatic lymphadenopathy was evident. No overt structural evidence of inflammatory, infiltrative or regenerative pathology was evident.

Gastrointestinal

There was some residual chyme and gas was noted in the **stomach**, yet not pathological. This is consistent with end post prandial presentation. Transit of chyme into the small intestine was normal. Curvilinear patterns were maintained throughout the GI tract. No evidence of pathology. Small and



PATIENT

Kailee Pullen

large intestine demonstrated normal luminal chyme and stool consistency respectively. No obstructive or overt infiltrative disease was noted. No associated abnormal lymphatic activity was noted.

SPECIES

Canine

Pancreas

The base and limbs of the **pancreas** were observed to be largely isoechoic to surrounding omental fat. Pancreatic duct and capsular contour were acceptably normal and parenchyma respected normal curvilinear patterns. No overt evidence of active inflammatory or neoplastic disease was noted.

BREED

Yorkiepoop

ULTRASONOGRAPHIC FINDINGS

- Minor retention of ingesta
- Minor uniform hepatic enlargement

SEX

Canine

INTERPRETATION OF THE FINDINGS & FURTHER RECOMMENDATIONS

No evidence of significant pathology. If the patient was NPO at the time of the sonogram, soft foreign matter such as grass or similar may be in the stomach. Other causes of inappetence, such as orthopedic pain, CNS disease or thoracic disease should be considered. Empirical treatment for gastritis may prove effective in this patient, yet no evidence of significant disease.

AGE

4 Years

WEIGHT

9.68 Pounds

INTERPRETED BY

Eric Lindquist, DMV
DABVP, Cert. IVUSS

IMAGING PERFORMED BY

Marti Williams

HOSPITAL NAME

Limestone VH

REFERRING VET

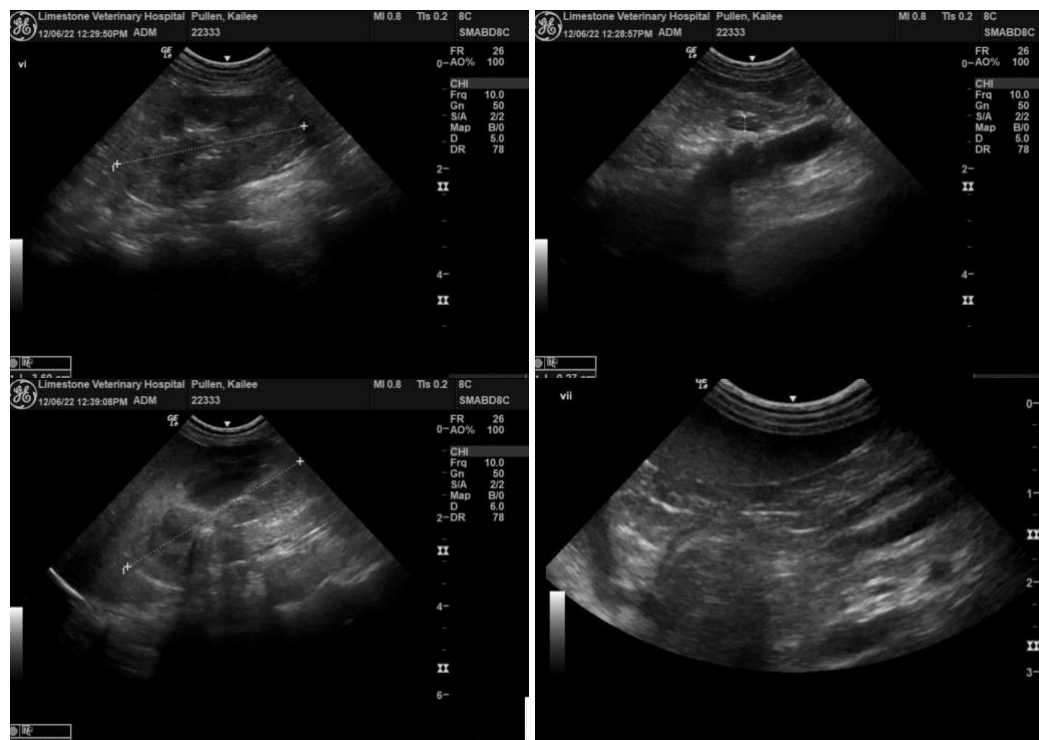
Marti Williams

INVOICE

19038

DATE

12/6/22





PATIENT

Kailee Pullen

SPECIES

Canine

BREED

Yorkiepoop

SEX

Canine

AGE

4 Years

WEIGHT

9.68 Pounds

INTERPRETED BY

Eric Lindquist, DMV
DABVP, Cert. IVUSS

IMAGING PERFORMED BY

Marti Williams

HOSPITAL NAME

Limestone VH

REFERRING VET

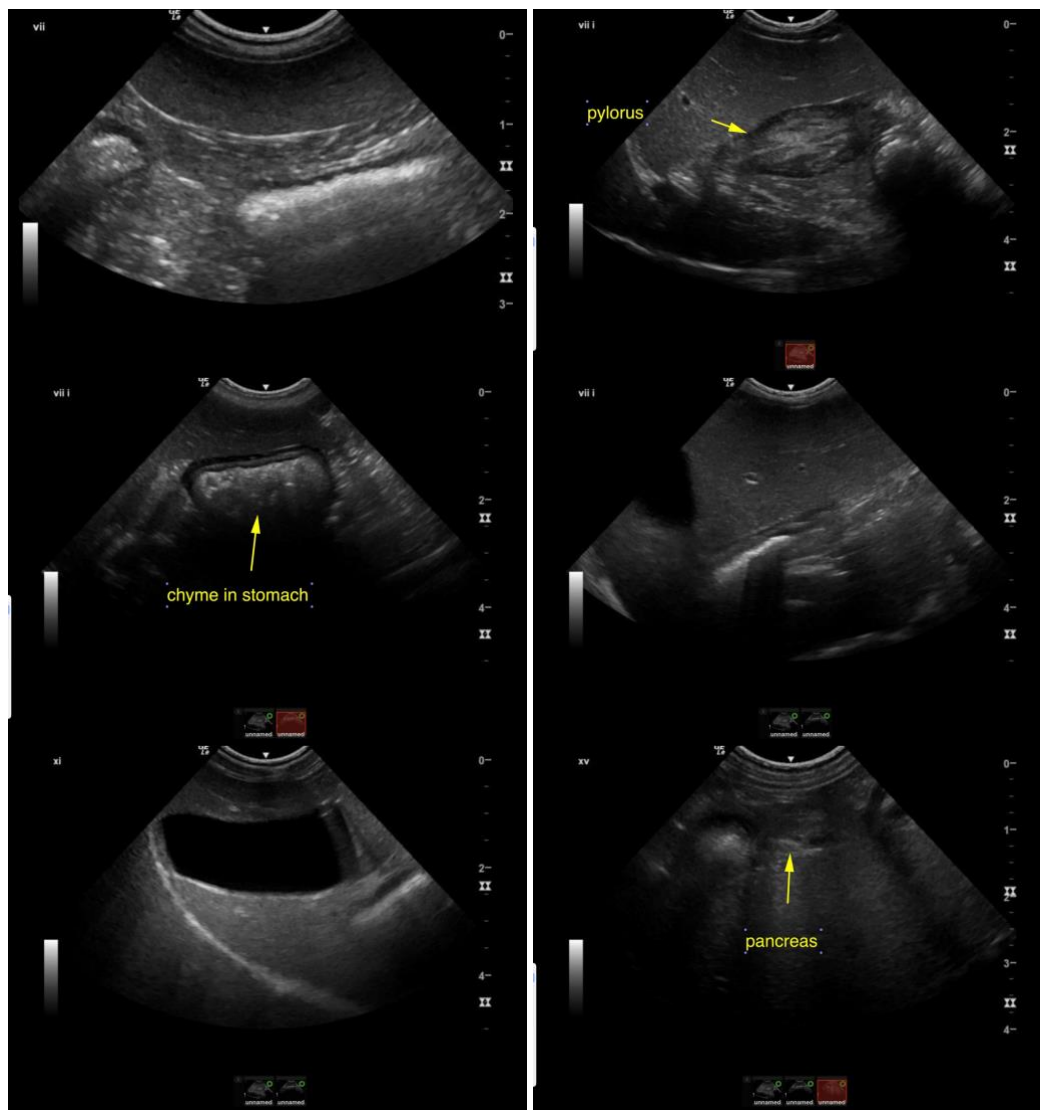
Marti Williams

INVOICE

19038

DATE

12/6/22



The information and recommendations provided are based on the images presented by the referring veterinarian. No evaluation can be communicated regarding pathology that was not visible in the image/video clips provided.

Thank you for this referral. If the clinical or image interpretation does not parallel your findings or if I can be of any further assistance please contact me.

Eric Lindquist, DMV, DABVP, Cert. IVUSS, CEO of SonoPath.com
info@SonoPath.com