



PATIENT

Phoebe Herig

PRESENTING CLINICAL SIGNS

straining to urinate, accidents in the house, increased urination and drinking, owner reports doing better recently

SPECIES

Canine

ULTRASONOGRAPHIC EXAMINATION OF THE ABDOMEN

Urinary System

BREED

Beagle

The **urinary bladder**, trigone, and pelvic urethra presented normal thicknesses and normal tone. The ureters were not visible which is normal. No uroliths or sediment were visualized and anechoic urine was present. No evidence of inflammatory or neoplastic changes were noted. Ureteral papillae were normal. The pelvic urethra was imaged 3.0 cm beyond the cystourethral junction. The pelvic urethra was imaged 3.0 cm beyond the cystourethral junction.

SEX

Spayed Female

The **kidneys** revealed normal size and structure, corticomedullary definition and ratio for this age. The cortices presented largely uniform texture with normal echogenic relationship to liver and spleen. Medullary structure differed distinctly from the cortex and no evidence of pelvic dilation was present. The capsules were acceptably uniform without significant irregularities. The right kidney measured 5.44 cm. The left kidney measured 5.28 cm.

AGE

7 Years

Adrenal Glands

WEIGHT

31.5 Pounds

Both **adrenal glands** were visualized and recognized as having normal shape, size, position and echogenicity for this breed. The phrenic vasculature, glandular echogenicity and detail were unremarkable. Capsule, cortex, and medullary definition were normal for this age patient. The right adrenal gland measured 2.41 cm x 1.48 cm at the cranial pole and 0.88 cm at the caudal pole.

INTERPRETED BY

Eric Lindquist, DMV
DABVP, Cert. IVUSS

Spleen

The **spleen** presented a smooth homogeneous parenchyma hyperechoic to liver and renal cortical parenchyma. The capsule was smooth without noticeable expansion or deviation from within the spleen or adjacent pathology. The splenic vasculature demonstrated normal volume without signs of congestion or thrombosis. No sonographic evidence of acute or chronic inflammatory, neoplastic, or infarctual changes were noted.

IMAGING PERFORMED BY

Jenn

Liver

HOSPITAL NAME

Rockaway AH

The **liver** presented heterogenous parenchyma with increased portal markings and coarse architecture. Slight undulating capsular contour was noted. The gallbladder and common bile duct were unremarkable. This is consistent with chronic inflammatory hepatopathy.

Gastrointestinal

REFERRING VET

Dr. Maniar

Examination of the **gastrointestinal tract** revealed a stomach and intestine free of stasis, of normal wall thickness, acceptable curvilinear mural detail, and peristaltic activity. Small and large intestine demonstrated normal luminal chyme and stool consistency respectively. No obstructive or overt infiltrative disease was noted. No associated abnormal lymphatic activity was noted.

INVOICE

33291

Pancreas

The base and limbs of the **pancreas** were observed to be largely isoechoic to surrounding omental fat. Pancreatic duct and capsular contour were acceptably normal and parenchyma respected normal curvilinear patterns. No overt evidence of active inflammatory or neoplastic disease was noted.

DATE

12/6/21



PATIENT

Phoebe Herig

ULTRASONOGRAPHIC FINDINGS

- Structurally unremarkable abdomen

SPECIES

Canine

INTERPRETATION OF THE FINDINGS & FURTHER RECOMMENDATIONS

No evidence of underlying pathology in the urinary bladder or proximal urethra. Deep pelvic urethral pathology could not be ruled out. However, the 3.0 cm of the urethra post cystourethral junction was absolutely normal. Examination of the vaginal vestibule warranted.

BREED

Beagle

SEX

Spayed Female

AGE

7 Years

WEIGHT

31.5 Pounds

INTERPRETED BY

Eric Lindquist, DMV
DABVP, Cert. IVUSS

IMAGING PERFORMED BY

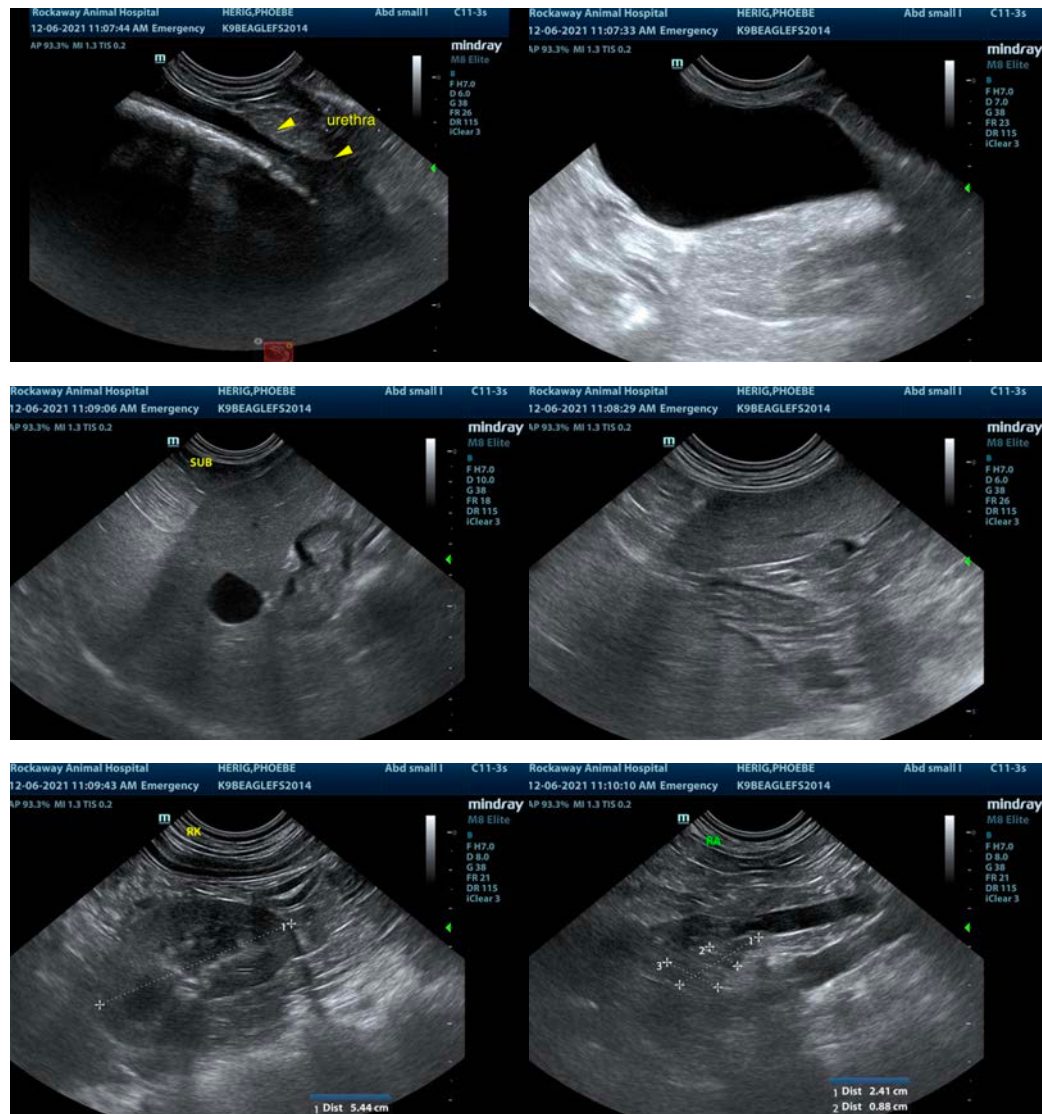
Jenn

HOSPITAL NAME

Rockaway AH

REFERRING VET

Dr. Maniar



INVOICE

33291

DATE

12/6/21



PATIENT

Phoebe Herig

SPECIES

Canine

BREED

Beagle

SEX

Spayed Female

AGE

7 Years

WEIGHT

31.5 Pounds

INTERPRETED BY

Eric Lindquist, DMV
DABVP, Cert. IVUSS

**IMAGING
PERFORMED BY**

Jenn

HOSPITAL NAME

Rockaway AH

REFERRING VET

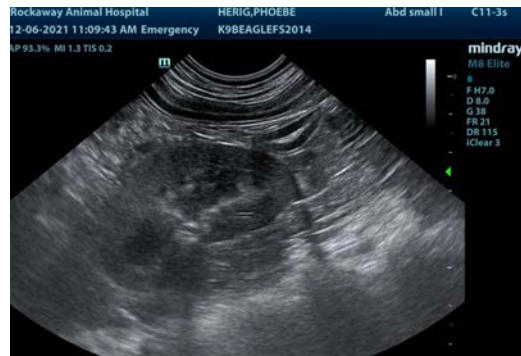Dr. Maniar

INVOICE

33291

DATE

12/6/21



The information and recommendations provided are based on the images presented by the referring veterinarian. No evaluation can be communicated regarding pathology that was not visible in the image/video clips provided.

Thank you for this referral. If the clinical or image interpretation does not parallel your findings or if I can be of any further assistance please contact me.

Eric Lindquist, DMV, DABVP, Cert. IVUSS, CEO of SonoPath.com
info@SonoPath.com