

**DATE**

12/6/21

PRESENTING CLINICAL SIGNS

History: Elevated ALT after being on Denamarin.
 Current Medications: Denamarin Advanced Small Dog (<51 lbs).
 Lab Results: Elevated ALT. Attached separately.
 Date of Previous IntraPet Ultrasound: No previous IntraPet scans.
 Sedation: Not required to complete full diagnostic ultrasound.
 Stat Report: Not requested.

PATIENT

Goose Karls

SPECIES

Canine

BREED

Australian Cattle Dog

SEX

Neutered male

AGE

8/8/17

WEIGHT

50 lbs

INTERPRETED BY

Eric Lindquist, DMV,
 DABVP, Cert. IVUSS,
 CEO of SonoPath.com

IMAGING PERFORMED BY

Rachel Brillhart RDMS

HOSPITAL NAME

Lake Shore AH

REFERRING VET

Dr. Stiehl

INVOICE**ULTRASONOGRAPHIC EXAMINATION OF THE ABDOMEN****Urinary System**

The **urinary bladder**, trigone, and pelvic urethra presented normal thicknesses and normal tone. The ureters were not visible which is normal. No uroliths or sediment were visualized and anechoic urine was present. No evidence of inflammatory or neoplastic changes was noted. Ureteral papillae were normal.

The residual prostate was slightly enlarged and measured 1.4 cm. There were slight areas of mineralization noted.

The **kidneys** revealed normal size and structure, corticomedullary definition and ratio for this age. The cortices presented largely uniform texture with normal echogenic relationship to liver and spleen. Medullary structure differed distinctly from the cortex and no evidence of pelvic dilation was present. The capsules were acceptably uniform without significant irregularities. The right kidney measured 6.06 cm.

Adrenal Glands

Both **adrenal glands** were visualized and recognized as having normal shape, size, position and echogenicity for this breed. The phrenic vasculature, glandular echogenicity and detail were unremarkable. Capsule, cortex, and medullary definition were normal for this age patient. The left adrenal gland measured 2.87 x 0.74 cm at the caudal pole and 0.67 cm at the cranial pole. The right adrenal gland measured 3.61 x 0.9 cm at the caudal pole and 0.82 cm at the cranial pole.

Spleen

The **spleen** revealed hypoechoic nodular changes and were non-disrupted measuring 0.98 cm. Coarse architecture was noted elsewhere in the spleen.

Liver

The **liver** presented heterogenous parenchyma with increased portal markings and coarse architecture. Slight undulating capsular contour was noted. The gallbladder and common bile duct were unremarkable. This is consistent with chronic inflammatory hepatopathy.

Gastrointestinal

Examination of the **gastrointestinal tract** revealed a stomach and intestine free of stasis, of normal wall thickness, acceptable curvilinear mural detail, and peristaltic activity. Small and large intestine demonstrated normal luminal chyme and stool consistency respectively. No obstructive or overt infiltrative disease was noted. No associated abnormal lymphatic activity was noted.

Pancreas

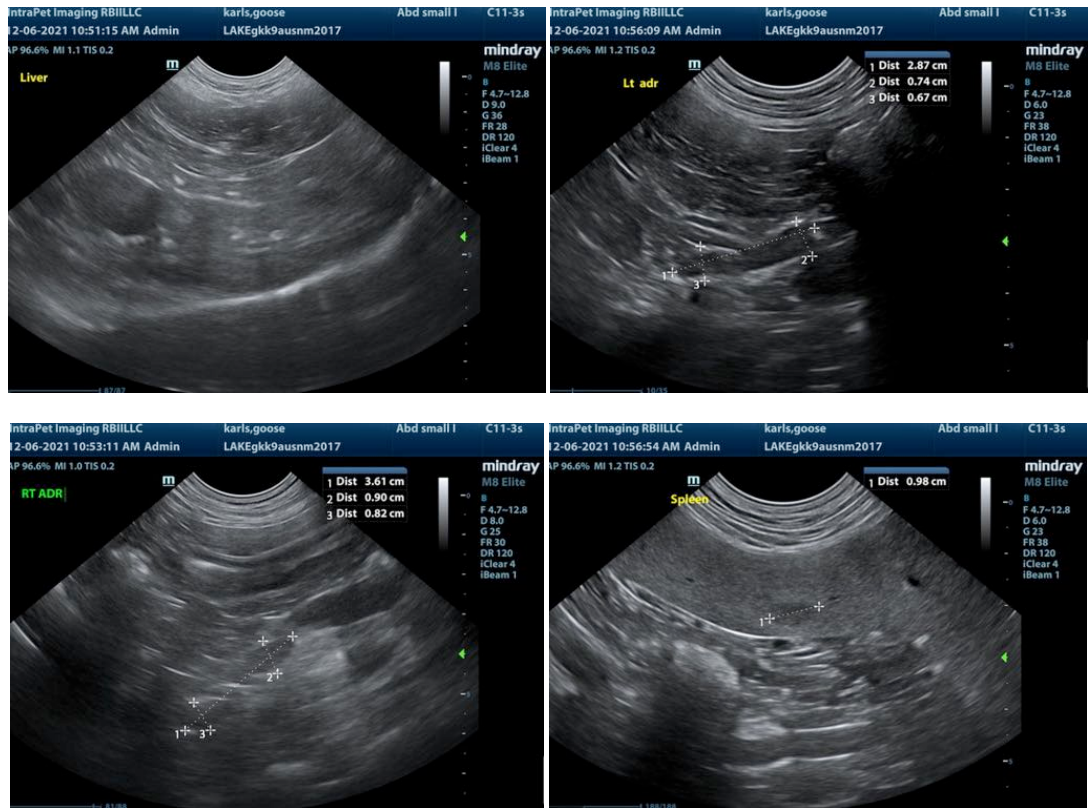
The base and limbs of the **pancreas** were observed to be largely isoechoic to surrounding omental fat. Pancreatic duct and capsular contour were acceptably normal and parenchyma respected normal curvilinear patterns. No overt evidence of active inflammatory or neoplastic disease was noted.

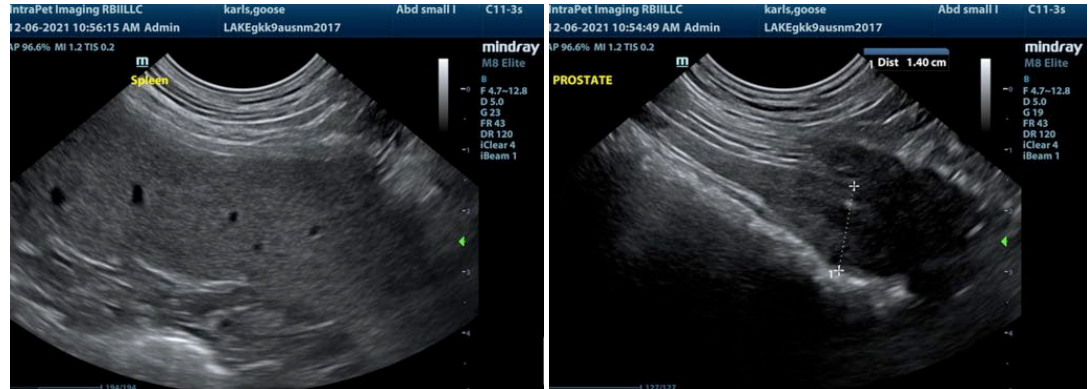
ULTRASONOGRAPHIC FINDINGS

Non-specific, chronic inflammatory hepatopathy.
Slightly prominent prostate.

INTERPRETATION OF THE FINDINGS & FURTHER RECOMMENDATIONS

Core biopsy or FNA is indicated to assess inflammatory cell type. Bile acid profile is indicated. Leptospirosis titers are indicated to rule out subclinical disease. If any straining to urinate is present in this patient's history then traumatic catheterization of the prostate is warranted. However, neutering during prostatitis or similar may have created this type of remodeled presentation.





The information and recommendations provided are based on the images presented by the referring veterinarian. No evaluation can be communicated regarding pathology that was not visible in the image/video clips provided.

Thank you for this referral. If the clinical or image interpretation does not parallel your findings or if I can be of any further assistance please contact me.

Eric Lindquist, DMV, DABVP, Cert. IVUSS, CEO of SonoPath.com
Eric.Lindquist@SonoPath.com