



PATIENT

Seymour Hill

SPECIES

Canine

BREED

Dachshund

SEX

Neutered Male

AGE

12 Years 10 Months

WEIGHT

16 lbs

INTERPRETED BY

Eric Lindquist, DMV,
DABVP (CFM), Cert.
IVUSS

IMAGING PERFORMED BY

Kevin Moon, DVM

HOSPITAL NAME

Shiloh Veterinary
Hospital

REFERRING VET

Stephanie Herr, VMD

INVOICE

72403

DATE

12/5/25

PRESENTING CLINICAL SIGNS

Pre-surgical bloodwork for a dental showed elevated liver values. P clinically doing well

Abnormal PE/Chem/CBC/UA Results: AST (SGOT) 71IU/L (15-66) ALT (SGPT) 140IU/L (12-118) Alk Phosphatase 387IU/L (5-131)

ULTRASONOGRAPHIC EXAMINATION OF THE ABDOMEN

Urinary System

The **urinary bladder**, trigone, and pelvic urethra presented normal thicknesses and normal tone. The ureters were not visible which is normal. No uroliths or sediment were visualized and anechoic urine was present. No evidence of inflammatory or neoplastic changes were noted. Ureteral papillae were normal. The pelvic urethra was imaged 1.0 cm beyond the cystourethral junction.

The **kidneys** revealed largely normal size and structure, corticomedullary definition and ratio (cortex 1/3 of medulla) were essentially maintained with some age-related loss of curvilinear patterns regarding the capsule and C/M junction. The cortices presented largely uniform texture with some increased echogenicity expected for his age patient. Medullary structure differed distinctly from that of the cortex and no evidence of pelvic dilation was present. Left kidney measured 5.3 cm. Right kidney measured 5.3 cm.

Adrenal Glands

Both **adrenal glands** were visualized and recognized as having normal shape, size, position and echogenicity for this breed. The phrenic vasculature, glandular echogenicity and detail were unremarkable. Capsule, cortex, and medullary definition were normal for this age patient. Left measured 0.60 cm. Right adrenal gland measured 0.85 cm at the cranial pole and 0.50 cm at the caudal pole.

Spleen

The **spleen** was largely smooth with subtle heterogeneous parenchymal changes while maintaining normal echogenic relationship to the liver and kidney. These changes are consistent with normal age-related alteration. The capsule was smooth without noticeable impingement from within the spleen or from pathology in the adjacent abdomen. Minor microcystic changes noted on the cranial body, measuring up to 0.70 cm x 0.50 cm. The splenic vasculature demonstrated normal volume without signs of congestion or significant contraction.

Liver

The **liver** presented normal size and contour. Parenchyma was uniform. Minor gallbladder calculi noted with minimal shadowing.

Gastrointestinal

Examination of the **gastrointestinal tract** revealed a stomach and intestine free of stasis, of normal wall thickness, acceptable curvilinear mural detail, and peristaltic activity. Small and large intestine demonstrated normal luminal chyme and stool consistency respectively. No obstructive or overt infiltrative disease was noted. No associated abnormal lymphatic activity was noted.



PATIENT

Seymour Hill

SPECIES

Canine

BREED

Dachshund

SEX

Neutered Male

AGE

12 Years 10 Months

WEIGHT

16 lbs

INTERPRETED BY

Eric Lindquist, DMV,
DABVP (CFM), Cert.
IVUSS

IMAGING PERFORMED BY

Kevin Moon, DVM

HOSPITAL NAME

Shiloh Veterinary
Hospital

REFERRING VET

Stephanie Herr, VMD

INVOICE

72403

DATE

12/5/25

Pancreas

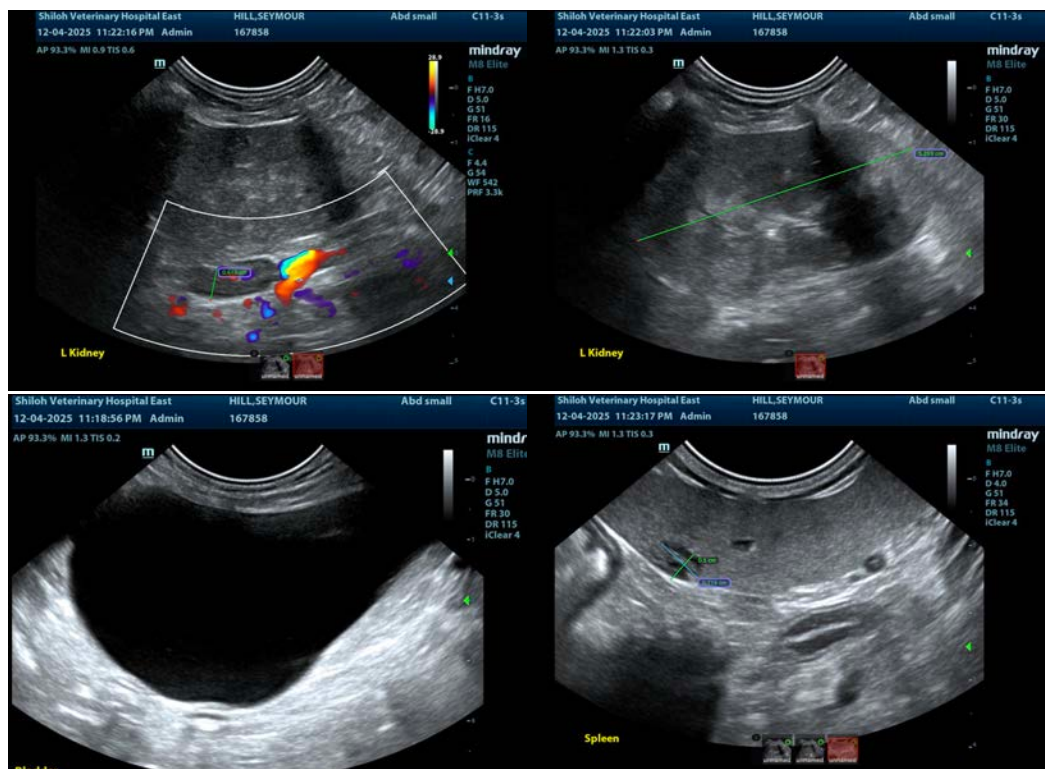
The base and limbs of the **pancreas** were observed to be largely isoechoic to surrounding omental fat. Pancreatic duct and capsular contour were acceptably normal and parenchyma respected normal curvilinear patterns. No overt evidence of active inflammatory or neoplastic disease was noted.

ULTRASONOGRAPHIC FINDINGS

- Splenic cysts.
- Benign hepatopathy, likely reactive hepatopathy.

INTERPRETATION OF THE FINDINGS & FURTHER RECOMMENDATIONS

No evidence of significant disease. The hepatic clinical sonographic presentation is most consistent with Reactive Hepatopathy which is the most common cause of liver enzyme elevation in dogs and cats. The presumption is that gut and other organ antigen stimuli may be causing a low-grade immune response through portal system with which the liver is reacting to causing low-grade enzyme elevations. US-guided FNA could be performed to assess if low grade lymphoplasmacytic inflammation is present that would support this theory. If FNA is performed, please ask the cytologist to emphasize the primary inflammatory cell type. Empirical treatment measures to address this issue can include diet change to hydrolyzed diet, probiotics, deworming, nutraceuticals (SAME, Actigall...), dental exam and cleaning, and potentially antibiotics such as Clavamox. Metronidazole and Tylosin have traditionally been utilized for this purpose but new studies show that both these antibiotics can disrupt the normal intestinal bacterial flora (intestinal dysbiosis) for weeks and up to 4-6 months. Therefore, Metronidazole and Tylosin should be utilized as a last resort if other efforts have not been effective and sonographic organ appearance remains benign.





PATIENT

Seymour Hill

SPECIES

Canine

BREED

Dachshund

SEX

Neutered Male

AGE

12 Years 10 Months

WEIGHT

16 lbs

INTERPRETED BY

Eric Lindquist, DMV,
DABVP (CFM), Cert.
IVUSS

IMAGING PERFORMED BY

Kevin Moon, DVM

HOSPITAL NAME

Shiloh Veterinary
Hospital

REFERRING VET

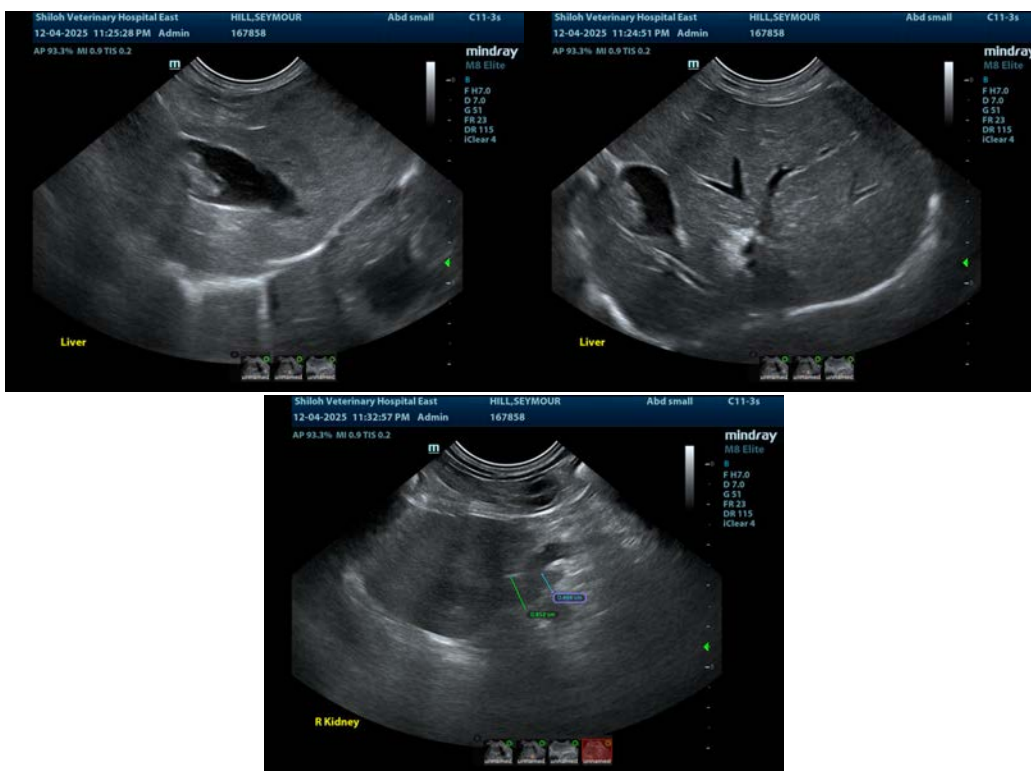
Stephanie Herr, VMD

INVOICE

72403

DATE

12/5/25



The information and recommendations provided are based on the images presented by the referring veterinarian/sonographer. No evaluation can be communicated regarding pathology that was not visible in the image/video clips provided.

Thank you for this referral. If the clinical or image interpretation does not parallel your findings or if I can be of any further assistance please contact me.

Eric Lindquist, DMV, DABVP(CFM), Cert. IVUSS,
CEO, Owner, Founder -- SonoPath.com
info@SonoPath.com