



**PATIENT**

Mochi Kwok

**SPECIES**

Canine

**BREED**

Shih Tzu

**SEX**

Neutered Male

**AGE**

7 Years 7 Months

**WEIGHT**

16.75 lbs

**INTERPRETED BY**

Eric Lindquist, DMV,  
DABVP (CFM), Cert.  
IVUSS

**IMAGING PERFORMED BY**

Vincent Ravancho, CVT

**HOSPITAL NAME**

Martinsville Veterinary  
Hospital

**REFERRING VET**

Dr. Shendell

**INVOICE**

72385

**DATE**

12/5/25

**PRESENTING CLINICAL SIGNS**

Check urinary tract for stones. History of recurrent cystoliths and urethral obstruction. Current meds: Rx urinary diet, preventatives.

Abnormal PE/Chem/CBC/UA Results: U/A 10-15 RBC /hpf 2+ CaOX (6-20) /hpf USG 1.0054 Plt 307 HCT 46.6

**ULTRASONOGRAPHIC EXAMINATION OF THE ABDOMEN**

**Urinary System**

The **urinary bladder** revealed a calculus measuring 0.60 cm. Largely anechoic urine present. Minimal amount of urine present at the time of the sonogram. Bladder wall was mildly thickened. Smaller calculi also noted up to 0.38 cm, non-obstructive at the time of the sonogram. The pelvic urethra was imaged 3.0 cm beyond the cystourethral junction.

The prostate was uniform at 1.0 cm.

The **kidneys** revealed normal size and structure, corticomedullary definition and ratio for this age. The cortices presented largely uniform texture with normal echogenic relationship to liver and spleen. Medullary structure differed distinctly from the cortex and no evidence of pelvic dilation was present. The capsules were acceptably uniform without significant irregularities. Right measured 4.42 cm. Left measured 3.5 cm.

**Adrenal Glands**

Both **adrenal glands** were visualized and recognized as having normal shape, size, position and echogenicity for this breed. The phrenic vasculature, glandular echogenicity and detail were unremarkable. Capsule, cortex, and medullary definition were normal for this age patient. Left measured 1.5 cm x 0.47 cm at the cranial pole and 0.47 cm at the caudal pole. Right measured 1.5 cm x 0.71 cm at the cranial pole and 0.45 cm at the caudal pole.

**Spleen**

The **spleen** presented a smooth homogeneous parenchyma hyperechoic to liver and renal cortical parenchyma. The capsule was smooth without noticeable expansion or deviation from within the spleen or adjacent pathology. The splenic vasculature demonstrated normal volume without signs of congestion or thrombosis. No sonographic evidence of acute or chronic inflammatory, neoplastic, or infarctual changes were noted.

**Liver**

The **liver** images submitted revealed subjectively normal liver size, contour, and structure. Parenchymal echogenicity was naturally coarse and hypoechoic to the spleen. Vascular and biliary tracts were of normal volume with no evidence of congestion. The gallbladder presented acceptably thin walls with primarily anechoic content. The cystic and common bile ducts were normal. No pathological hepatic lymphadenopathy was evident. No overt structural evidence of inflammatory, infiltrative or regenerative pathology was evident.



**PATIENT**

Mochi Kwok

**SPECIES**

Canine

**BREED**

Shih Tzu

**SEX**

Neutered Male

**AGE**

7 Years 7 Months

**WEIGHT**

16.75 lbs

**INTERPRETED BY**

Eric Lindquist, DMV,  
DABVP (CFM), Cert.  
IVUSS

**IMAGING PERFORMED BY**

Vincent Ravancho, CVT

**HOSPITAL NAME**

Martinsville Veterinary  
Hospital

**REFERRING VET**

Dr. Shendell

**INVOICE**

72385

**DATE**

12/5/25

**Gastrointestinal**

Examination of the **gastrointestinal tract** revealed a stomach and intestine free of stasis, of normal wall thickness, acceptable curvilinear mural detail, and peristaltic activity. Small and large intestine demonstrated normal luminal chyme and stool consistency respectively. No obstructive or overt infiltrative disease was noted. No associated abnormal lymphatic activity was noted.

**Pancreas**

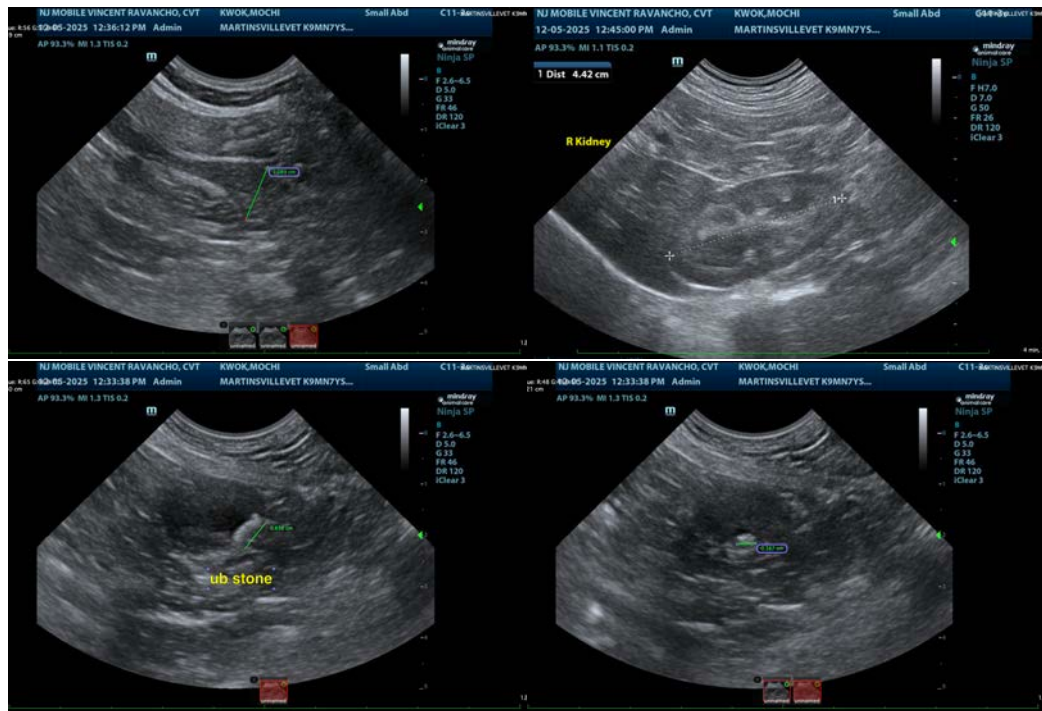
The base and limbs of the **pancreas** were observed to be largely isoechoic to surrounding omental fat. Pancreatic duct and capsular contour were acceptably normal and parenchyma respected normal curvilinear patterns. No overt evidence of active inflammatory or neoplastic disease was noted.

**ULTRASONOGRAPHIC FINDINGS**

- Urolithiasis, non-obstructive.

**INTERPRETATION OF THE FINDINGS & FURTHER RECOMMENDATIONS**

Cystotomy, stone analysis and culture indicated.





**PATIENT**

Mochi Kwok

**SPECIES**

Canine

**BREED**

Shih Tzu

**SEX**

Neutered Male

**AGE**

7 Years 7 Months

**WEIGHT**

16.75 lbs

**INTERPRETED BY**

Eric Lindquist, DMV,  
DABVP (CFM), Cert.  
IVUSS

**IMAGING PERFORMED BY**

Vincent Ravancho, CVT

**HOSPITAL NAME**

Martinsville Veterinary  
Hospital

**REFERRING VET**

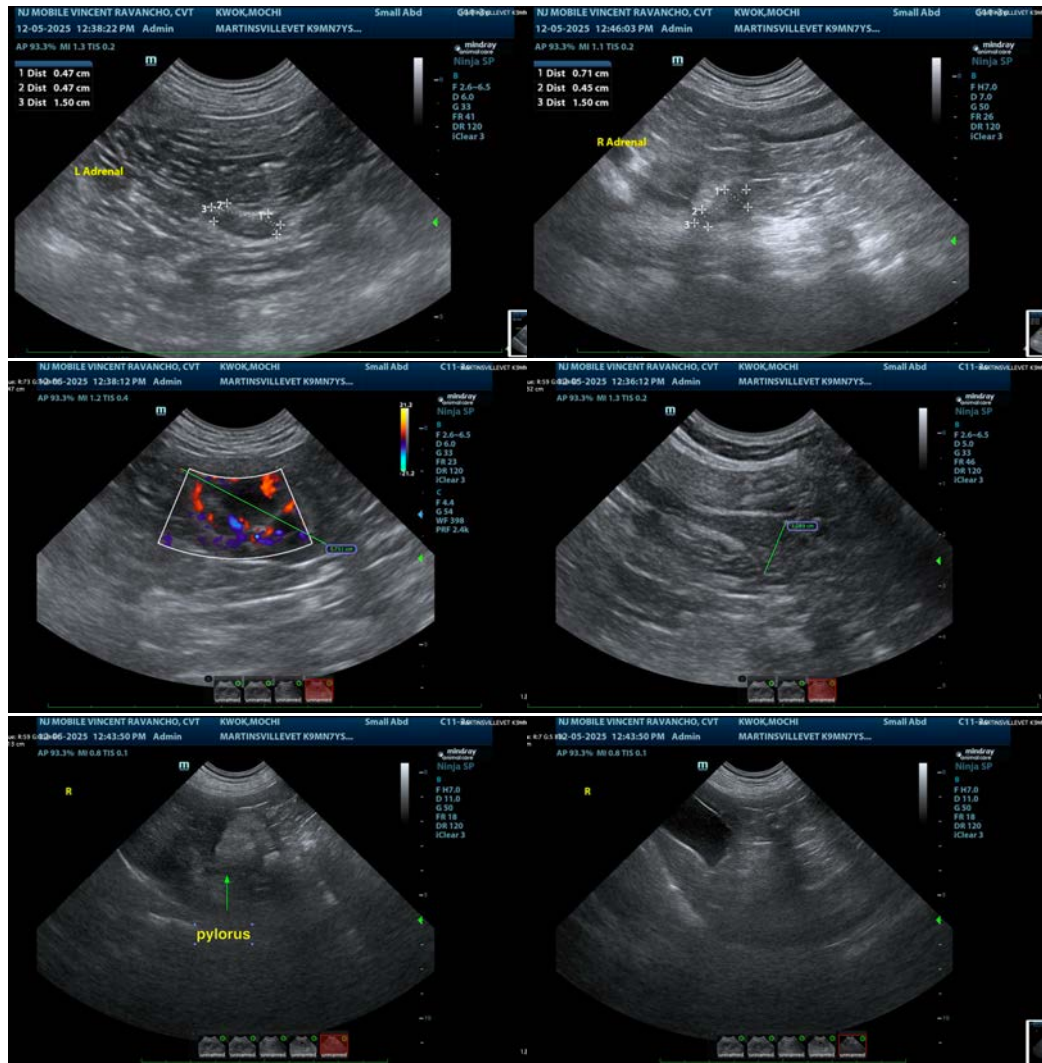
Dr. Shendell

**INVOICE**

72385

**DATE**

12/5/25



The information and recommendations provided are based on the images presented by the referring veterinarian/sonographer. No evaluation can be communicated regarding pathology that was not visible in the image/video clips provided.

Thank you for this referral. If the clinical or image interpretation does not parallel your findings or if I can be of any further assistance please contact me.

**Eric Lindquist, DMV, DABVP(CFM), Cert. IVUSS,**  
CEO, Owner, Founder -- SonoPath.com  
[info@SonoPath.com](mailto:info@SonoPath.com)