



## PATIENT

Billy Wallum

## SPECIES

Canine

## BREED

Cavalier x

## SEX

Male

## AGE

10 Months

## WEIGHT

6.8 lbs

## INTERPRETED BY

Eric Lindquist, DMV,  
DABVP (CFM), Cert.  
IVUSS

## IMAGING PERFORMED BY

Dr. Scott

## HOSPITAL NAME

Wyckoff Veterinary  
Hospital

## REFERRING VET

Dr. Scott

## INVOICE

72394

## DATE

12/5/25

## PRESENTING CLINICAL SIGNS

Routine pre- neuter bloodwork abnormal, pet has picky app but no pu/pd as per owner

Abnormal PE/Chem/CBC/UA Results: BUn 107, Creat 2.3, SDMA 33, Alb 1.9, Glob 4.5, urinalysis urine culture pending but disptick urine +++ protein

## ULTRASONOGRAPHIC EXAMINATION OF THE ABDOMEN

### Urinary System

The **urinary bladder**, trigone, and pelvic urethra presented normal thicknesses and normal tone. The ureters were not visible which is normal. No uroliths or sediment were visualized and anechoic urine was present. No evidence of inflammatory or neoplastic changes were noted. Ureteral papillae were normal.

The prostate was uniform at 1.5 cm.

The **kidneys** revealed normal size and structure, corticomedullary definition and ratio for this age. The cortices presented largely uniform texture with normal echogenic relationship to liver and spleen. Medullary structure differed distinctly from the cortex and no evidence of pelvic dilation was present. The capsules were acceptably uniform without significant irregularities. Left kidney measured 3.0 cm. Right kidney measured 3.6 cm.

### Adrenal Glands

Both **adrenal glands** were visualized and recognized as having normal shape, size, position and echogenicity for this breed. The phrenic vasculature, glandular echogenicity and detail were unremarkable. Capsule, cortex, and medullary definition were normal for this age patient. Left measured 0.30 cm at the cranial pole and 0.30 cm at the caudal pole. Right measured 0.50 cm at the cranial pole and 0.30 cm at the caudal pole.

### Spleen

The **spleen** presented a smooth homogeneous parenchyma hyperechoic to liver and renal cortical parenchyma. The capsule was smooth without noticeable expansion or deviation from within the spleen or adjacent pathology. The splenic vasculature demonstrated normal volume without signs of congestion or thrombosis. No sonographic evidence of acute or chronic inflammatory, neoplastic, or infarctual changes were noted.

### Liver

The **liver** images submitted revealed subjectively normal liver size, contour, and structure. Parenchymal echogenicity was naturally coarse and hypoechoic to the spleen. Vascular and biliary tracts were of normal volume with no evidence of congestion. The gallbladder presented acceptably thin walls with primarily anechoic content. The cystic and common bile ducts were normal. No pathological hepatic lymphadenopathy was evident. No overt structural evidence of inflammatory, infiltrative or regenerative pathology was evident.

### Gastrointestinal

There was some residual chyme and gas was noted in the **stomach**, yet not pathological. This is consistent with end post prandial presentation. Transit of chyme into the small intestine was normal.



## PATIENT

Billy Wallum

## SPECIES

Canine

## BREED

Cavalier x

## SEX

Male

## AGE

10 Months

## WEIGHT

6.8 lbs

## INTERPRETED BY

Eric Lindquist, DMV,  
DABVP (CFM), Cert.  
IVUS

## IMAGING PERFORMED BY

Dr. Scott

## HOSPITAL NAME

Wyckoff Veterinary  
Hospital

## REFERRING VET

Dr. Scott

## INVOICE

72394

## DATE

12/5/25

Curvilinear patterns were maintained throughout the GI tract. No evidence of pathology. Small and large intestine demonstrated normal luminal chyme and stool consistency respectively. No obstructive or overt infiltrative disease was noted. No associated abnormal lymphatic activity was noted.

## Pancreas

The base and limbs of the **pancreas** were observed to be largely isoechoic to surrounding omental fat. Pancreatic duct and capsular contour were acceptably normal and parenchyma respected normal curvilinear patterns. No overt evidence of active inflammatory or neoplastic disease was noted.

## ULTRASONOGRAPHIC FINDINGS

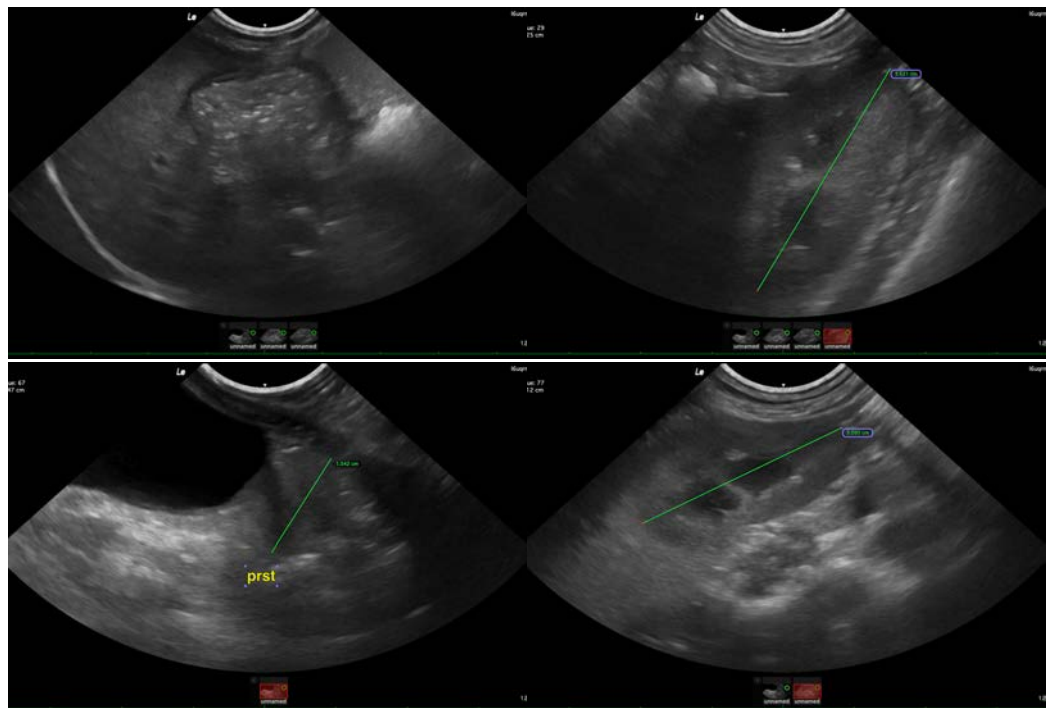
- Structurally unremarkable abdomen with normal kidney structure and size for this breed and age.
- Partially full stomach.

## INTERPRETATION OF THE FINDINGS & FURTHER RECOMMENDATIONS

Causes of subacute insult should be investigated such as toxin exposure or Leptospirosis. Screening for Addison's indicated even though the adrenals appear normal. IV fluid support, GI protectants, urine culture and blood pressures all indicated.

For an additional charge an internal medicine consult can be utilized through [Sonopath.com](http://sonopath.com). You can select the internal medicine drop down at <http://spa.sonopath.com/>.

One of the world's top internists & SonoPath associate Dr. Remo Lobetti BVSc, MMedVet, PhD, DECVIM can evaluate your case through SonoPath. <https://sonopath.com/resources/sonopath-services/internal-medicine-teleconsultation-services>





## PATIENT

Billy Wallum

## SPECIES

Canine

## BREED

Cavalier x

## SEX

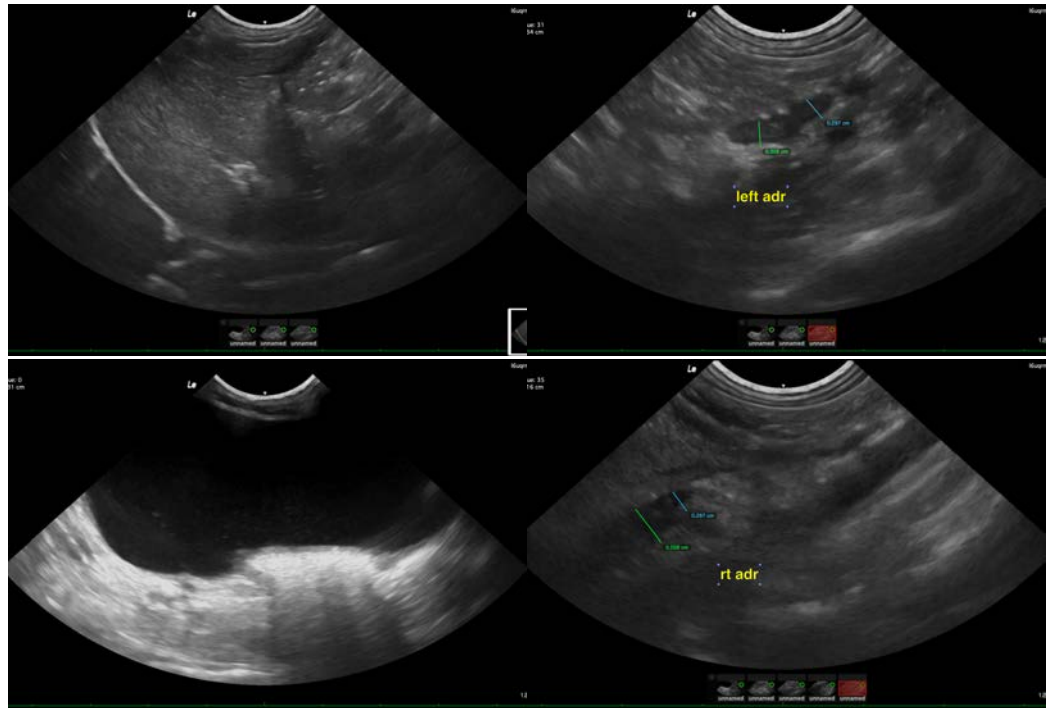
Male

## AGE

10 Months

## WEIGHT

6.8 lbs



## INTERPRETED BY

Eric Lindquist, DMV,  
DABVP (CFM), Cert.  
IVUSS

## IMAGING PERFORMED BY

Dr. Scott

## HOSPITAL NAME

Wyckoff Veterinary  
Hospital

## REFERRING VET

Dr. Scott

## INVOICE

72394

## DATE

12/5/25

The information and recommendations provided are based on the images presented by the referring veterinarian/sonographer. No evaluation can be communicated regarding pathology that was not visible in the image/video clips provided.

Thank you for this referral. If the clinical or image interpretation does not parallel your findings or if I can be of any further assistance please contact me.

Eric Lindquist, DMV, DABVP(CFM), Cert. IVUSS,  
CEO, Owner, Founder -- SonoPath.com  
[info@SonoPath.com](mailto:info@SonoPath.com)