



## PATIENT

Adrienne Walker

## SPECIES

Canine

## BREED

Toy Fox Terrier

## SEX

Spayed female

## AGE

11 years

## WEIGHT

8.6 lbs

## INTERPRETED BY

Eric Lindquist, DMV  
DABVP, Cert. IVUSS

## PRESENTING CLINICAL SIGNS

History: progressive heart d cardiomegaly with perihilar pattern Echo prior to initiating Pimobendan 5/6 HM Owner states no coughing energy levels good. Current meds Lasix 12.5mg 1 BID  
Abnormal PE/Chem/CBC/UA Results: Anaplasma +

## ULTRASONOGRAPHIC EXAMINATION OF THE HEART

The echocardiogram in this patient demonstrated normal **left atrial** size based on 3 different LA measurement methods. Chamber volumes and echogenicity were normal. The cranial and caudal **mitral** valve leaflets presented vegetative thickening consistent with endocardiosis. Prolapse of the anterior mitral valve leaflet was noted. Doppler indicated measurable insufficiency. The **left ventricle** presented thicknesses with linear contour and was not dilated nor restricted. The **myocardium** presented normal echogenicity without subjective evidence of significant fibrotic or ischemic disease. **Contractility** of the ventricular walls was adequate and in normal range for this patient evidenced by the fractional shortening measurement and subjective evaluation of the different regions of the myocardium. The **left ventricular outflow** tract demonstrated normal laminar flow and subjective structural integrity. The **right atrium** and auricle revealed normal size, structure and content. No evidence of masses was noted or chamber overload. **Tricuspid** valvular assessment demonstrated adequate linear morphology. The **right ventricle** was of normal size (1/3 diameter of LV), chordae structure, myocardial echogenicity and thickness. **Pulmonic** tract assessment revealed normal valve structure, laminar flow, and diameter (approx. 1:1 pa/ao ratio). No visible **pericardial** or free pleura fluid was noted. No echographically detectable evidence of infiltrative disease was visible. The cranial **mediastinum and pericardial regions** were free of masses in the visible window. Significant artifact was noted during this scan owing to respiratory stress of the patient.

## IMAGING PERFORMED BY

Jenn

## HOSPITAL NAME

Rocakway AH

## REFERRING VET

Dr. Schiess

## INVOICE

69352

## DATE

12/5/25

CANINE CARDIAC PARAMETERS	MR VMAX (m/s)	TR VMAX (m/s)	LA/AO	LA/AO (Heart Base)	FS (%)	EF (%)	EPSS (cm)
NORMAL PARAMETER	4.5-5.5	<2.7	1.3	<1.6	28-40	40-100	<0.6
PATIENT	6.0	NM	NM	2.0	50	NM	NM
CANINE CARDIAC PARAMETERS	HR (BPM)	AV VMAX (m/s)	PV MAX (m/s)	BODY WEIGHT	LA 2D short axis Base view (cm)	LVIDd Avg; 2D and m-mode short axis (cm)	LVIDs Avg; 2D and m-mode short axis (cm)
NORMAL PARAMETER	50-100	0.7-1.7	0.7-1.6	BELOW	BELOW	BELOW	BELOW
PATIENT	190	NM	NM	8.6 lbs	3.5 max	2.8	



**PATIENT**

Adrienne Walker

**SPECIES**

Canine

**BREED**

Toy Fox Terrier

**SEX**

Spayed female

**AGE**

11 years

**WEIGHT**

8.6 lbs

**INTERPRETED BY**

Eric Lindquist, DMV  
DABVP, Cert. IVUSS

**IMAGING PERFORMED BY**

Jenn

**HOSPITAL NAME**

Rocakway AH

**REFERRING VET**

Dr. Schiess

**INVOICE**

69352

**DATE**

12/5/25

**ULTRASONOGRAPHIC FINDINGS**

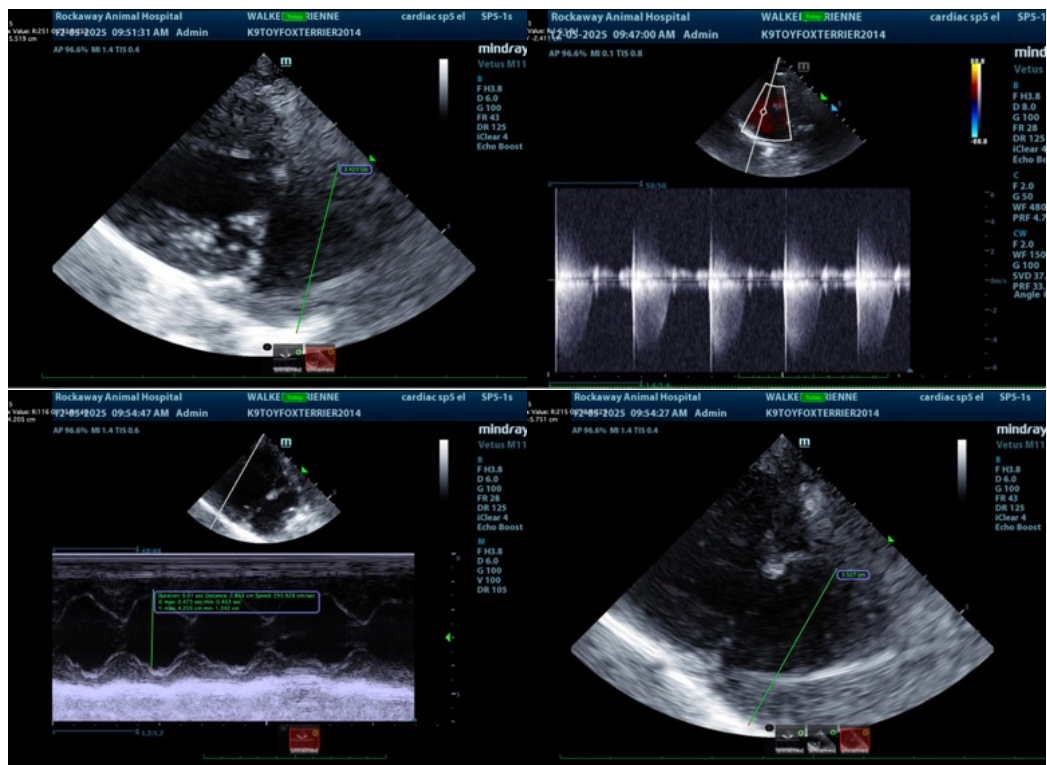
Mitral insufficiency.

Left atrial enlargement, stage B2+-C1 valvular disease.

**INTERPRETATION OF THE FINDINGS & FURTHER RECOMMENDATIONS**

If systolic blood pressure measurements are >160 then ace inhibitor therapy is indicated. I recommend initiating Pimobendan at 0.3 mg/kg b.i.d., ace inhibitor at 0.5 mg/kg s.i.d. progressing to b.i.d. and continuation of Lasix.

The heart is in a somewhat precarious state with volume overload and a heart that is working to compensate for the valvular insufficiency. Target respiratory rate is < 20 resp/minute after therapy. After initiating therapy, I recommend recheck on the clinical exam, BUN, Creatinine, USG, Chest radiographs & Blood pressure in 5-7 days. Recheck echo in 1 month. Earlier if clinical decompensation is occurring. I do not recommend anesthesia at this time until stabilization has occurred on the recommended medications. Repeat preanesthetic echo is ideal if anesthesia is eventually necessary.





## PATIENT

Adrienne Walker

## SPECIES

Canine

## BREED

Toy Fox Terrier

## SEX

Spayed female

## AGE

11 years

## WEIGHT

8.6 lbs

## INTERPRETED BY

Eric Lindquist, DMV  
DABVP, Cert. IVUSS

## IMAGING PERFORMED BY

Jenn

## HOSPITAL NAME

Rocakway AH

## REFERRING VET

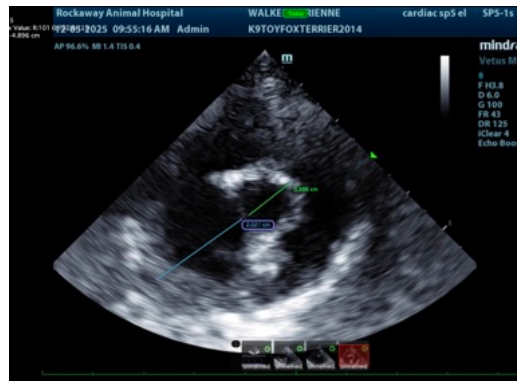
Dr. Schiess

## INVOICE

69352

## DATE

12/5/25



The information and recommendations provided are based on the images presented by the referring veterinarian/sonographer. No evaluation can be communicated regarding pathology that was not visible in the image/video clips provided.

Thank you for this referral. If the clinical or image interpretation does not parallel your findings or if I can be of any further assistance please contact me.

Eric Lindquist, DMV, DABVP (CFM), Cert. IVUSS, CEO of SonoPath.com

[info@SonoPath.com](mailto:info@SonoPath.com)