



PATIENT

Tucker VanSchepen

SPECIES

Canine

BREED

Mix

SEX

Neutered male

AGE

5 years

WEIGHT

49 lbs

INTERPRETED BY

Eric Lindquist, DMV
DABVP, Cert. IVUSS

IMAGING PERFORMED BY

Dr. Ammeraal

HOSPITAL NAME

Sova

REFERRING VET

Dr. Ammeraal

INVOICE

42853

DATE

12/5/22

PRESENTING CLINICAL SIGNS

History: New Patient - HAs a hx of 3 UTI's this past year . Treated w Primor at prior vet
Normal Exam, U/A Pending

ULTRASONOGRAPHIC EXAMINATION OF THE ABDOMEN

Urinary System

The **urinary bladder** revealed a minor amount of sand accumulation and apical ventral polypoid changes. The capical ventral wall changes measured approximately 3.4 cm. The prostate and pelvic urethra were unremarkable. The prostate measured 1.0 cm. The pelvic urethra was imaged 3.0 cm beyond the cystourethral junction.

The **kidneys** revealed normal size and structure, corticomedullary definition and ratio for this age. The cortices presented largely uniform texture with normal echogenic relationship to liver and spleen. Medullary structure differed distinctly from the cortex and no evidence of pelvic dilation was present. The capsules were acceptably uniform without significant irregularities. The right kidney measured 5.82 cm. The left kidney measured 6.43 cm.

ULTRASONOGRAPHIC FINDINGS

Bladder sand accumulation.

Apical ventral polypoid changes.

INTERPRETATION OF THE FINDINGS & FURTHER RECOMMENDATIONS

This appears resectable with removal of the cranial third of the urinary bladder. Bladder lavage, normal and retrograde flush and apical partial cystectomy is indicated. There is a minor potential for bladder carcinoma in this patient; however, it is unlikely. The apical thickening is likely serving as a chronic nidus of infection. Culture of the resected bladder wall would be appropriate as well as histopathology.



PATIENT

Tucker VanSchepen

SPECIES

Canine

BREED

Mix

SEX

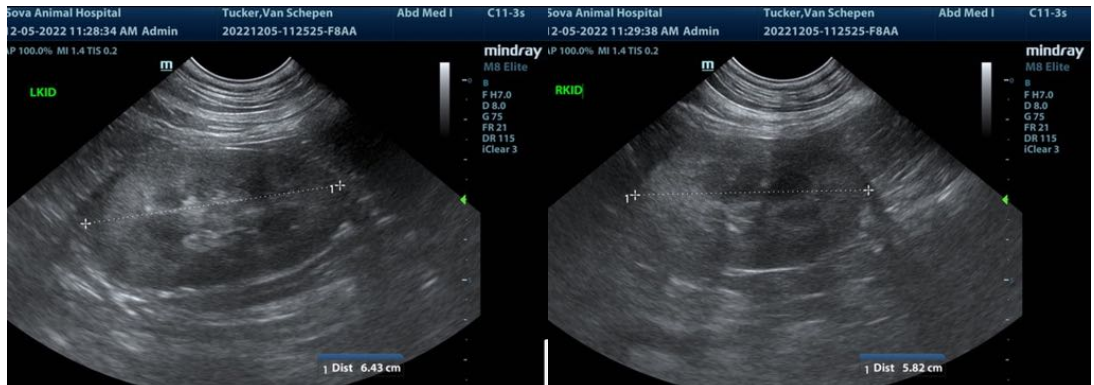
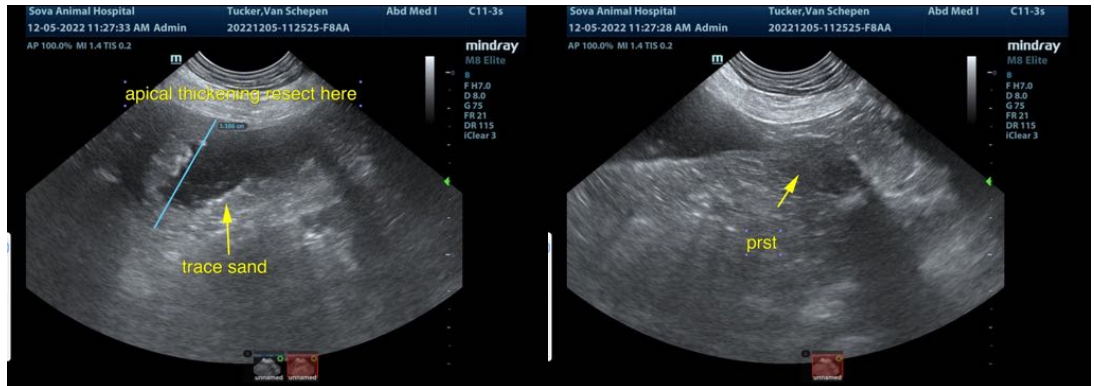
Neutered male

AGE

5 years

WEIGHT

49 lbs



INTERPRETED BY

Eric Lindquist, DMV
DABVP, Cert. IVUSS

IMAGING PERFORMED BY

Dr. Ammeraal

HOSPITAL NAME

Sova

REFERRING VET

Dr. Ammeraal

INVOICE

42853

DATE

12/5/22

The information and recommendations provided are based on the images presented by the referring veterinarian/sonographer. No evaluation can be communicated regarding pathology that was not visible in the image/video clips provided.

Thank you for this referral. If the clinical or image interpretation does not parallel your findings or if I can be of any further assistance please contact me.

Eric Lindquist, DMV, DABVP, Cert. IVUSS, CEO of SonoPath.com
info@SonoPath.com