

PATIENT

Teddy Bird

SPECIES

Canine

BREED

Lab

SEX

Neutered Male

AGE

1

WEIGHT

65

INTERPRETED BY

Eric Lindquist, DMV
DABVP, Cert. IVUSS

IMAGING PERFORMED BY

Jenn

HOSPITAL NAME

Rockaway AH

REFERRING VET

Dr. Maniar

INVOICE

18990

DATE

12/5/22

PRESENTING CLINICAL SIGNS

History: re check prev u/s on 12/3 showed moderate non shadowing gastric ingesta with intermittent to several non specific circular hypoechoic luminal echoes, hes doing well in the hosp

LIMITED ULTRASONOGRAPHIC EXAMINATION OF THE GASTROINTESTINAL TRACT

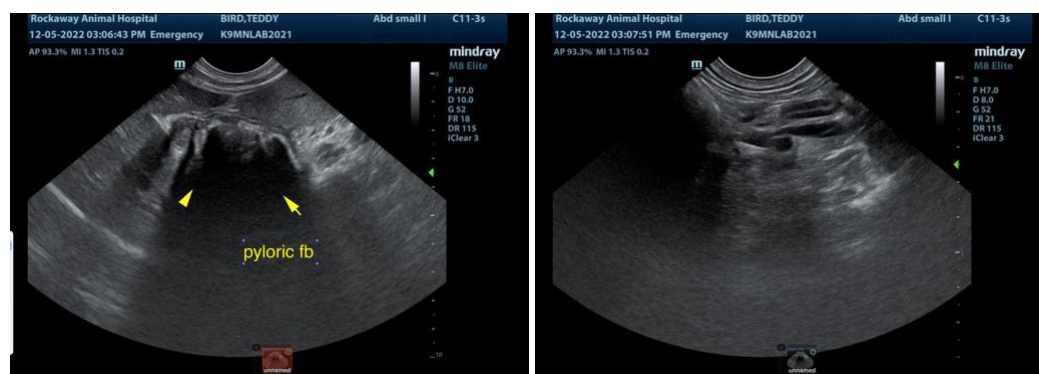
The stomach in this patient revealed persistent shadowing material in the pyloric outflow, presuming this patient was NPO at the time of the sonogram. The structure measured approximately 3-4 cm. This is consistent with plastic wrapping or similar. The small intestine and colon were unremarkable.

ULTRASONOGRAPHIC FINDINGS

- Persistent gastric foreign matter

INTERPRETATION OF THE FINDINGS & FURTHER RECOMMENDATIONS

Surgical intervention or endoscopy is indicated, assuming the patient was NPO at the time of the sonogram.



The information and recommendations provided are based on the images presented by the referring veterinarian. No evaluation can be communicated regarding pathology that was not visible in the image/video clips provided.

Thank you for this referral. If the clinical or image interpretation does not parallel your findings or if I can be of any further assistance please contact me.

Eric Lindquist, DMV, DABVP, Cert. IVUSS, CEO of SonoPath.com
info@SonoPath.com