



PATIENT

Max Rayos

PRESENTING CLINICAL SIGNS

History: elevated ALP on pre-op bloodwork. Enlarged liver on x-ray
Abnormal PE/Chem/CBC/UA Results: ALP 1837 PT/PTT- normal

SPECIES

Canine

ULTRASONOGRAPHIC EXAMINATION OF THE ABDOMEN

Urinary System

The **urinary bladder**, trigone, and pelvic urethra presented normal thicknesses and normal tone. The ureters were not visible which is normal. No uroliths or sediment were visualized and anechoic urine was present. No evidence of inflammatory or neoplastic changes was noted. Ureteral papillae were normal.

BREED

Dachshund

SEX

Neutered male

The **kidneys** revealed largely normal size and structure, corticomedullary definition and ratio (cortex 1/3 of medulla) were essentially maintained with some age-related loss of curvilinear patterns regarding the capsule and C/M junction. The cortices presented largely uniform texture with some increased echogenicity expected for his age patient. Medullary structure differed distinctly from that of the cortex and no evidence of pelvic dilation was present. Occasional cortical cyst was noted in the kidneys.

AGE

9 years

WEIGHT

15.6 kg

Adrenal Glands

Both **adrenal glands** were visualized and recognized as having normal shape, size, position and echogenicity for this breed. The phrenic vasculature, glandular echogenicity and detail were unremarkable. Capsule, cortex, and medullary definition were normal for this age patient. The left adrenal gland measured 0.6 cm. The right adrenal gland measured 0.5 cm.

INTERPRETED BY

Eric Lindquist, DMV
DABVP, Cert. IVUSS

Spleen

The **spleen** revealed subtle, micronodular changes.

IMAGING PERFORMED BY

Dallas Reynolds LVT

HOSPITAL NAME

Lone Mountain AH

Liver

Exam of the cranial abdomen demonstrated excessive **liver** size and swollen contour. Mild, coarse architecture was noted with increased portal markings and minor parenchymal remodeling is suggestive of an inflammatory component. Occasional, hypoechoic nodule was noted and was non-disruptive. Minor excessive GB debris was noted with the presence gallbladder dilation and precipitate without the overt formation of mucocele but this may be an issue in the future. This type of liver presentation typically is associated with slow and gradual SAP elevations with low-grade ALT rise. USG-FNA sampling is encouraged if more aggressive LE profiles are present such as ALT > 200 or rapid rise in SAP. These presentations are usually reactive hepatopathies owing to other disease processes either endocrine (Diabetes, Hypothyroidism, Cushing's disease), "antigen surveillance" from the gut/pancreas, or idiopathic breed predisposed progressions.

REFERRING VET

Dr. Parker

INVOICE

42849

DATE

12/5/22



PATIENT

Gastrointestinal

Max Rayos

Examination of the **gastrointestinal tract** revealed a stomach and intestine free of stasis, of normal wall thickness, acceptable curvilinear mural detail, and peristaltic activity. Small and large intestine demonstrated normal luminal chyme and stool consistency respectively. No obstructive or overt infiltrative disease was noted. No associated abnormal lymphatic activity was noted.

SPECIES

Canine

BREED

Dachshund

Pancreas

The base and limbs of the **pancreas** were observed to be largely isoechoic to surrounding omental fat. Pancreatic duct and capsular contour were acceptably normal and parenchyma respected normal curvilinear patterns. No overt evidence of active inflammatory or neoplastic disease was noted.

SEX

Neutered male

ULTRASONOGRAPHIC FINDINGS

AGE

9 years

Hepatic remodeling, history of inflammatory hepatopathy with nodular hyperplasia pattern. Minor potential for underlying neoplasia.

Subtle, heterogenous splenic changes.

Age related renal changes with occasional cyst.

Otherwise, unremarkable abdomen.

WEIGHT

15.6 kg

INTERPRETATION OF THE FINDINGS & FURTHER RECOMMENDATIONS

If any weight loss is an issue then FNA of the spleen and liver is indicated.

INTERPRETED BY

Eric Lindquist, DMV
DABVP, Cert. IVUSS

IMAGING PERFORMED BY

Dallas Reynolds LVT

HOSPITAL NAME

Lone Mountain AH

REFERRING VET

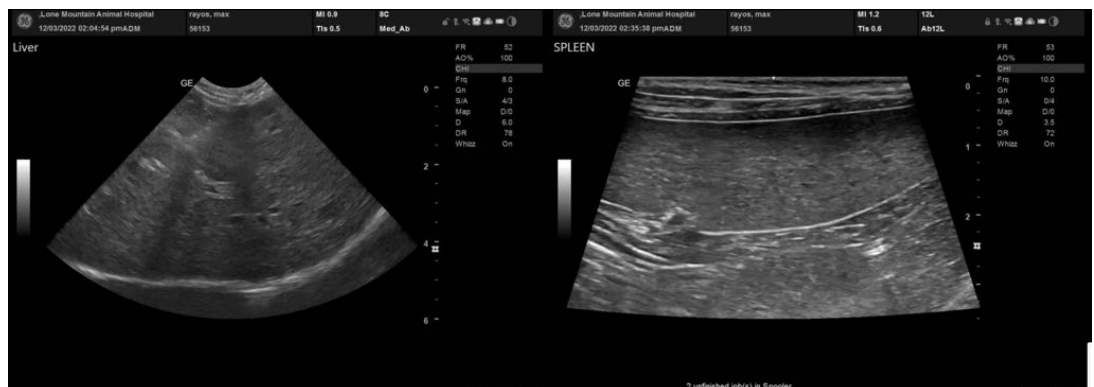Dr. Parker

INVOICE

42849

DATE

12/5/22





PATIENT

Max Rayos

SPECIES

Canine

BREED

Dachshund

SEX

Neutered male

AGE

9 years

WEIGHT

15.6 kg

INTERPRETED BY

Eric Lindquist, DMV
DABVP, Cert. IVUSS

IMAGING PERFORMED BY

Dallas Reynolds LVT

HOSPITAL NAME

Lone Mountain AH

REFERRING VET

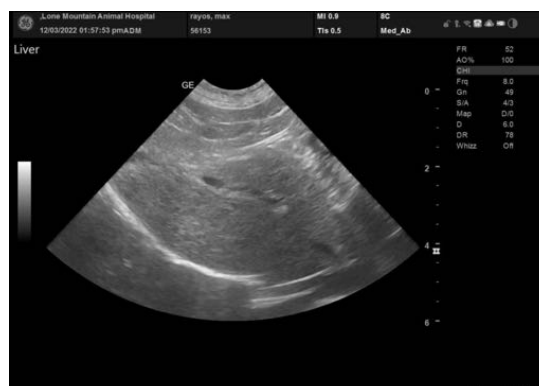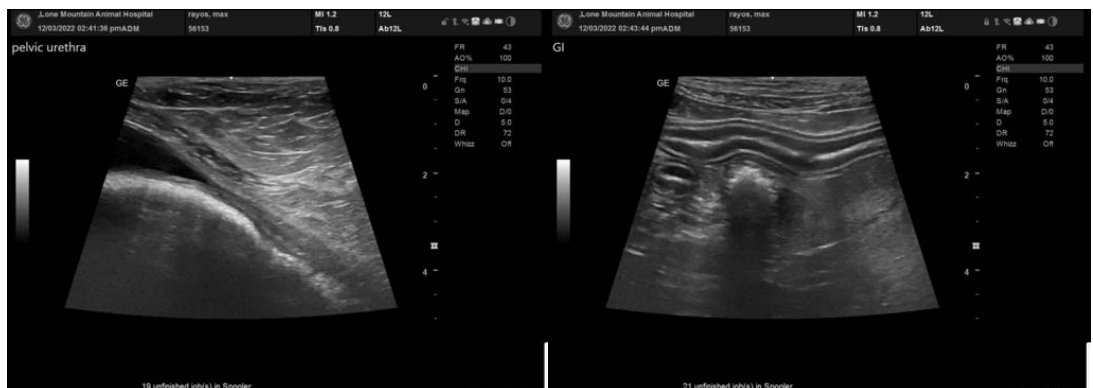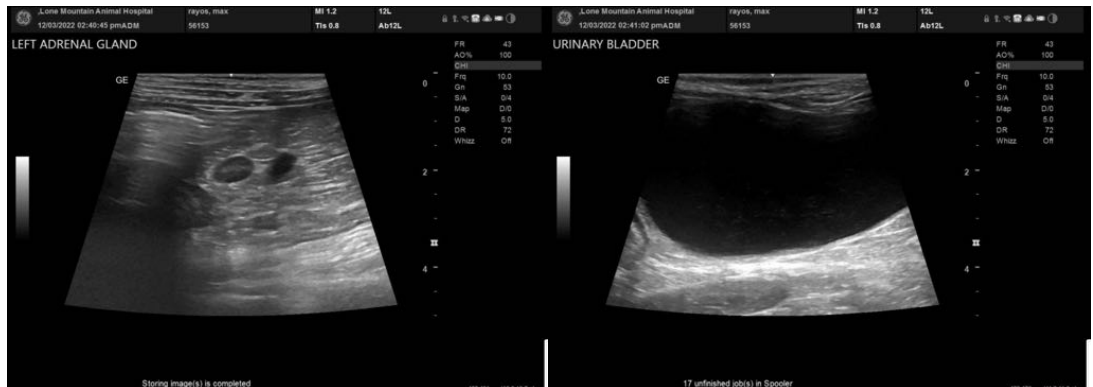
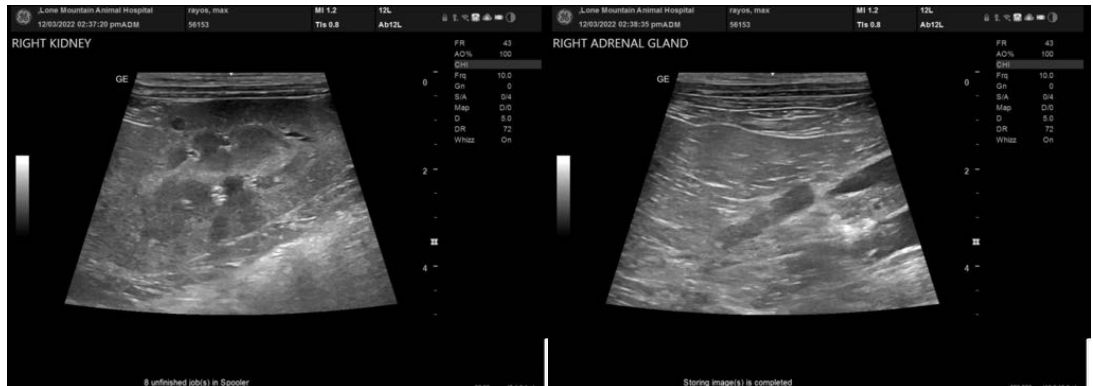Dr. Parker

INVOICE

42849

DATE

12/5/22





PATIENT

Max Rayos

SPECIES

Canine

BREED

Dachshund

SEX

Neutered male

AGE

9 years

WEIGHT

15.6 kg

INTERPRETED BY

Eric Lindquist, DMV
DABVP, Cert. IVUSS

**IMAGING
PERFORMED BY**

Dallas Reynolds LVT

HOSPITAL NAME

Lone Mountain AH

REFERRING VET

Dr. Parker

INVOICE

42849

DATE

12/5/22

The information and recommendations provided are based on the images presented by the referring veterinarian/sonographer. No evaluation can be communicated regarding pathology that was not visible in the image/video clips provided.

Thank you for this referral. If the clinical or image interpretation does not parallel your findings or if I can be of any further assistance please contact me.

Eric Lindquist, DMV, DABVP, Cert. IVUSS, CEO of SonoPath.com
info@SonoPath.com