



PATIENT

Lucy Barger

SPECIES

Canine

BREED

Beagle

SEX

Spayed female

AGE

9 years

WEIGHT

27 lbs

INTERPRETED BY

Eric Lindquist, DMV
DABVP, Cert. IVUSS

IMAGING PERFORMED BY

Brian Klug

HOSPITAL NAME

Sondel Family VC

REFERRING VET

Dr. Wallisch

INVOICE

42859

DATE

12/5/22

PRESENTING CLINICAL SIGNS

History: Recheck of spleen from full AUS on 10/31/22- monitoring for growth of splenic nodules to determine if splenectomy is necessary at this time

Abnormal PE/Chem/CBC/UA Results: No further diagnostics done since last AUS

ULTRASONOGRAPHIC EXAMINATION OF THE ABDOMEN

Spleen

The **spleen** revealed multi-focal, hypoechoic nodular changes up to 0.5 cm. This is similar to the prior sonogram. There was no progression noted.

Liver

Only a portion of the **liver** was visible in this image set and appeared unremarkable.

Gastrointestinal

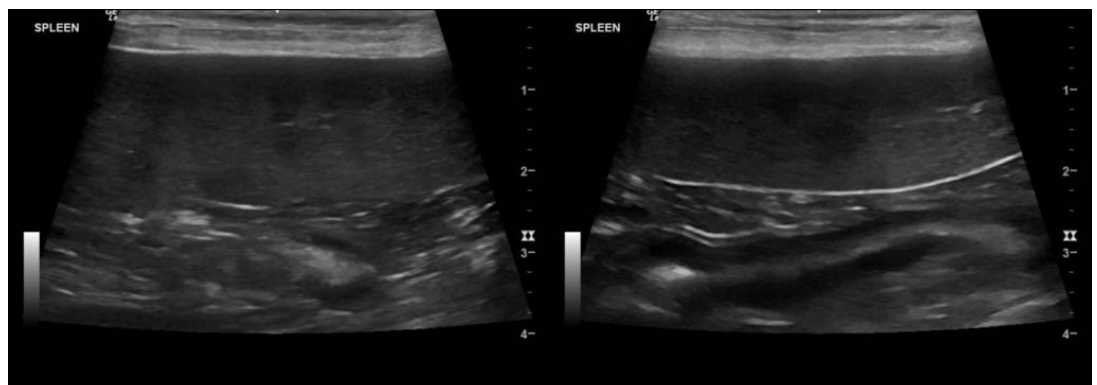
There was some residual chyme and gas was noted in the **stomach**, yet not pathological. This is consistent with end post prandial presentation. Transit of chyme into the small intestine was normal. Curvilinear patterns were maintained throughout the GI tract. No evidence of pathology. Small and large intestine demonstrated normal luminal chyme and stool consistency respectively. No obstructive or overt infiltrative disease was noted. No associated abnormal lymphatic activity was noted.

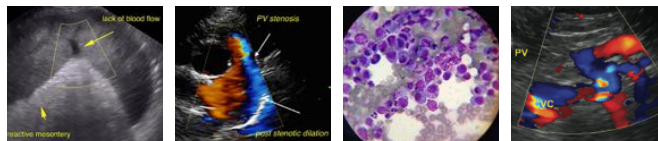
ULTRASONOGRAPHIC FINDINGS

Multi-focal, hypoechoic nodular changes in the spleen.

INTERPRETATION OF THE FINDINGS & FURTHER RECOMMENDATIONS

FNA is indicated to confirm suspicion of hyperplasia and to confirm that underlying round cell neoplasia is not an issue.





PATIENT

Lucy Barger

SPECIES

Canine

BREED

Beagle

SEX

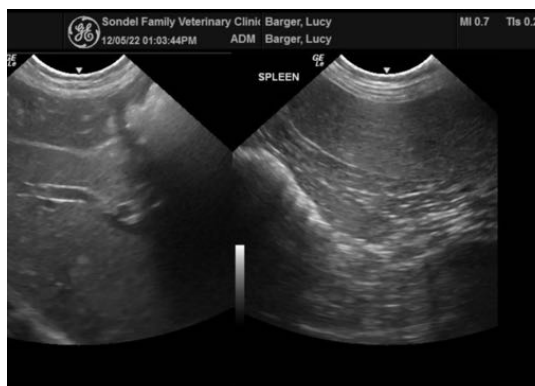
Spayed female

AGE

9 years

WEIGHT

27 lbs



The information and recommendations provided are based on the images presented by the referring veterinarian/sonographer. No evaluation can be communicated regarding pathology that was not visible in the image/video clips provided.

Thank you for this referral. If the clinical or image interpretation does not parallel your findings or if I can be of any further assistance please contact me.

Eric Lindquist, DMV, DABVP, Cert. IVUSS, CEO of SonoPath.com
info@SonoPath.com

INTERPRETED BY

Eric Lindquist, DMV
DABVP, Cert. IVUSS

**IMAGING
PERFORMED BY**

Brian Klug

HOSPITAL NAME

Sondel Family VC

REFERRING VET

Dr. Wallisch

INVOICE

42859

DATE

12/5/22