



PATIENT

Penny Jesensky

SPECIES

Feline

BREED

DSH

SEX

Spayed Female

AGE

17 Years

WEIGHT

7 pounds

INTERPRETED BY

Eric Lindquist, DMV,
DABVP(CFM), Cert.
IVUSS

IMAGING PERFORMED BY

Meghan Morse, LVT,
CVT

HOSPITAL NAME

Orchard Grove Animal
Hospital

REFERRING VET

Dr. Ludmerer

INVOICE

12560

DATE

12/04/25

PRESENTING CLINICAL SIGNS

Intermittent V+, weight loss, no diarrhea, Cerenia helps

Current meds: Cerenia

Abnormal PE/Chem/CBC/UA Results: CBC/CHEM/spec FPL- all WNL, TT4 2.9

ULTRASONOGRAPHIC EXAMINATION OF THE ABDOMEN

Urinary System

The **urinary bladder**, trigone, and pelvic urethra (to a depth of 2.0 cm) presented normal thicknesses and normal tone. The ureters were not visible which is normal. No uroliths or sediment were visualized, and anechoic urine was present. No evidence of inflammatory or neoplastic changes were noted. Ureteral papillae were normal.

The **kidneys** revealed largely normal size and structure, corticomedullary definition and ratio (cortex 1/3 of medulla) were essentially maintained with some mild to moderate age-related loss of curvilinear patterns regarding the capsule and C/M junction. The cortices presented largely uniform texture with some increased echogenicity expected for his age patient. Medullary structure differed distinctly from that of the cortex. Slight pinpoint mineralizations were noted. The left kidney measured 2.8 cm in length. The right kidney measured 2.8 cm in length.

Adrenal Glands

Both **adrenal glands** were visualized and recognized as having normal shape, size, position and echogenicity for this breed. The phrenic vasculature, glandular echogenicity and detail were unremarkable. Capsule, cortex, and medullary definition were normal for this age patient. The left adrenal gland measured 0.25 cm width. The right adrenal gland measured 0.42 cm width.

Spleen

The **spleen** presented a smooth homogeneous parenchyma hyperechoic to liver and renal cortical parenchyma. The capsule was smooth without noticeable expansion or deviation from within the spleen or adjacent pathology. The splenic vasculature demonstrated normal volume without signs of congestion or thrombosis. No sonographic evidence of acute or chronic inflammatory, neoplastic, or infarctual changes were noted.

Liver

The **liver** images from right and left intercostal as well as subcostal views revealed subjectively normal liver size, contour, and structure. Some mild age-related parenchymal remodeling was noted but likely not clinically significant at this time. Vascular and biliary tracts were of normal volume, and no evidence of congestion was noted. The gallbladder presented some dependent debris with essentially normal contour. The cystic and common bile ducts were normal. No overt evidence of active inflammatory, infiltrative or regenerative pathology was noted but should be paired with current or past LE elevations regarding any clinical significance to this presentation.

Gastrointestinal

Examination of the **gastrointestinal tract** revealed a stomach and intestine free of stasis, of normal wall thickness, acceptable curvilinear mural detail, and peristaltic activity. Small and large intestine



PATIENT

Penny Jesensky

SPECIES

Feline

BREED

DSH

SEX

Spayed Female

AGE

17 Years

WEIGHT

7 pounds

INTERPRETED BY

Eric Lindquist, DMV,
DABVP(CFM), Cert.
IUUSS

IMAGING PERFORMED BY

Meghan Morse, LVT,
CVT

HOSPITAL NAME

Orchard Grove Animal
Hospital

REFERRING VET

Dr. Ludmerer

INVOICE

12560

DATE

12/04/25

demonstrated normal luminal chyme and stool consistency respectively. No obstructive or overt infiltrative disease was noted. No associated abnormal lymphatic activity was noted.

Pancreas

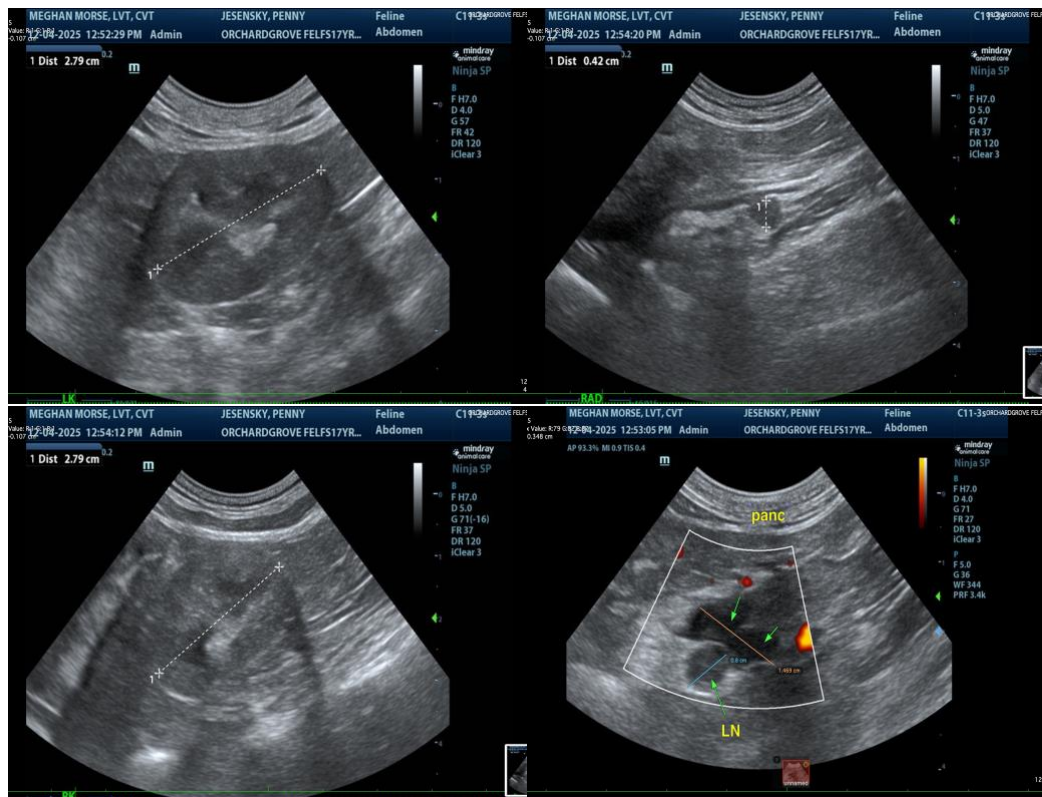
The right base of the **pancreas** revealed a mixed hypoechoic cyst and nodular changes with an adjacent rounded hypoechoic lymph node. The cystic and nodular changes measured approximately 1.5 cm. The lymph node is likely a hepatic lymph node. Subjectively, the pancreatic lesions appear to be benign. Some echogenic remodeling was noted in the remainder of the pancreas.

ULTRASONOGRAPHIC FINDINGS

- Age-related renal changes with pinpoint mineralizations.
- Pancreatic cyst or nodules, possible abscessation.
- Regional lymphadenopathy.

INTERPRETATION OF THE FINDINGS & FURTHER RECOMMENDATIONS

Under full sedation, ultrasound guided drainage and aspiration of the cystic/nodular structures could be considered. No overt evidence of neoplasia, however, cannot completely rule out potential neoplastic event in the pancreas such as carcinoma yet is not suspected. Malassimilation or neoplasia elsewhere in the body is a possibility. Maldigestion panel, three view chest radiographs and full CNS examination is recommended to examine for occult disease that could be responsible for the weight loss. Evaluation for competitive eating environments should also be considered. Largely geriatric abdomen other than the pancreatic presentation.





PATIENT

Penny Jesensky

SPECIES

Feline

BREED

DSH

SEX

Spayed Female

AGE

17 Years

WEIGHT

7 pounds

INTERPRETED BY

Eric Lindquist, DMV,
DABVP(CFM), Cert.
IVUSS

**IMAGING
PERFORMED BY**

Meghan Morse, LVT,
CVT

HOSPITAL NAME

Orchard Grove Animal
Hospital

REFERRING VET

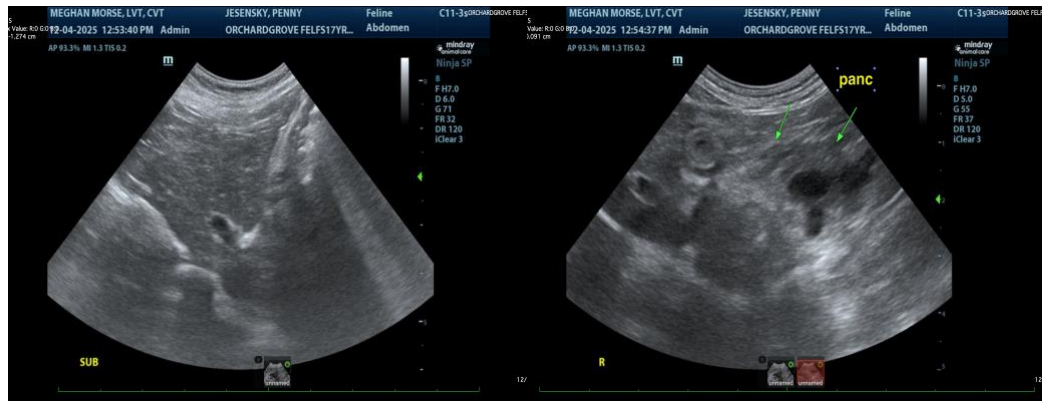
Dr. Ludmerer

INVOICE

12560

DATE

12/04/25



The information and recommendations provided are based on the images presented by the referring veterinarian/sonographer. No evaluation can be communicated regarding pathology that was not visible in the image/video clips provided.

Thank you for this referral. If the clinical or image interpretation does not parallel your findings or if I can be of any further assistance, please contact me.

Eric Lindquist, DMV, DABVP(CFM), Cert. IVUSS,

CEO, Owner, Founder -- SonoPath.com

info@SonoPath.com