



DATE PRESENTING CLINICAL SIGNS

12/4/25

Patient History: P presented for an approximately 4 day history of sneezing, yellow nasal discharge and clear ocular discharge. Otherwise, P acting normally at home. On examination, nasal and ocular discharge was confirmed. Also, P was icteric and dehydrated. Bloodwork revealed inflammatory changes and primary liver and cholestatic enzyme elevations.

PATIENT

Martha Kulbicki

SPECIES

Feline

BREED

DSH

SEX

Spayed Female

AGE

10/30/12

WEIGHT

3.41 kg

INTERPRETED BY

Kathleen Sennello DVM,
MS, Diplomate ACVIM
(Small Animal Internal
Medicine)

HOSPITAL NAME

Eastern Animal
Hospital

REFERRING VET

Dr. Aparicio-Massanett

INVOICE

72346

Current Medications: While P hospitalized starting on: Cerenia 1mg/kg IV SID, Denamarin Advanced for Cats/Small Dogs- one tablet PO SID, Amoxi/Clav Liquid 62.5mg/mL 15mL- 0.6mL PO BID

Labwork Results: Labwork not attached, reported as Bloodwork revealed inflammatory changes (neutrophilia, monocytosis, thrombocytosis) and primary liver and cholestatic enzyme elevations (ALT, ALP, GGT, Tbili).

Date of Previous IntraPet Ultrasound: No previous.

Sedation: Not required to complete full diagnostic ultrasound.

Stat Report: Not requested.

Imaging Performed by: Rachel Brillhart, RDMS.

ULTRASONOGRAPHIC EXAMINATION OF THE ABDOMEN

Urinary System

The urinary bladder is moderately distended with anechoic urine. The Bladder wall, trigone, ureteral papillae and visible urethra (to a depth of 2cm) appear normal with no evidence of wall thickening, mucosal irregularities, masses or cystic calculi.

The left kidney has a normal shape and size (4.06 cm) with pyelectasia at 0.17 cm. Overall echogenicity is slightly hyperechoic with mildly reduced corticomedullary distinction and a typical 1:3 cortex:medulla ratio. There is no evidence of focal perinephric inflammation or effusion. There is no evidence of pyelectasia, nephroliths, infarcts or hydroureter. Renal vasculature is normal.

The right kidney has a normal shape and size (4.11 cm) with pyelectasia at 0.35 cm. Overall echogenicity is slightly hyperechoic with mildly reduced corticomedullary distinction and a typical 1:3 cortex:medulla ratio. There is no evidence of focal perinephric inflammation or effusion. There is no evidence of pyelectasia, nephroliths, infarcts or hydroureter. Renal vasculature is normal.

Adrenal Glands

The left adrenal gland is normal in size measuring 0.49 cm at the caudal pole. It is observed in its normal position cranial to the left renal artery. It is normal in appearance (uniformly hypoechoic) and shape with no evidence of a mass effect.

The right adrenal gland is normal in size measuring 0.47 cm at the caudal pole. It is observed in its normal position between the cranial aspect of the right kidney and the caudal vena cava. It is normal in appearance (uniformly hypoechoic) and shape with no evidence of a mass effect.

Spleen

The spleen is subjectively normal in size (0.81 cm), echotexture is homogenous, and the splenic capsule is smooth with no irregularities. The blood flow through the hilus and splenic parenchyma appears normal. No focal parenchymal abnormalities are visualized.

Liver

The liver is large, rounded, and slightly hyperechoic. The vasculature is normal. The intrahepatic bile ducts appear dilated. There is a complex cystic mass lesion visualized in the right side of the liver measuring 2.7 cm x 2.81 cm.

The gallbladder has a large amount of debris and thickened, irregular wall measuring at 0.24 cm. The bile duct is thick, dilated and tortuous. The proximal cystic duct measures 0.35 cm. The mid common bile duct measures 0.49 cm. At the duodenal papilla the bile duct measures at 0.37 cm with no focal obstruction visualized (but cannot be ruled out). The duodenal papilla appears prominent but normal, measuring 0.49 cm x 0.32 cm.

Gastrointestinal

The stomach contains mild fluid/ingesta. It measures at a normal thickness of <0.36cm with some variability due to the presence of rugal folds. The distinction of the gastric wall layers is adequate and there is no impression of reduced peristaltic activity. No masses or focal lesions were observed.

The visualized areas of duodenum, jejunum and ileum have a uniform diameter with minimal to mild fluid distension. Wall thickness is increased. Bowel loops follow a typical curvilinear path. Some areas have reduced detail of wall layering. Duodenum wall measures 0.20 cm. Jejunum wall measures 0.24 cm. Visualized peristalsis appears appropriate. The muscularis is diffusely prominent throughout the jejunum, and there is significant thickening with some areas exhibiting reduced detail of wall layering.

The ileocecal junction was visualized and exhibited normal intact wall layering and is subjectively of normal thickness. Sections of colon are visualized with formed fecal material and gas shadowing distally. There is no observed focal or generalized colon wall thickening or loss of layering.

Pancreas

The pancreas is large and hypoechoic to surrounding mesentery. There is no evidence of nodules or cystic lesions. There is evidence of regional mesenteric inflammation. Consistent with mild/moderate pancreatitis. Prominent pancreatic duct noted measuring 0.28 cm.

Free Abdomen

Evaluation of the peritoneal cavity did not reveal any evidence of effusion. No significant lymphadenopathy noted. The omentum is diffusely hyperechoic.

Other

There is an irregular, hypoechoic, sometimes somewhat mottled/cystic appearing lesion visualized in the ventral mid caudal abdomen. This is poorly vascular, measuring 3.0 cm x 1.17 cm.

ULTRASONOGRAPHIC FINDINGS

- Age related changes and mild pyelectasia visualized associated with both kidneys.
- Pancreatic changes consistent with chronic active pancreatitis.
- Large, mildly hyperechoic liver with a complex cystic mass lesion – Hepatic changes are non-specific and could be consistent with hepatic lipidosis, inflammatory/infectious disease, infiltrative neoplasia, or other hepatopathy. The mass lesion has the appearance most consistent with a cystadenoma, cystadenocarcinoma.

- Large, distended gallbladder with a large amount of disorganized debris, wall thickening, and a severely thickened, dilated/tortuous bile duct – Findings are suggestive of severe cholecystitis/cholangiohepatitis. An underlying neoplastic process cannot be ruled out.
- Diffuse thickening of the small intestine with a prominent muscularis layer and reduced detail of wall layering – Findings are most suggestive of severe inflammatory or early neoplastic process.
- Irregular, poorly vascular, hypoechoic lesion in the mid ventral caudal abdomen – Findings could be consistent with poorly vascular tissue (mass, lymph node, etc.), echogenic fluid, a hematoma secondary to cystocentesis, etc.

INTERPRETATION OF THE FINDINGS & FURTHER RECOMMENDATIONS

The liver is large and hyperechoic with a complex cystic lesion. This likely represents a cystadenoma or cystadenocarcinoma and is likely unrelated to the current liver issues. When the patient is feeling better this could be aspirated or further evaluated for surgical removal.

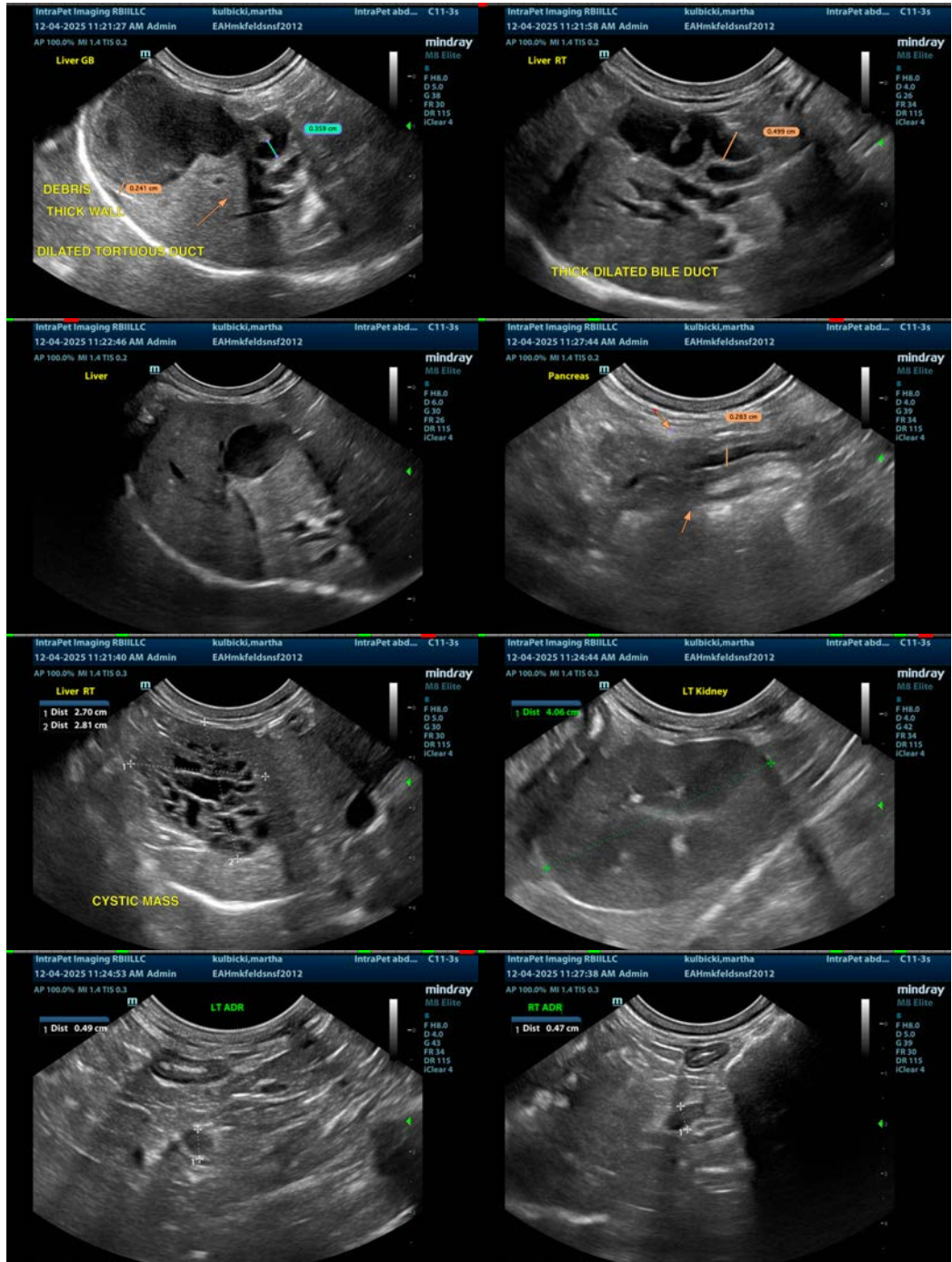
The gallbladder is severely enlarged with a large amount of intraluminal debris, and the bile duct is thickened, dilated and tortuous. No evidence of a definitive obstruction is visualized, but this cannot be ruled out. Recommend treatment for cholangiohepatitis with Ursodiol, Denamarin and antibiotics with supportive care (fluids, nausea meds, etc.). If the patient is not responding to this therapy, a contrast CT scan should be considered, looking for a focal obstruction. While treatment is being implemented, recommend a fine needle aspirate of the liver and the abnormal hypoechoic lesion in the ventral abdomen (unless a hematoma secondary to cystocentesis is suspected).

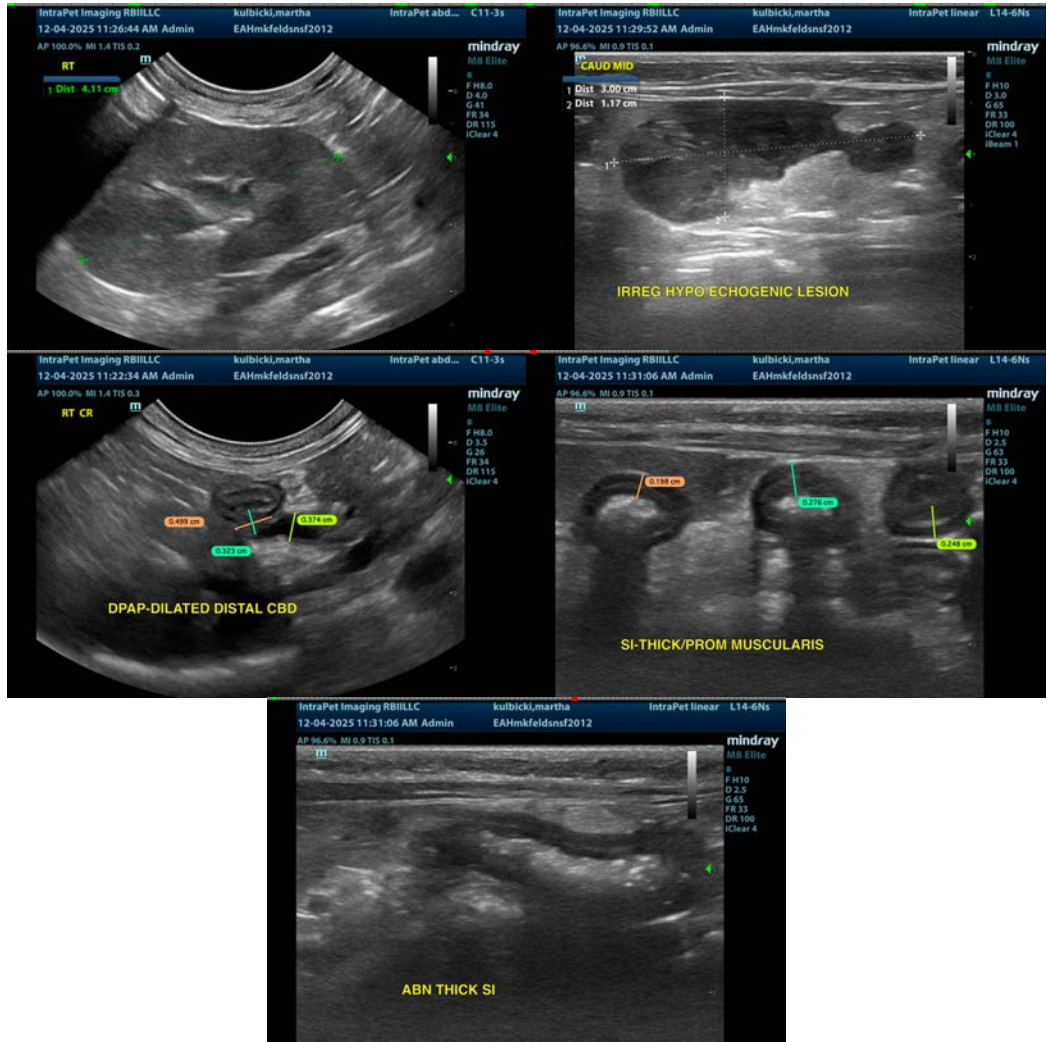
The pancreas has changes consistent with chronic pancreatitis. Recommend concurrent treatment for pancreatitis. The small intestine appears severely thickened with reduced detail of wall layering and a severely thickened muscularis layer. The multicentric nature of these lesions is concerning for possible infiltrative neoplasia or Triaditis. If sampling of the liver is not helpful and the patient is not responding to therapy, surgical biopsies of the GI tract, liver, pancreas, etc. may eventually be warranted.

Additionally, you could consider a hydrolyzed protein prescription diet, a GI panel to Texas A&M for a qualitative PLI, TLI, cobalamin and folate. Recommend three view thoracic radiographs to evaluate for possible concurrent thoracic disease/involvement (disregard if this has already been done).

Recommend three view thoracic radiographs to evaluate for possible concurrent thoracic disease/involvement (disregard if this has already been done).

If the patient is responding to therapy, consider repeat imaging in the future to follow the progression of this disease process and to help guide medical therapy.





The information and recommendations provided are based on the images presented by the referring veterinarian/sonographer. No evaluation can be communicated regarding pathology that was not visible in the image/video clips provided.

Thank you for this referral. If the clinical or image interpretation does not parallel your findings or if I can be of any further assistance please contact me.

Kathleen Sennello DVM,MS, Diplomate ACVIM (Small animal Internal Medicine)
info@sonopath.com