



PATIENT

Athena Mieczkowski

SPECIES

Canine

BREED

Pitbull

SEX

Spayed Female

AGE

7 years

WEIGHT

109 Lbs.

INTERPRETED BY

Eric Lindquist, DMV
DABVP, Cert. IVUSS

IMAGING PERFORMED BY

Kayla Hanson

HOSPITAL NAME

Yorkville AH

REFERRING VET

Dr. Long

INVOICE

12838

DATE

12/4/21

PRESENTING CLINICAL SIGNS

History: P came in for annual BW

Abnormal PE/Chem/CBC/UA Results: Kidney and liver values increased. hypercalcemia. rec u/s for kidney, liver, adrenals.

ULTRASONOGRAPHIC EXAMINATION OF THE ABDOMEN

Urinary System

The **bladder** in this patient was mildly thickened with slight echogenic mural changes. A trace amount of sand was noted in the bladder, non-obstructive. Slight micropolypoid changes were noted. This is a frequent finding in older animals and may be linked to a history of chronic urinary tract infection or active urinary tract infection. Urinalysis would be recommended with culture if any evidence of inflammatory sediment is present. The region of the trigone and visible pelvic urethra were normal.

The **kidneys** revealed largely normal size and structure, corticomedullary definition and ratio (cortex 1/3 of medulla) were essentially maintained with some mild age-related loss of curvilinear patterns regarding the capsule and C/M junction. The cortices presented largely uniform texture with some increased echogenicity expected for his age patient. Medullary structure differed distinctly from that of the cortex and no evidence of pelvic dilation was present. The left kidney measured 6.23 cm. The right kidney measured 5.17 cm. Pinpoint mineralizations were noted in both kidneys.

Adrenal Glands

The **right adrenal gland** was isoechoic to surrounding fat. The right adrenal gland measured 0.5 cm at maximum width.

The left **adrenal gland** was not visualized.

Spleen

The **spleen** presented a smooth homogeneous parenchyma hyperechoic to liver and renal cortical parenchyma. The capsule was smooth without noticeable expansion or deviation from within the spleen or adjacent pathology. The splenic vasculature demonstrated normal volume without signs of congestion or thrombosis. No sonographic evidence of acute or chronic inflammatory, neoplastic, or infarctual changes were noted.

Liver

The **liver** presented heterogenous parenchyma with increased portal markings and coarse architecture. Slight undulating capsular contour was noted. The gallbladder and common bile duct were unremarkable. This is consistent with mild chronic inflammatory hepatopathy.

Gastrointestinal

The **stomach** revealed shadowing material in the pylorus, may be postprandial or possible soft foreign matter. No overt obstructive pattern noted. The small intestine and colon were unremarkable.

Pancreas



PATIENT

Athena Mieczkowski

The base and limbs of the **pancreas** were observed to be largely isoechoic to surrounding omental fat. Pancreatic duct and capsular contour were acceptably normal and parenchyma respected normal curvilinear patterns. No overt evidence of active inflammatory or neoplastic disease was noted.

SPECIES

Canine

Other

The **anal glands** were imaged. No evident pathology.

BREED

Pitbull

ULTRASONOGRAPHIC FINDINGS

SEX

Spayed Female

- Trace bladder sand. Mild cystitis pattern
- Mild degenerative renal changes with slight mineralization (non-obstructive)- The patient may be passing calculi periodically, which may be contributing to the renal enzyme elevations as the kidneys do not appear end stage.
- Concurrent non-specific chronic inflammatory hepatopathy- FNA could be considered for further investigation of inflammatory cell type
- Shadowing material in the pylorus

AGE

7 years

WEIGHT

109 Lbs.

INTERPRETATION OF THE FINDINGS & FURTHER RECOMMENDATIONS

Full urinary work up with culture and sensitivity warranted (if any inflammatory sediment is present) with dissolution diet based on urinalysis results. Given the hypercalcemia, other causes of hypercalcemia such as primary hyperparathyroidism, cranial mediastinal masses or lytic spinal lesions should be investigated. Given the azotemia and hypercalcemia, Addison's should be ruled out in this patient with baseline cortisol or ACTH stimulation.

INTERPRETED BY

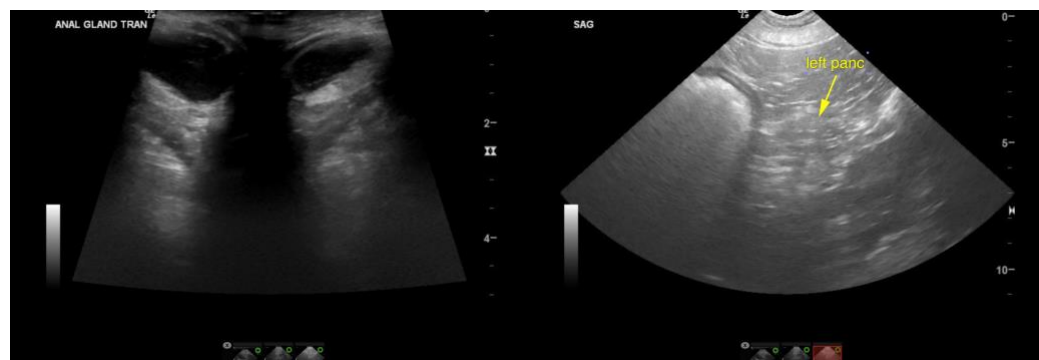
Eric Lindquist, DMV
DABVP, Cert. IVUSS

IMAGING PERFORMED BY

Kayla Hanson

HOSPITAL NAME

Yorkville AH



REFERRING VET

Dr. Long

INVOICE

12838

DATE

12/4/21



PATIENT

Athena Mieczkowski

SPECIES

Canine

BREED

Pitbull

SEX

Spayed Female

AGE

7 years

WEIGHT

109 Lbs.

INTERPRETED BY

Eric Lindquist, DMV
DABVP, Cert. IVUSS

IMAGING PERFORMED BY

Kayla Hanson

HOSPITAL NAME

Yorkville AH

REFERRING VET

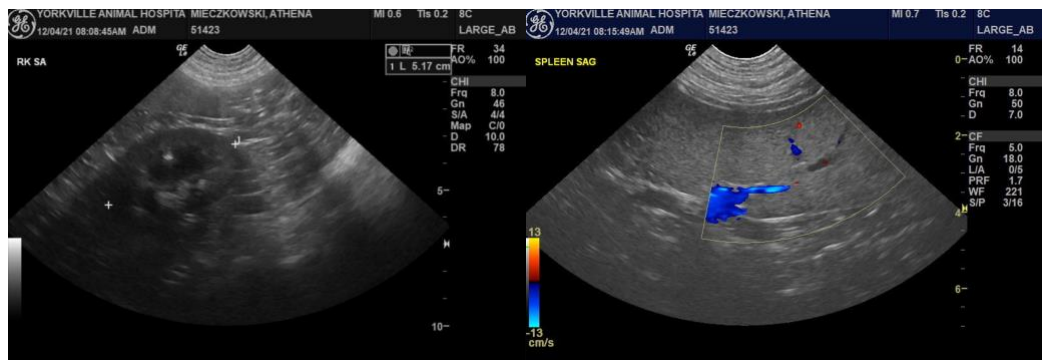
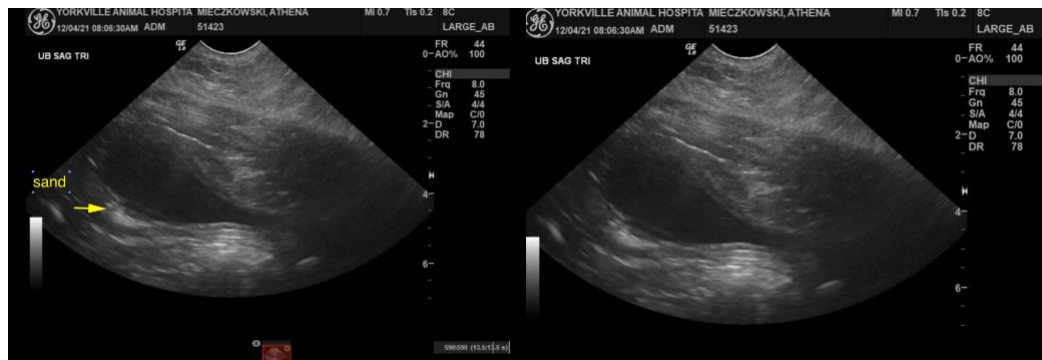
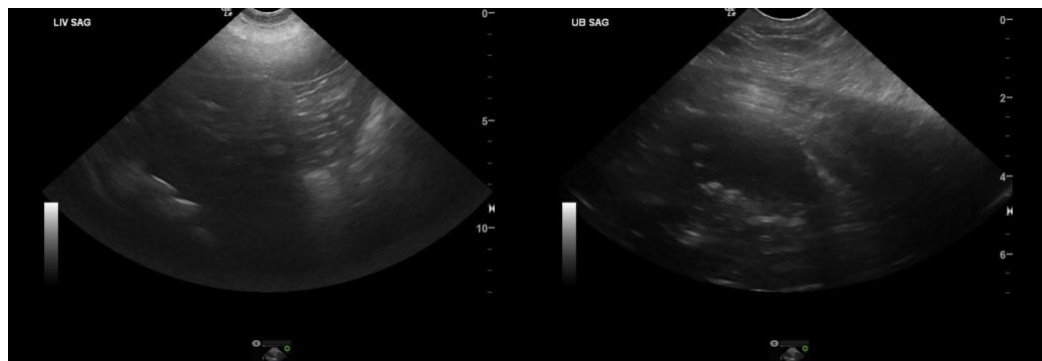
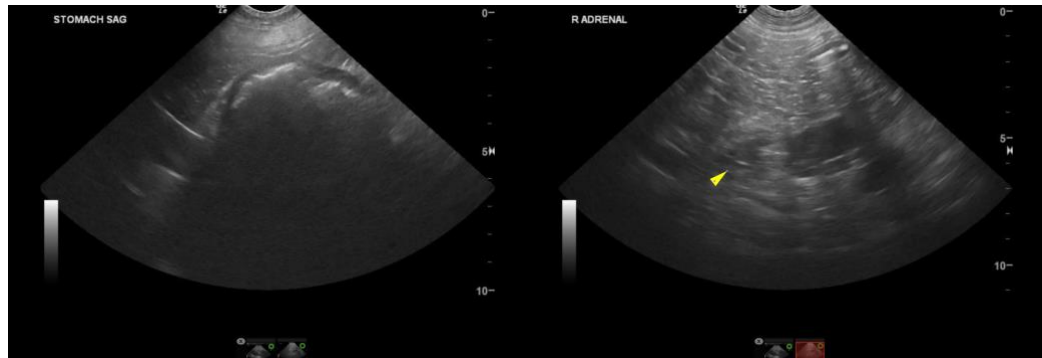
Dr. Long

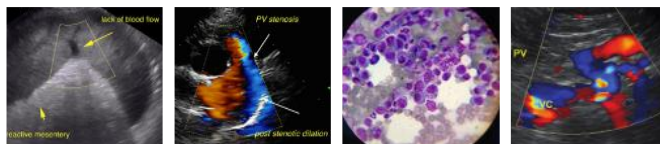
INVOICE

12838

DATE

12/4/21





PATIENT

Athena Mieczkowski

SPECIES

Canine

BREED

Pitbull

SEX

Spayed Female

AGE

7 years

WEIGHT

109 Lbs.

INTERPRETED BY

Eric Lindquist, DMV
DABVP, Cert. IVUSS

IMAGING PERFORMED BY

Kayla Hanson

HOSPITAL NAME

Yorkville AH

REFERRING VET

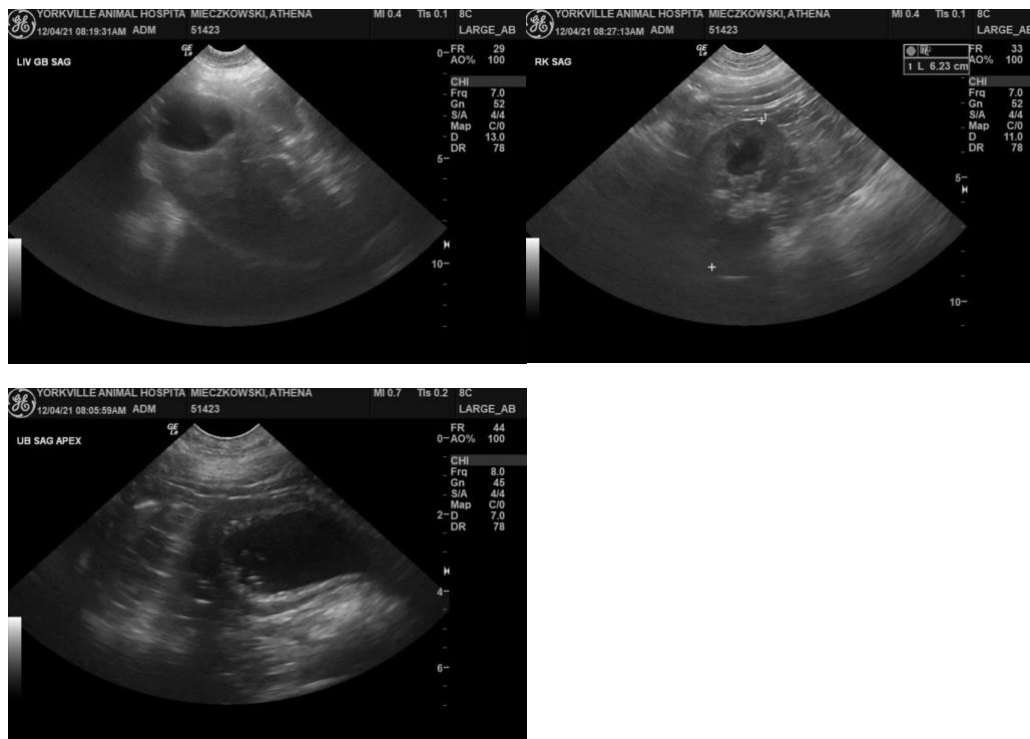
Dr. Long

INVOICE

12838

DATE

12/4/21



The information and recommendations provided are based on the images presented by the referring veterinarian. No evaluation can be communicated regarding pathology that was not visible in the image/video clips provided.

Thank you for this referral. If the clinical or image interpretation does not parallel your findings or if I can be of any further assistance please contact me.

Eric Lindquist, DMV, DABVP, Cert. IVUSS, CEO of SonoPath.com
info@SonoPath.com

CANINE HYPERCALCEMIA

<http://www.sonopath.com/CanineHypercalcemia>

Description: Hypercalcemia is defined as either a persistently elevated total calcium serum (> 12 mg/dl) or ionized calcium (> 1.45 mmol/l) concentration. Clinical signs are often absent with mild hypercalcemia (< 13 mg/dl). In fact, hypercalcemia is often only discovered when serum biochemistry is done for unrelated reasons. Clinical signs are usually mild when the serum calcium concentration is less than 14 mg/dl; however, signs become more readily apparent when the concentration exceeds 15 mg/dl. Life-threatening cardiac arrhythmias can develop when the serum calcium exceeds 18 mg/dl.



PATIENT

Athena Mieczkowski

Common etiologies of hypercalcemia include humoral hypercalcemia of malignancy (HHM), hypoadrenocorticism, chronic kidney disease (CKD), hypervitaminosis D, and primary hyperparathyroidism. Less common etiologies include bone neoplasia, osteomyelitis, hypertrophic osteodystrophy, granulomatous disease, calcium supplementation, and oral phosphate binders.

SPECIES

Canine

Clinical Signs: Common clinical signs include polyuria, polydipsia, lethargy, inappetence, and weakness. With chronic hypercalcemia, calcium oxalate and calcium phosphate uroliths can form, resulting in clinical signs suggestive of lower urinary tract disease. Systemic signs of illness are suggestive of HHM.

BREED

Pitbull

SEX

Spayed Female

Diagnostics: One important etiology of hypercalcemia is laboratory error; therefore, hypercalcemia should always be confirmed before embarking on any further diagnostic evaluation. Results of a CBC, serum biochemistry panel, and urinalysis, in conjunction with a patient history and findings from a physical examination, can often provide enough information to arrive at a diagnosis. The appendicular skeleton, peripheral lymph nodes, abdominal cavity, and rectum should all be carefully palpated for masses, lymphadenopathy, hepatomegaly, splenomegaly, and/or pain in the long bones. The following diagnostic tests are helpful for identifying an underlying malignancy: thoracic and abdominal radiographs; abdominal ultrasound; cytological evaluation of aspirates of the liver, spleen, lymph nodes, and bone marrow; determination of serum ionized calcium, parathyroid hormone (PTH), and parathyroid hormone-related protein concentration (PTHrP); and ultrasound of the neck. Ascertaining the concentrations of serum ionized calcium, PTH, and PTHrP helps differentiate primary hyperparathyroidism from HHM. The finding of one or more enlarged parathyroid glands upon conducting an ultrasound of the neck supports a diagnosis of primary hyperparathyroidism.

AGE

7 years

WEIGHT

109 Lbs.

INTERPRETED BY

Eric Lindquist, DMV
DABVP, Cert. IVUSS

Hypoadrenocorticism-induced hypercalcemia usually occurs in conjunction with hyponatremia, hyperkalemia, and prerenal azotemia. With HHM and primary hyperparathyroidism, serum phosphorus concentration is often in the low to low-normal reference range. If the serum phosphorus concentration is high but kidney function is normal, hypervitaminosis D or osteolysis should be suspected.

IMAGING PERFORMED BY

Kayla Hanson

HOSPITAL NAME

Yorkville AH

It can be difficult to determine whether kidney failure is primary or secondary to hypercalcemia when hyperphosphatemia and hypercalcemia coexist with azotemia. Serum ionized calcium concentrations are typically normal or decreased in cases of renal failure and increased in cases of hypercalcemia caused by other disorders.

REFERRING VET

Dr. Long

Sternal and hilar lymphadenopathy is common with lymphoma-induced hypercalcemia and can be readily identified on thoracic radiographs. In cases of multiple myeloma, discrete lytic lesions in the vertebrae or long bones, hyperproteinemia, proteinuria, and plasma cell infiltration in the bone marrow may be present. Cytological evaluation of the peripheral lymph nodes, bone marrow, and spleen can be helpful in identifying lymphoma.

INVOICE

12838

DATE

12/4/21



PATIENT

Athena Mieczkowski

Increased serum ionized calcium concentrations, detectable serum PTHrP concentrations, and non-detectable serum PTH concentrations are all diagnostic for HHM. Lymphoma is the most common etiology of HHM, but other tumors, such as apocrine gland adenocarcinoma and various carcinomas (e.g. mammary gland, squamous cell, bronchogenic), can all give rise to hypercalcemia. Increased serum ionized calcium, normal to increased serum PTH, and non-detectable PTHrP concentrations are diagnostic of primary hyperparathyroidism.

SPECIES

Canine

BREED

Pitbull

Differentials for Hypercalcemia: "HARD IONS"

SEX

Hyperparathyroid

Spayed Female

Addison's

Renal

AGE

7 years

D-toxicity

Idiopathic

WEIGHT

109 Lbs.

Osteolytic

Neoplastic

Spurious

INTERPRETED BY

Eric Lindquist, DMV
DABVP, Cert. IVUSS

PTH tumor: Elevated total and ionized Ca, low PTHrP, and normal/high PTH. Keeshonds, German Shepherds, and Golden Retrievers are all predisposed.

IMAGING PERFORMED BY

Kayla Hanson

Addison's disease: Elevated total and normal ionized Ca, elevated BUN, hypoalbuminemia and hyperkalemia.

HOSPITAL NAME

Yorkville AH

Renal failure: Elevated to normal total Ca, low ionized Ca, low PTHrP, elevated PTH, azotemia, and low urine specific gravity.

Vitamin D toxicity: Elevated total and ionized Ca, low PTHrP, and normal/low PTH.

REFERRING VET

Dr. Long

Hypercalcemia of malignancy (HHM): Elevated total and ionized Ca, high PTHrP, and low PTH.

Granulomatous disease: Elevated total and ionized Ca, low PTHrP, and low PTH.

Renal failure: Elevated to normal total Ca, low ionized Ca, low PTHrP, elevated PTH, azotemia, and low urine specific gravity.

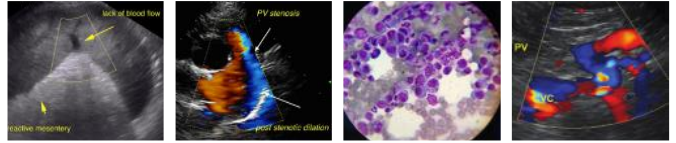
INVOICE

12838

Treatment: Therapies for hypercalcemia are aimed at correcting the underlying etiology; however, because prolonged hypercalcemia can result in kidney damage, the use of fluid therapy, furosemide, and possibly prednisone is indicated in all cases to reduce serum calcium levels. Suggested dosages include saline (0.9% 120-180 ml/kg day IV), furosemide (1-4 mg/kg PO TID), and prednisone (0.25 mg/kg PO Q24hr).

DATE

12/4/21



PATIENT

Athena Mieczkowski

SPECIES

Canine

BREED

Pitbull

SEX

Spayed Female

AGE

7 years

WEIGHT

109 Lbs.

INTERPRETED BY

Eric Lindquist, DMV
DABVP, Cert. IVUSS

**IMAGING
PERFORMED BY**

Kayla Hanson

HOSPITAL NAME

Yorkville AH

REFERRING VET

Dr. Long

INVOICE

12838

DATE

12/4/21

References:

Chew DJ, Schenck PA, Jaeger JQ. Clinical disorders of hypercalcemia and hypocalcemia in dogs and cats. Proceedings from the American College of Veterinary Internal Medicine, Charlotte, NC, June 4-7, 2003.

Feldman EC. Disorders of the parathyroid glands. In: Ettinger SJ, Feldman EC, ed. *Textbook of Veterinary Internal Medicine, 7th ed.* St. Louis, MO: Saunders Elsevier; 2010:1722-50.

Peterson ME. Hypercalcemia in dogs & cats: differential diagnosis & treatment. Proceedings from the Western Veterinary Conference, Las Vegas, NV, February 19-23, 2012.