



PATIENT

Yankee Styers

SPECIES

Canine

BREED

Bichon

SEX

Neutered male

AGE

12 years

WEIGHT

20 lbs

INTERPRETED BY

Eric Lindquist, DMV
DABVP, Cert. IVUSS

IMAGING PERFORMED BY

Brandon

HOSPITAL NAME

Dillsburg VC

REFERRING VET

Dr. Pryor

INVOICE

69735

DATE

12/31/25

PRESENTING CLINICAL SIGNS

History of murmur and bladder stones; Needs another cystotomy. Not currently on
Abnormal PE/Chem/CBC/UA Results: BW and EKG pending

ULTRASONOGRAPHIC EXAMINATION OF THE HEART

Multiple oblique views of the heart were submitted in this patient. Vegetative mitral valve was noted. This is likely the cause of the underlying murmur. Occasional arrhythmia was noted. EKG is indicated. There was no significant volume overload of the left atrium or left ventricle. The contractility appeared adequate. No pericardial or pleural effusion was noted.

Limited parameters were recovered:

CANINE CARDIAC PARAMETERS	MR VMAX (m/s)	TR VMAX (m/s)	LA/AO	LA/AO (Heart Base)	FS (%)	EF (%)	EPSS (cm)
NORMAL PARAMETER	4.5-5.5	<2.7	1.3	<1.6	28-40	40-100	<0.6
CANINE CARDIAC PARAMETERS	HR (BPM)	AV VMAX (m/s)	PV MAX (m/s)	BODY WEIGHT	LA 2D short axis Base view (cm)	LVIDd Avg; 2D and m-mode short axis (cm)	LVIDs Avg; 2D and m-mode short axis (cm)
NORMAL PARAMETER	50-100	0.7-1.7	0.7-1.6	BELOW	BELOW	BELOW	BELOW
PATIENT	80	NM	NM	20 lbs	3.3 max	3.0	

ULTRASONOGRAPHIC FINDINGS

Vegetative mitral valve, like stage B1 valvular disease. Normal compensatory function.

Occasional arrhythmia was noted.

INTERPRETATION OF THE FINDINGS & FURTHER RECOMMENDATIONS

There is no gross contraindication to anesthetic procedure in this patient based on the echocardiogram provided. I recommend EKG in this patient. Minor risk of anesthesia of short duration were present as long as blood pressures and EKG are normal. Further imaging and Doppler assessment is necessary for complete interrogation of the heart.



PATIENT

Yankee Styers

SPECIES

Canine

BREED

Bichon

SEX

Neutered male

AGE

12 years

WEIGHT

20 lbs

INTERPRETED BY

Eric Lindquist, DMV
DABVP, Cert. IVUSS

IMAGING PERFORMED BY

Brandon

HOSPITAL NAME

Dillsburg VC

REFERRING VET

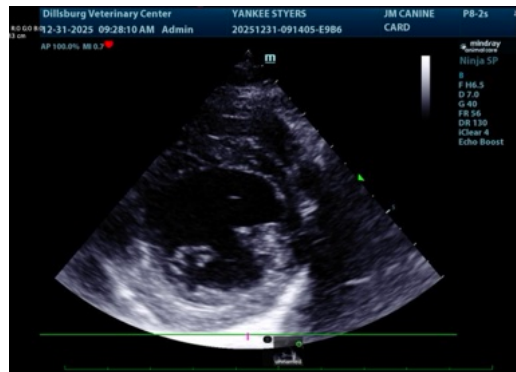
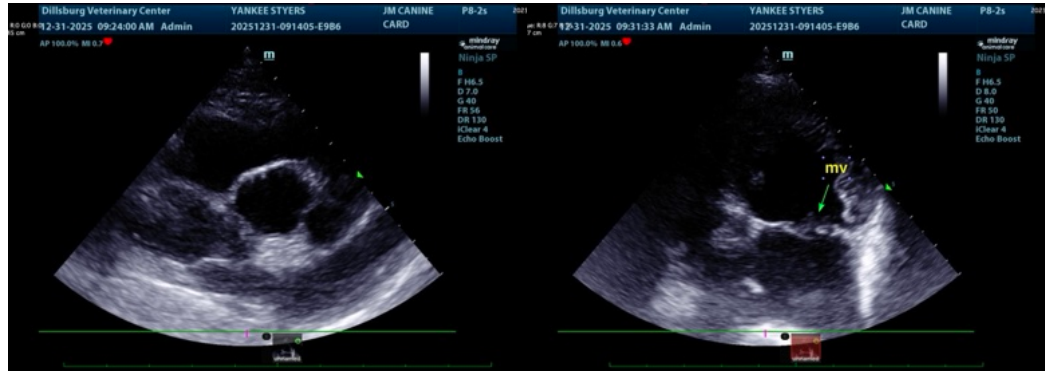
Dr. Pryor

INVOICE

69735

DATE

12/31/25



The information and recommendations provided are based on the images presented by the referring veterinarian/sonographer. No evaluation can be communicated regarding pathology that was not visible in the image/video clips provided.

Thank you for this referral. If the clinical or image interpretation does not parallel your findings or if I can be of any further assistance please contact me.

Eric Lindquist, DMV, DABVP (CFM), Cert. IVUSS, CEO of SonoPath.com

info@SonoPath.com