


PATIENT PRESENTING CLINICAL SIGNS

Sophie Fuentes

 History: past 6 months restless at night pacing whining
 Abnormal PE/Chem/CBC/UA Results: ALP 227 remainder WNL 4dx neg

SPECIES

Canine

ULTRASONOGRAPHIC EXAMINATION OF THE HEART
BREED

English Bulldog

The echocardiogram in this patient demonstrated normal **left atrial** size based on 3 separate methods of LA evaluation. **Mitral** valve insufficiency was noted in this patient. The **left ventricle** presented normal thicknesses with linear contour and was not dilated nor restricted. The **myocardium** presented normal echogenicity without subjective evidence of significant fibrotic or ischemic disease. **Contractility** of the ventricular walls was adequate and in normal range for this patient evidenced by the fractional shortening measurement and subjective evaluation of the different regions of the myocardium. The **left ventricular outflow** tract demonstrated normal laminar flow and subjective structural integrity. The **right atrium** and auricle revealed normal size, structure and content. No evidence of masses was noted. **Tricuspid** insufficiency was noted with a centralized jet. The **right ventricle** was of normal size (1/3 diameter of LV), chordae structure, myocardial echogenicity and thickness. **Pulmonary outflow** tract assessment revealed normal valve structure, laminar flow, and diameter (approx. 1:1 pa/ao ratio). No visible **pericardial** or free pleura fluid was noted. The cranial **mediastinum and pericardial and extra-cardiac regions** were free of masses in the visible window.

SEX

Spayed female

AGE

10 years

WEIGHT

78 lbs

INTERPRETED BY

 Eric Lindquist, DMV
 DABVP, Cert. IVUSS

IMAGING PERFORMED BY

Jenn

HOSPITAL NAME

Rockaway

REFERRING VET

Dr. Maniar

CANINE CARDIAC PARAMETERS	MR VMAX (m/s)	TR VMAX (m/s)	LA/AO (Boon method)	LA/AO (Heart Base; Swe)	FS (%)	EF (%)	EPSS (cm)
NORMAL PARAMETER	4.5-5.5	<2.7	1.3	<1.6	28-40	40-100	<0.6
PATIENT			1.3	1.28			0.1
CANINE CARDIAC PARAMETERS	HR (BPM)	AV VMAX (m/s)	PV MAX (m/s)	BODY WEIGHT	LA (2D short axis Base view) (cm)	LVIDd (Avg; 2D and m-mode short axis) (cm)	LVIDs (Avg; 2D and m-mode short axis) (cm)
NORMAL PARAMETER	50-100	0.7-1.7	0.7-1.6	BELOW	BELOW	BELOW	BELOW
PATIENT		1.0	0.74	78 lbs	4.0		

ULTRASONOGRAPHIC EXAMINATION OF THE ABDOMEN
Urinary System

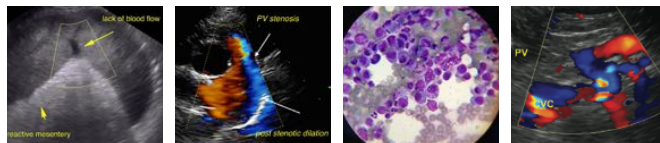
The **urinary bladder**, trigone, and pelvic urethra presented normal thicknesses and normal tone. The ureters were not visible which is normal. No uroliths or sediment were visualized and anechoic urine was present. No evidence of inflammatory or neoplastic changes was noted. Ureteral papillae were normal.

INVOICE

42438

DATE

12/31/22



PATIENT

Sophie Fuentes

The **kidneys** revealed normal size and structure, corticomedullary definition and ratio for this age. The cortices presented largely uniform texture with normal echogenic relationship to liver and spleen. Medullary structure differed distinctly from the cortex and no evidence of pelvic dilation was present. The capsules were acceptably uniform without significant irregularities. The right kidney measured 6.87 cm. The left kidney measured 6.75 cm.

SPECIES

Canine

Adrenal Glands

BREED

English Bulldog

Both **adrenal glands** were visualized and recognized as having normal shape, size, position and echogenicity for this breed. The phrenic vasculature, glandular echogenicity and detail were unremarkable. Capsule, cortex, and medullary definition were normal for this age patient. The right adrenal gland measured 2.05 x 1.03 cm at the cranial pole and 0.9 cm at the caudal pole. The left adrenal gland measured 1.55 x 0.54 cm at the caudal pole and 0.64 cm at the cranial pole.

SEX

Spayed female

Spleen

AGE

10 years

The **spleen** presented a smooth homogeneous parenchyma hyperechoic to liver and renal cortical parenchyma. The capsule was smooth without noticeable expansion or deviation from within the spleen or adjacent pathology. The splenic vasculature demonstrated normal volume without signs of congestion or thrombosis. No sonographic evidence of acute or chronic inflammatory, neoplastic, or infarctual changes was noted.

WEIGHT

78 lbs

Liver

INTERPRETED BY

Eric Lindquist, DMV
DABVP, Cert. IVUSS

The **liver** images submitted revealed subjectively normal liver size, contour, and structure. Parenchymal echogenicity was naturally coarse and hypoechoic to the spleen. Vascular and biliary tracts were of normal volume with no evidence of congestion. The gallbladder presented acceptably thin walls with primarily anechoic content. The cystic and common bile ducts were normal. No pathological hepatic lymphadenopathy was evident. No overt structural evidence of inflammatory, infiltrative or regenerative pathology was evident.

IMAGING PERFORMED BY

Jenn

HOSPITAL NAME

Rockaway

Gastrointestinal

Examination of the **gastrointestinal tract** revealed a stomach and intestine free of stasis, of normal wall thickness, acceptable curvilinear mural detail, and peristaltic activity. Small and large intestine demonstrated normal luminal chyme and stool consistency respectively. No obstructive or overt infiltrative disease was noted. No associated abnormal lymphatic activity was noted.

REFERRING VET

Dr. Maniar

Pancreas

INVOICE

42438

The base and limbs of the **pancreas** were observed to be largely isoechoic to surrounding omental fat. Pancreatic duct and capsular contour were acceptably normal and parenchyma respected normal curvilinear patterns. No overt evidence of active inflammatory or neoplastic disease was noted.

DATE

12/31/22



PATIENT

Sophie Fuentes

ULTRASONOGRAPHIC FINDINGS

Stage B1 valvular disease.

Age related abdominal changes.

SPECIES

Canine

INTERPRETATION OF THE FINDINGS & FURTHER RECOMMENDATIONS

BREED

English Bulldog

The heart is stable without clinical disease. No overt contraindication for anesthesia of brief to moderate duration. I suggest Torbutrol premed, Propofol induction, Isoflor maintenance or similar protocol if anesthesia is desired. Blood pressure recommended if not already performed and target white coat negative systolic pressure of < 160 mmHg. If higher than this ACE-inhibitor is suggested to reach this level. Recheck echocardiogram is recommended in 6 months, earlier if murmur grade increases or clinical signs initiate.

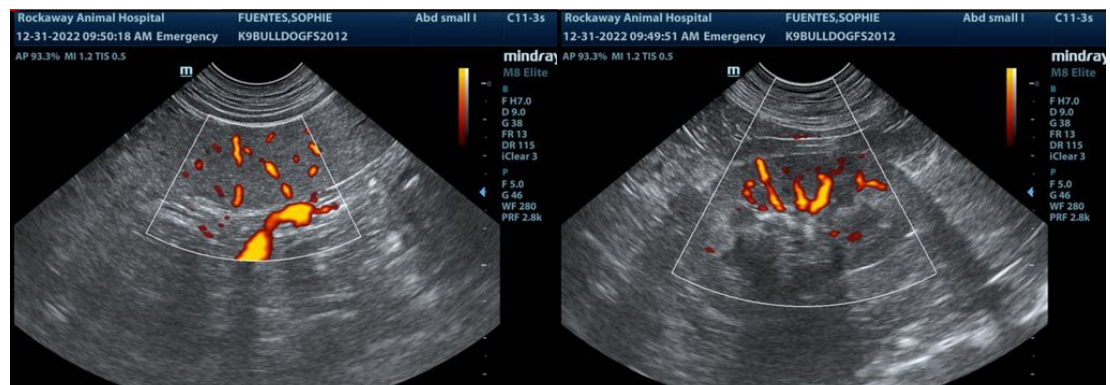
SEX

Spayed female

The cause of restlessness is unclear in this patient. Blood pressure measurements, full orthopedic and CNS examination is indicated to assess for pain related disease.

AGE

10 years



WEIGHT

78 lbs

INTERPRETED BY

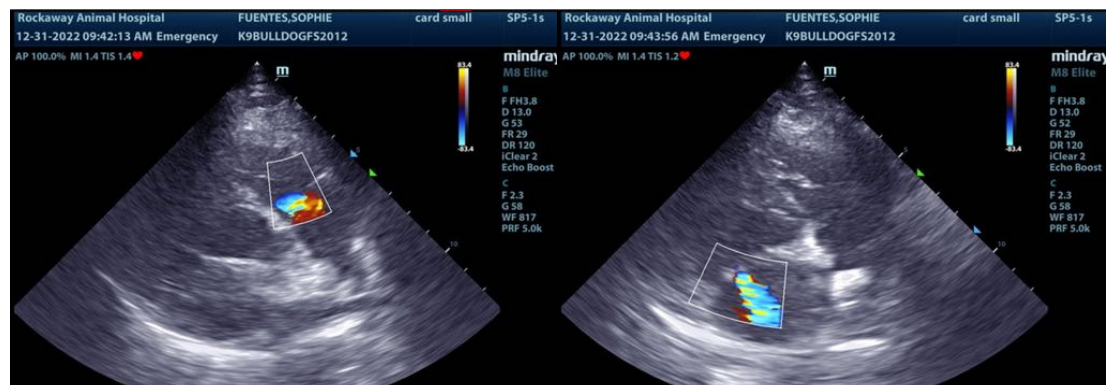
Eric Lindquist, DMV
DABVP, Cert. IVUSS

IMAGING PERFORMED BY

Jenn

HOSPITAL NAME

Rockaway



REFERRING VET

Dr. Maniar

INVOICE

42438

DATE

12/31/22



PATIENT

Sophie Fuentes

SPECIES

Canine

BREED

English Bulldog

SEX

Spayed female

AGE

10 years

WEIGHT

78 lbs

INTERPRETED BY

Eric Lindquist, DMV
DABVP, Cert. IVUSS

IMAGING PERFORMED BY

Jenn

HOSPITAL NAME

Rockaway

REFERRING VET

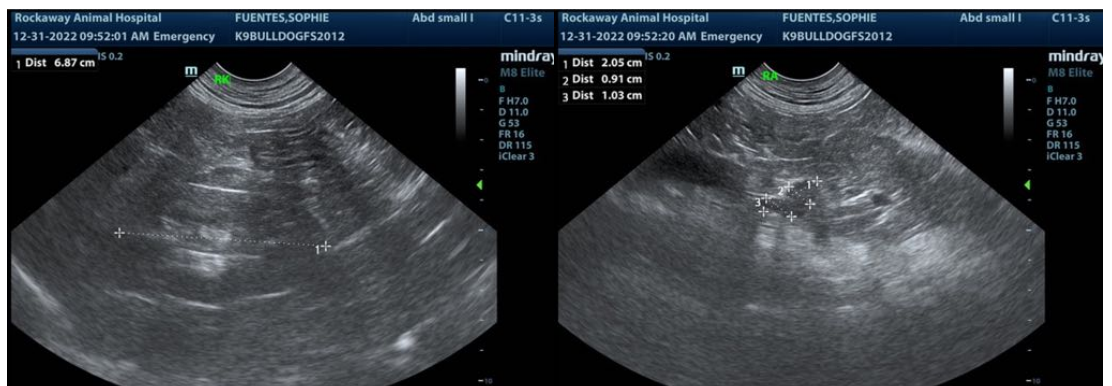
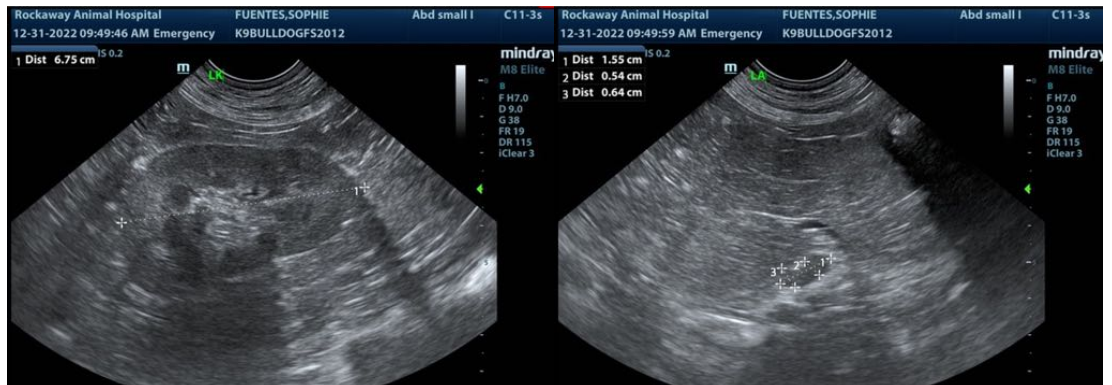
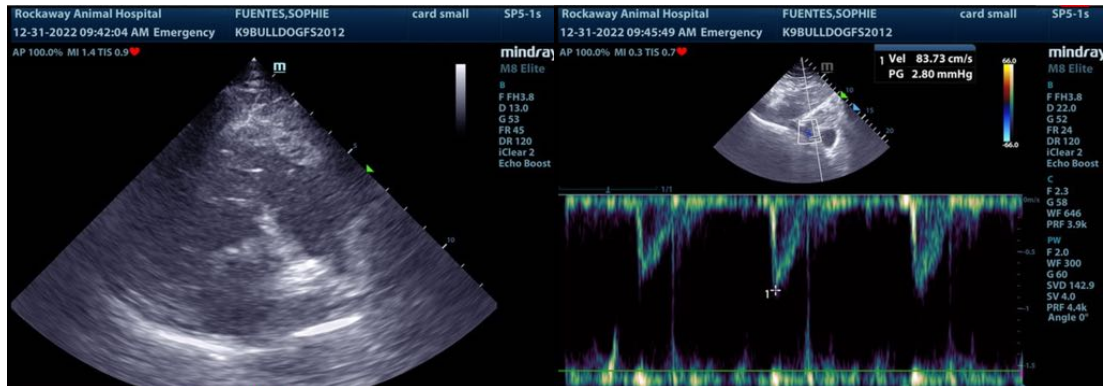
Dr. Maniar

INVOICE

42438

DATE

12/31/22



The information and recommendations provided are based on the images presented by the referring veterinarian/sonographer. No evaluation can be communicated regarding pathology that was not visible in the image/video clips provided.

Thank you for this referral. If the clinical or image interpretation does not parallel your findings or if I can be of any further assistance please contact me.

Eric Lindquist, DMV, DABVP, Cert. IVUSS, CEO of SonoPath.com
info@SonoPath.com