

PATIENT PRESENTING CLINICAL SIGNS

Zoe Guzzi Cushing's disease, recheck adrenal glands.

ULTRASONOGRAPHIC EXAMINATION OF THE ABDOMEN

SPECIES
Urinary System

Canine

The **urinary bladder**, trigone, and pelvic urethra presented normal thicknesses and normal tone. The ureters were not visible which is normal. No uroliths or sediment were visualized and anechoic urine was present. No evidence of inflammatory or neoplastic changes were noted. Ureteral papillae were normal.

BREED

Miniature Pinscher

The **kidneys** presented moderate degenerative changes with polycystic cortices and pinpoint mineralizations and pelvic dilation. The left kidney measured 4.5 cm. The right kidney measured 6.5 cm.

SEX

Spayed Female

Adrenal Glands

The **left adrenal gland** was severely enlarged at 4.0 cm x 1.88 cm at the cranial pole and 1.66 cm at the caudal pole. The **right adrenal gland** was heterogeneous and nodular, measuring 3.81 cm x 2.99 cm at the cranial pole and 0.80 cm at the caudal pole.

AGE

14 Years

Spleen

The **spleen** presented a smooth homogeneous parenchyma hyperechoic to liver and renal cortical parenchyma. The capsule was smooth without noticeable expansion or deviation from within the spleen or adjacent pathology. The splenic vasculature demonstrated normal volume without signs of congestion or thrombosis. No sonographic evidence of acute or chronic inflammatory, neoplastic, or infarctual changes were noted.

INTERPRETED BY

Eric Lindquist, DMV
DABVP, Cert. IVUSS

IMAGING PERFORMED BY

Eric Lindquist, DMV
DABVP, Cert. IVUSS

HOSPITAL NAME

Rockaway AH

Liver

The **liver** was uniformly swollen with minor, excessive gallbladder debris and over distension with dependent and suspended bile without evidence of overt mucocele formation. However, excessive sludge was present. The liver presented coarse architecture with mildly increased portal markings and subtle, mixed echogenic changes. This is consistent with vacuolar hepatopathy and some level of remodeling and history of inflammatory component. There was no overt suspicion of neoplasia.

REFERRING VET

Dr. Maniar

Gastrointestinal

Examination of the **gastrointestinal tract** revealed a stomach and intestine free of stasis, of normal wall thickness, acceptable curvilinear mural detail, and peristaltic activity. Small and large intestine demonstrated normal luminal chyme and stool consistency respectively. No obstructive or overt infiltrative disease was noted. No associated abnormal lymphatic activity was noted.

INVOICE

33871

Pancreas

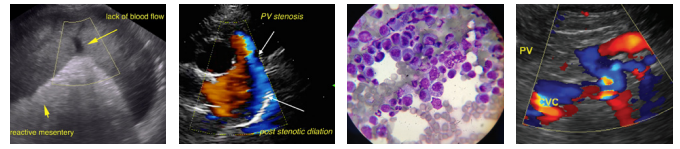
The base and limbs of the **pancreas** were observed to be largely isoechoic to surrounding omental fat. Pancreatic duct and capsular contour were acceptably normal and parenchyma respected normal curvilinear patterns. No overt evidence of active inflammatory or neoplastic disease was noted.

DATE

12/31/21

ULTRASONOGRAPHIC FINDINGS

- Persistent bilateral adrenal enlargement
- Polycystic kidney disease with moderate degenerative changes and calculi
- Geriatric abdomen otherwise



PATIENT

Zoe Guzzi

INTERPRETATION OF THE FINDINGS & FURTHER RECOMMENDATIONS

Serial blood pressures, urine catecholamine, further workup for Cushing's all indicated. Neither adrenal gland is invasive. Hyperplasia, adenocarcinoma, pheochromocytoma of either adrenal possible.

SPECIES

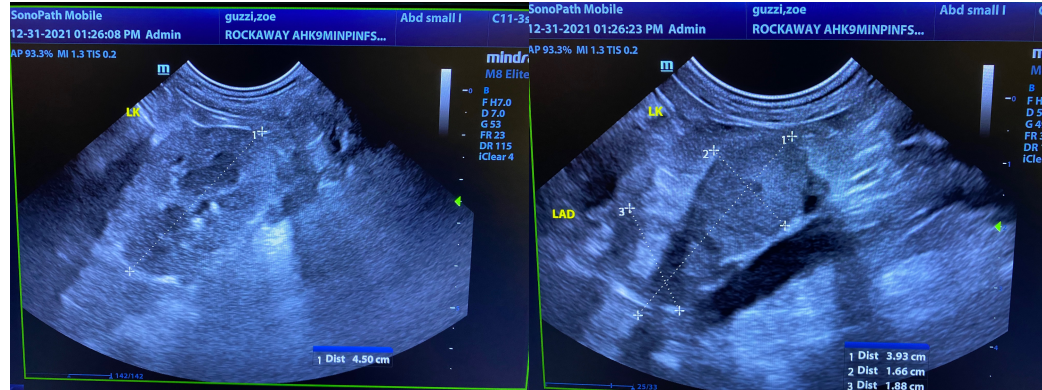
Canine

BREED

Miniature Pinscher

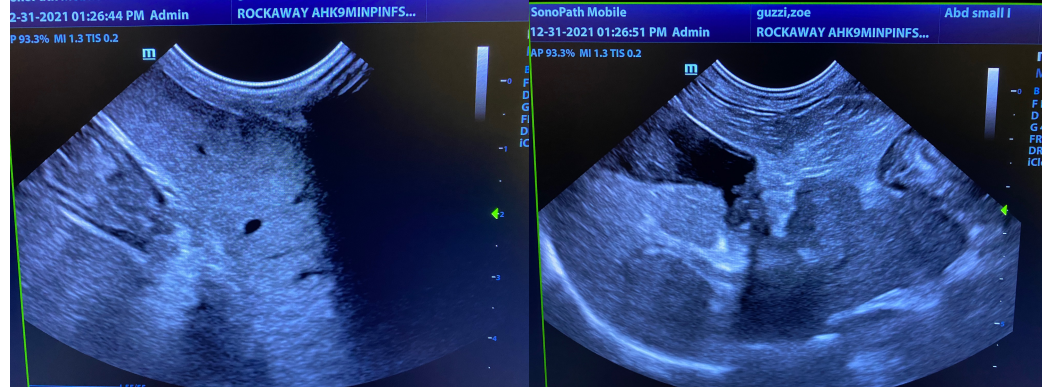
SEX

Spayed Female



AGE

14 Years



INTERPRETED BY

Eric Lindquist, DMV
DABVP, Cert. IVUSS

IMAGING PERFORMED BY

Eric Lindquist, DMV
DABVP, Cert. IVUSS

HOSPITAL NAME

Rockaway AH

REFERRING VET

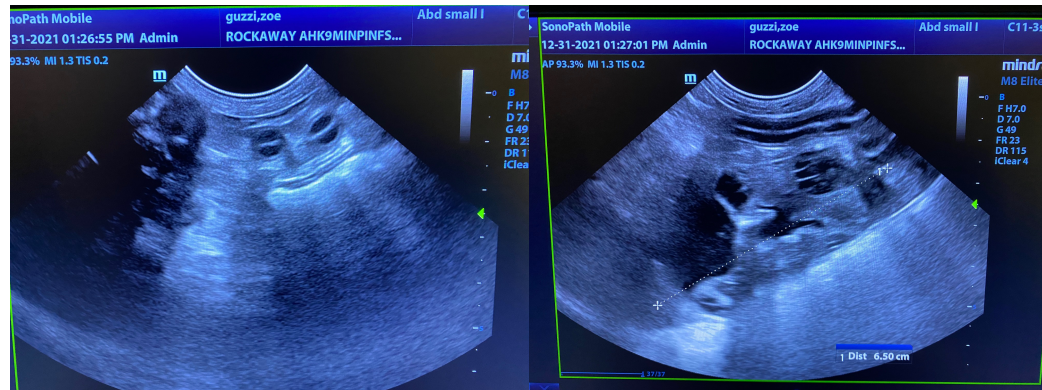
Dr. Maniar

INVOICE

33871

DATE

12/31/21





PATIENT

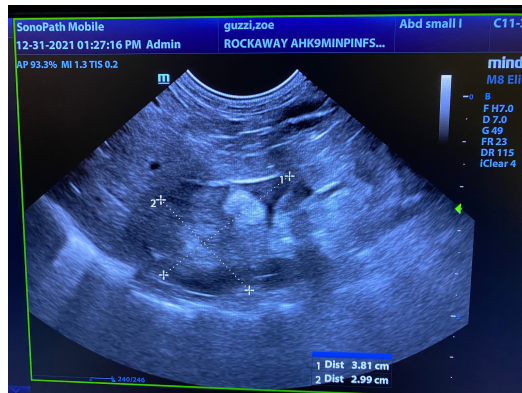
Zoe Guzzi

SPECIES

Canine

BREED

Miniature Pinscher



SEX

Spayed Female

AGE

14 Years

The information and recommendations provided are based on the images presented by the referring veterinarian. No evaluation can be communicated regarding pathology that was not visible in the image/video clips provided.

Thank you for this referral. If the clinical or image interpretation does not parallel your findings or if I can be of any further assistance please contact me.

INTERPRETED BY

Eric Lindquist, DMV
DABVP, Cert. IVUSS

Eric Lindquist, DMV, DABVP, Cert. IVUSS, CEO of SonoPath.com
Info@SonoPath.com

IMAGING PERFORMED BY

Eric Lindquist, DMV
DABVP, Cert. IVUSS

HOSPITAL NAME

Rockaway AH

REFERRING VET

Dr. Maniar

INVOICE

33871

DATE

12/31/21