



PATIENT PRESENTING CLINICAL SIGNS

Ginger Roberti hypertension, limb swelling
 Abnormal PE/Chem/CBC/UA Results: BUN 30.6, crea 1.6, ALKP 159, glu 161

SPECIES ULTRASONOGRAPHIC EXAMINATION OF THE HEART & ABDOMEN

Canine

BREED

Mix

SEX

Spayed Female

AGE

12 Years

WEIGHT

59.1 Pounds

CANINE CARDIAC PARAMETERS	MR VMAX (m/s)	TR VMAX (m/s)	LA/AO (Boon method)	LA/AO (Heart Base; Swe)	FS (%)	EF (%)	EPSS (cm)
NORMAL PARAMETER	4.5-5.5	<2.7	1.3	<1.6	28-40	40-100	<0.6
PATIENT			1.15	1.0	50		NM
CANINE CARDIAC PARAMETERS	HR (BPM)	AV VMAX (m/s)	PV MAX (m/s)	BODY WEIGHT (kg)	LA 2D short axis Base view (cm)	LVIDd Avg; 2D and m-mode short axis (cm)	LVIDs Avg; 2D and m-mode short axis (cm)
NORMAL PARAMETER	50-100	0.7-1.7	0.7-1.6				
PATIENT		2.38			3.3	1.6	

Cardiac Presentation

The echocardiogram in this patient demonstrated normal **left atrial** size based on 3 separate methods of LA evaluation. The cranial and caudal **mitral** valve leaflets presented normal linear structure, extension in systole, and union in diastole with normal kinesis. The **left ventricle** presented thicknesses with linear contour and was not dilated nor restricted. The **myocardium** presented normal echogenicity without subjective evidence of significant fibrotic or ischemic disease. **Contractility** of the ventricular walls was adequate and in normal range for this patient evidenced by the fractional shortening measurement and subjective evaluation of the different regions of the myocardium. The **left ventricular outflow** tract demonstrated normal laminar flow and subjective structural integrity. The **right atrium** and auricle revealed normal size, structure and content. No evidence of masses was noted. **Tricuspid** valvular assessment demonstrated adequate linear morphology and kinesis. The **right ventricle** was of normal size (1/3 diameter of LV), chordae structure, myocardial echogenicity and thickness. **Pulmonary outflow** tract assessment revealed normal valve structure, laminar flow, and diameter (approx. 1:1 pa/ao ratio). No visible **pericardial** or free pleura fluid was noted. The cranial **mediastinum and pericardial and extra-cardiac regions** were free of masses in the visible window.

Urinary System

The **bladder** in this patient was mildly thickened with slight echogenic mural changes. No calculi or masses were noted. Slight micropolypoid changes were noted. This is a frequent finding in older animals and may be linked to a history of chronic urinary tract infection or active urinary tract infection. Urinalysis would be recommended with culture if any evidence of inflammatory sediment is present. The region of the trigone and visible pelvic urethra were normal. The pelvic urethra was imaged 3.0 cm beyond the cystourethral junction.

INTERPRETED BY

Eric Lindquist, DMV
 DABVP, Cert. IVUSS

IMAGING PERFORMED BY

Diane McFadden

HOSPITAL NAME

Newton Vet Hospital

REFERRING VET

Dr. Barron

INVOICE

33884

DATE

12/31/21



PATIENT

Ginger Roberti

The **kidneys** revealed largely normal size and structure, corticomedullary definition and ratio (cortex 1/3 of medulla) were essentially maintained with some age-related loss of curvilinear patterns regarding the capsule and C/M junction. The cortices presented largely uniform texture with some increased echogenicity expected for his age patient. Medullary structure differed distinctly from that of the cortex and no evidence of pelvic dilation was present. Corticomedullary mineralization noted in both kidneys. The left kidney measured 5.0 cm. The right kidney measured 6.0 cm.

SPECIES

Canine

Adrenal Glands

BREED

Mix

Both **adrenal glands** were visualized and recognized as having normal shape, size, position and echogenicity for this breed. The phrenic vasculature, glandular echogenicity and detail were unremarkable. Capsule, cortex, and medullary definition were normal for this age patient. The right adrenal gland measured 8.23 cm x 1.64 cm at the cranial pole and 0.84 cm at the caudal pole. The left adrenal gland measured 2.47 cm x 0.48 cm at the caudal pole and 0.67 cm at the cranial pole.

SEX

Spayed Female

Spleen

The **spleen** presented minor heterogeneous parenchymal changes and was folded upon itself cranially.

AGE

12 Years

Liver

The **liver** images from right and left intercostal as well as subcostal views revealed subjectively normal liver size, contour, and structure. Some age-related parenchymal remodeling was noted but likely not clinically significant at this time. Vascular and biliary tracts were of normal volume and no evidence of congestion was noted. The gallbladder presented some dependent debris with essentially normal contour. The cystic and common bile ducts were normal. No overt evidence of active inflammatory, infiltrative or regenerative pathology was noted but should be paired with current or past LE elevations regarding any clinical significance to this presentation. The hepatic lymph nodes were unremarkable.

WEIGHT

59.1 Pounds

Gastrointestinal

INTERPRETED BY

Eric Lindquist, DMV
DABVP, Cert. IVUSS

Examination of the **gastrointestinal tract** revealed a stomach and intestine free of stasis, of normal wall thickness, acceptable curvilinear mural detail, and peristaltic activity. Small and large intestine demonstrated normal luminal chyme and stool consistency respectively. No obstructive or overt infiltrative disease was noted. No associated abnormal lymphatic activity was noted.

IMAGING PERFORMED BY

Diane McFadden

Pancreas

The base and limbs of the **pancreas** were observed to be largely isoechoic to surrounding omental fat. Pancreatic duct and capsular contour were acceptably normal and parenchyma respected normal curvilinear patterns. No overt evidence of active inflammatory or neoplastic disease was noted.

HOSPITAL NAME

Newton Vet Hospital

ULTRASONOGRAPHIC FINDINGS

REFERRING VET

Dr. Barron

- Normal echocardiogram with minor increased left ventricular outflow velocity – likely owing to hypertension or hyperdynamic state.
- Moderate degenerative renal changes with mineralization, non-obstructive

INTERPRETATION OF THE FINDINGS & FURTHER RECOMMENDATIONS

INVOICE

33884

No evidence of primary cardiac disease. No evidence of neoplasia. Full urinary workup warranted given the bladder wall thickening and antihypertensives. The cause of hind limb swelling is not evident from an abdominal standpoint.

DATE

12/31/21



PATIENT

Ginger Roberti

SPECIES

Canine

BREED

Mix

SEX

Spayed Female

AGE

12 Years

WEIGHT

59.1 Pounds

INTERPRETED BY

Eric Lindquist, DMV
DABVP, Cert. IVUSS

IMAGING PERFORMED BY

Diane McFadden

HOSPITAL NAME

Newton Vet Hospital

REFERRING VET

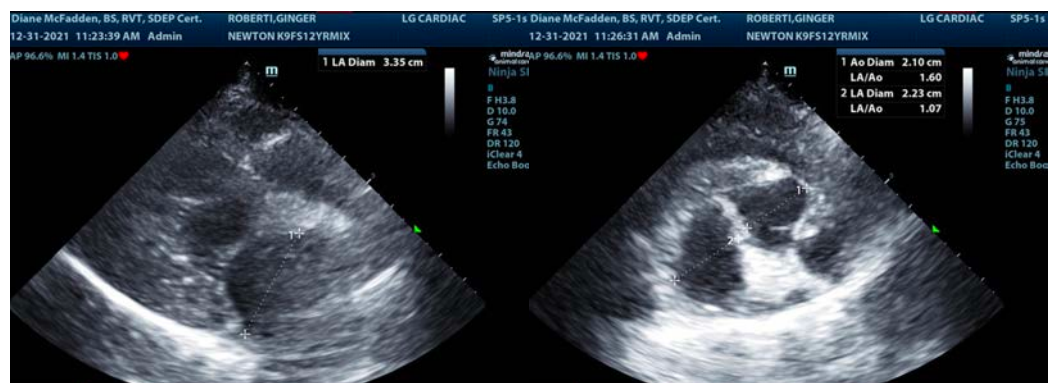
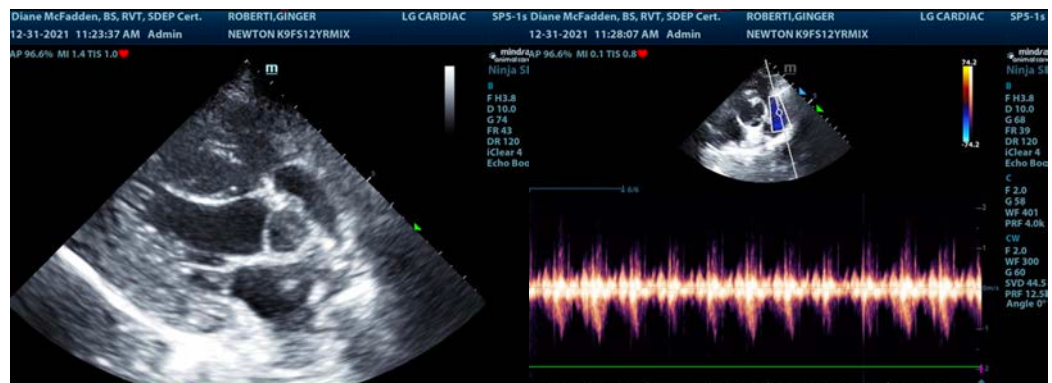
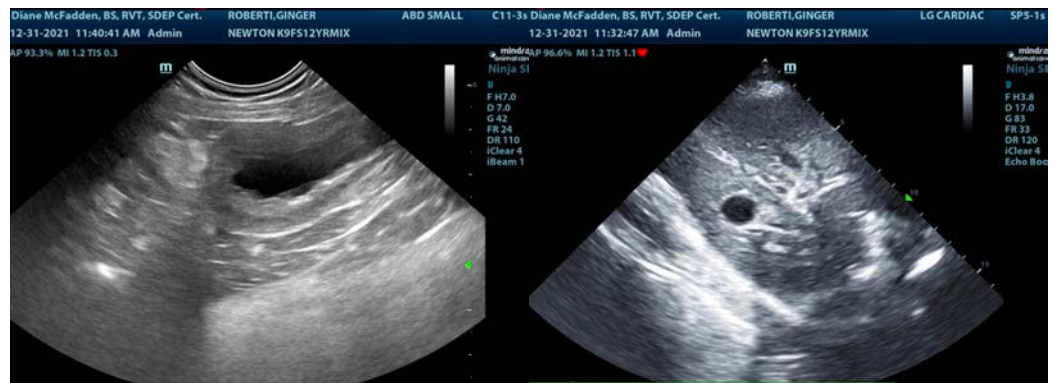
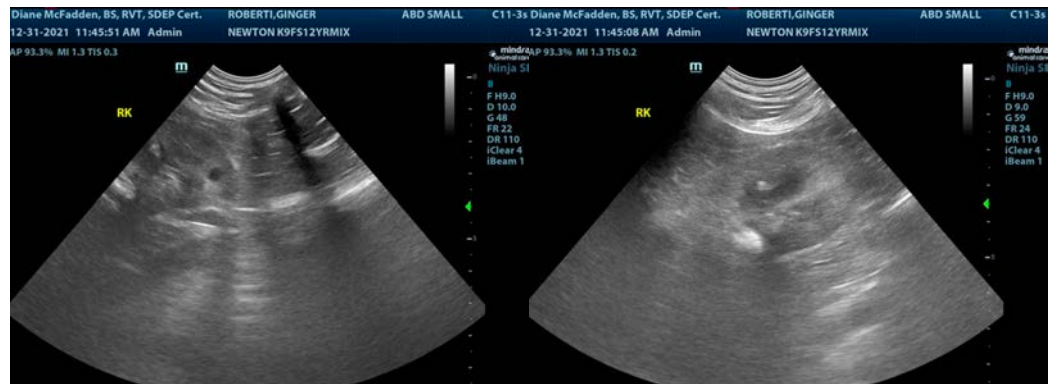
Dr. Barron

INVOICE

33884

DATE

12/31/21





PATIENT

Ginger Roberti

SPECIES

Canine

BREED

Mix

SEX

Spayed Female

AGE

12 Years

WEIGHT

59.1 Pounds

INTERPRETED BY

Eric Lindquist, DMV
DABVP, Cert. IVUSS

IMAGING PERFORMED BY

Diane McFadden

HOSPITAL NAME

Newton Vet Hospital

REFERRING VET

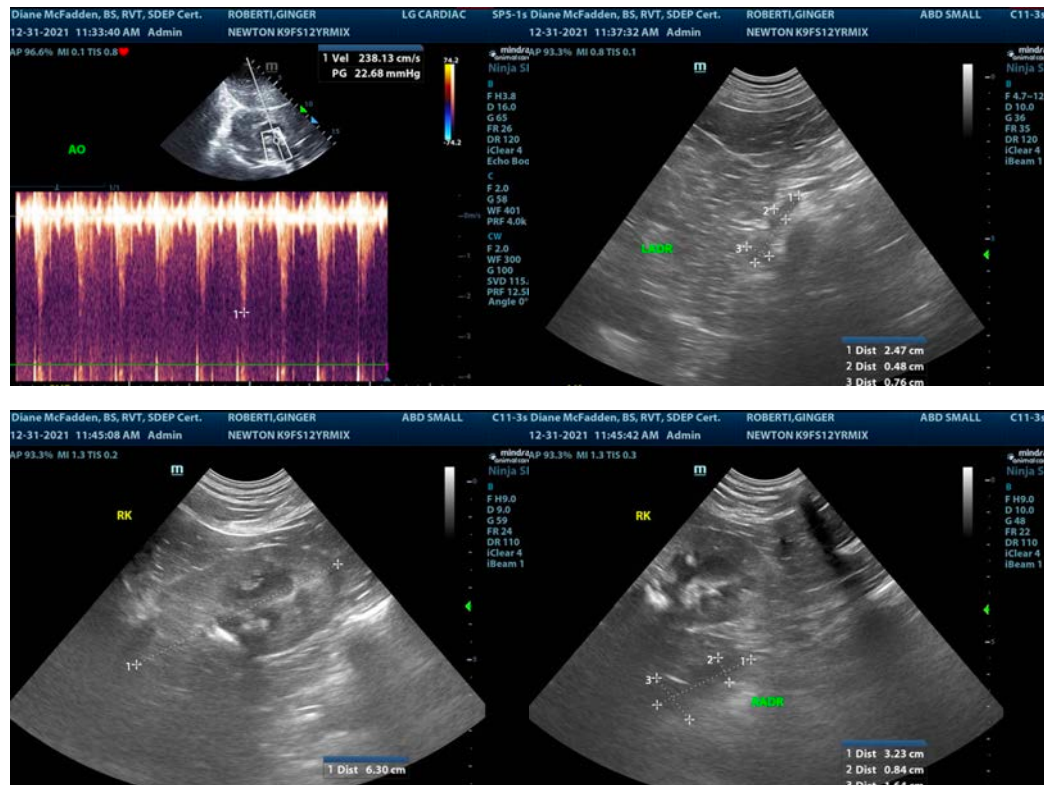
Dr. Barron

INVOICE

33884

DATE

12/31/21



The information and recommendations provided are based on the images presented by the referring veterinarian. No evaluation can be communicated regarding pathology that was not visible in the image/video clips provided.

Thank you for this referral. If the clinical or image interpretation does not parallel your findings or if I can be of any further assistance please contact me.

Eric Lindquist, DMV, DABVP, Cert. IVUSS, CEO of SonoPath.com
info@SonoPath.com