



**PATIENT**

Garfunkel Myzak

**SPECIES**

Feline

**BREED**

DSH

**SEX**

Neutered Male

**AGE**

12 Years

**WEIGHT**

4.51 Pounds

**INTERPRETED BY**

Eric Lindquist, DMV  
DABVP, Cert. IVUSS

**IMAGING PERFORMED BY**

Dr. Kristin Peterson

**HOSPITAL NAME**

Wilvet Salem

**REFERRING VET**

Dr. Rowley

**INVOICE**

33892

**DATE**

12/31/21

**PRESENTING CLINICAL SIGNS**

Referred by Dr Rowley. 2# weight loss since October, Hx Nasopharyngeal stricture, enlarged kidney, abnormal cells in urine.

Abnormal PE/Chem/CBC/UA Results: QAR, MM pale pink, CRT < 2s, Mild dehydration 7%, Right eye previous enucleation, Thoracic auscultation no murmur or gallop, eupenic with normal BV sounds but referred upper airway noise, Abdominal palpation nonpainful, Left kidney is very large, no palpable masses, urinary bladder medium size and soft. Azotemic, abnormal cells in urine, weight loss 2# since October

**LIMITED ULTRASONOGRAPHIC EXAMINATION**

The urinary bladder, trigone, and pelvic urethra presented normal thicknesses and normal tone. The ureters were not visible which is normal. No uroliths or sediment were visualized and anechoic urine was present. No evidence of inflammatory or neoplastic changes were noted. Ureteral papillae were normal.

The right kidney was enlarged (5.5 cm) and irregular with subcapsular halo and thickened, irregular, nodular cortices. Slight pyelectasia noted. An overt cortical mass was noted. The mass measured approximately 2.5 cm.

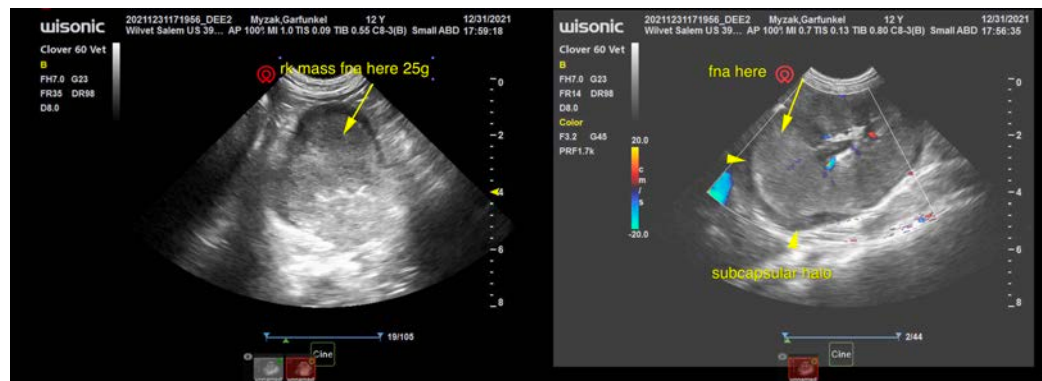
The left kidney also appeared enlarged and irregular, measuring approximately 5.0 cm with loss of corticomedullary and early subcapsular halo.

**ULTRASONOGRAPHIC FINDINGS**

- Renal lymphoma pattern

**INTERPRETATION OF THE FINDINGS & FURTHER RECOMMENDATIONS**

The kidneys were not labeled, and I'm presuming both kidneys have similar appearance. However, the right kidney definitely has abnormal appearance with nodular changes and an overt mass. Recommended ultrasound guided FNA of the right kidney. Prognosis is poor depending upon responsiveness to chemotherapy.





**PATIENT**

Garfunkel Myzak

**SPECIES**

Feline

**BREED**

DSH

**SEX**

Neutered Male

**AGE**

12 Years

**WEIGHT**

4.51 Pounds

**INTERPRETED BY**

Eric Lindquist, DMV  
DABVP, Cert. IVUSS

**IMAGING  
PERFORMED BY**

Dr. Kristin Peterson

**HOSPITAL NAME**

Wilvet Salem

**REFERRING VET**

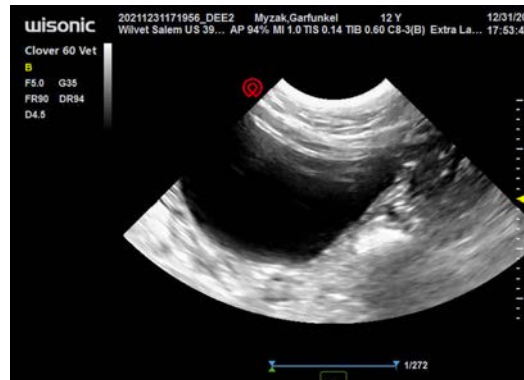
Dr. Rowley

**INVOICE**

33892

**DATE**

12/31/21



The information and recommendations provided are based on the images presented by the referring veterinarian. No evaluation can be communicated regarding pathology that was not visible in the image/video clips provided.

Thank you for this referral. If the clinical or image interpretation does not parallel your findings or if I can be of any further assistance please contact me.

Eric Lindquist, DMV, DABVP, Cert. IVUSS, CEO of SonoPath.com  
[info@SonoPath.com](mailto:info@SonoPath.com)