



PATIENT

Sprinkles Darr

SPECIES

Canine

BREED

Boxer Mix

SEX

Spayed Female

AGE

10 Years

WEIGHT

56 pounds

INTERPRETED BY

Eric Lindquist, DMV,
DABVP(CFM), Cert.
IVUSS

IMAGING PERFORMED BY

Eric Lindquist, DMV,
DABVP(CFM), Cert.
IVUSS

HOSPITAL NAME

Loving Care Veterinary
Hospital

REFERRING VET

Dr. Steele

INVOICE

12874

DATE

12/30/25

PRESENTING CLINICAL SIGNS

Anemic (↓HCT, reticulocytes low). No current medications. Hematocrit ↓ Hemoglobin ↓ MCH ↓ reticulocytes ↓ WBC ↓ lymphocytes ↓ ALP ↑ cholesterol ↑ Lipase ↑ Urine protein 2+.

ULTRASONOGRAPHIC EXAMINATION OF THE HEART & ABDOMEN

CANINE CARDIAC PARAMETERS	MR VMAX (m/s)	TR VMAX (m/s)	LA/AO (M-Mode)	LA/AO (Heart Base; Swe)	FS (%)	EF (%)	EPSS (cm)
NORMAL PARAMETER	4.5-5.5	<2.7	1.3	Up to 1.6	28-40	40-100	<0.6
PATIENT	--	--	1.3	1.4	27	54	NM
CANINE CARDIAC PARAMETERS	HR (BPM)	AV VMAX (m/s)	PV MAX (m/s)	BODY WEIGHT (kg)	LAD LA MAX 4 Chamber	LVIDd Avg; 2D and m-mode short axis (cm)	LVIDs Avg; 2D and m-mode short axis (cm)
NORMAL PARAMETER	50-100	0.7-1.7	0.7-1.6				
PATIENT	--	1.4	0.85	--	4.02	3.75	--

Cardiac Presentation

The echocardiogram in this patient demonstrated normal **left atrial** size based on 3 separate methods of LA evaluation. The cranial and caudal **mitral** valve leaflets presented normal linear structure, extension in systole, and union in diastole with normal kinesis. The **left ventricle** presented normal thicknesses with linear contour and was not dilated nor restricted. The **myocardium** presented normal echogenicity without subjective evidence of significant fibrotic or ischemic disease. **Contractility** of the ventricular walls was adequate and in normal range for this patient evidenced by the fractional shortening measurement and subjective evaluation of the different regions of the myocardium. The **left ventricular outflow** tract demonstrated normal laminar flow and subjective structural integrity. The **right atrium** and auricle revealed normal size, structure and content. No evidence of masses was noted. **Tricuspid** valvular assessment demonstrated adequate linear morphology and kinesis. The **right ventricle** was of normal size (1/3 diameter of LV), chordae structure, myocardial echogenicity and thickness. **Pulmonary outflow** tract assessment revealed normal valve structure, laminar flow, and diameter (approx.1:1 pa/ao ratio). No visible **pericardial** or free pleura fluid was noted. The cranial **mediastinum and pericardial and extra-cardiac regions** were free of masses in the visible window. Bradycardia was noted in this patient.

Urinary System

The **urinary bladder**, trigone, and pelvic urethra presented normal thicknesses and normal tone. The ureters were not visible which is normal. No uroliths or sediment were visualized, and anechoic urine



PATIENT

Sprinkles Darr

SPECIES

Canine

BREED

Boxer Mix

SEX

Spayed Female

AGE

10 Years

WEIGHT

56 pounds

INTERPRETED BY

Eric Lindquist, DMV,
 DABVP(CFM), Cert.
 IVUSS

IMAGING PERFORMED BY

Eric Lindquist, DMV,
 DABVP(CFM), Cert.
 IVUSS

HOSPITAL NAME

Loving Care Veterinary
 Hospital

REFERRING VET

Dr. Steele

INVOICE

12874

DATE

12/30/25

was present. No evidence of inflammatory or neoplastic changes were noted. Ureteral papillae were normal.

The **kidneys** revealed largely normal size and structure, corticomedullary definition and ratio (cortex 1/3 of medulla) were essentially maintained with some mild age-related loss of curvilinear patterns regarding the capsule and C/M junction. The cortices presented largely uniform texture with some increased echogenicity expected for his age patient. Medullary structure differed distinctly from that of the cortex and no evidence of pelvic dilation was present. The left kidney measured 6.62 cm in length. The right kidney measured 5.98 cm in length.

Adrenal Glands

Both **adrenal glands** were visualized and recognized as having normal shape, size, position and echogenicity for this breed. The phrenic vasculature, glandular echogenicity and detail were unremarkable. Capsule, cortex, and medullary definition were normal for this age patient. The left adrenal gland measured 2.8 cm x 0.68 cm width. The right adrenal gland measured 2.34 cm x 1.53 cm width at the cranial pole and 0.83 cm width at the caudal pole.

Spleen

The **spleen** revealed a 7.4 cm cavitated complex mixed echogenic mass deriving from the mid cranial body. Multiple nodular changes were also noted throughout the spleen.

Liver

The **liver** presented enlarged and irregular with multiple masses and cavitated metastatic type lesions with significant disruption in architecture. The larger mass measured approximately 5.0 cm, however, multiple cavitated nodular changes and target lesions were noted and consistent with metastatic disease deriving from likely hemangiosarcoma or deriving from the spleen.

Gastrointestinal

The **gastrointestinal** tract was structurally unremarkable with minor colonic thickening and soft stool noted.

Pancreas

The base and limbs of the **pancreas** were observed to be largely isoechoic to surrounding omental fat. Pancreatic duct and capsular contour were acceptably normal and parenchyma respected normal curvilinear patterns. No overt evidence of active inflammatory or neoplastic disease was noted.

ULTRASONOGRAPHIC FINDINGS

- Normal echocardiogram with bradyarrhythmia.
- Soft stool in colon.
- Multicentric abdominal neoplasia splenohepatic pattern- hemangiosarcoma likely.

INTERPRETATION OF THE FINDINGS & FURTHER RECOMMENDATIONS

Oncological intervention is recommended, however, prognosis is poor.



PATIENT

Sprinkles Darr

SPECIES

Canine

BREED

Boxer Mix

SEX

Spayed Female

AGE

10 Years

WEIGHT

56 pounds

INTERPRETED BY

Eric Lindquist, DMV,
 DABVP(CFM), Cert.
 IVUSS

IMAGING PERFORMED BY

Eric Lindquist, DMV,
 DABVP(CFM), Cert.
 IVUSS

HOSPITAL NAME

Loving Care Veterinary
 Hospital

REFERRING VET

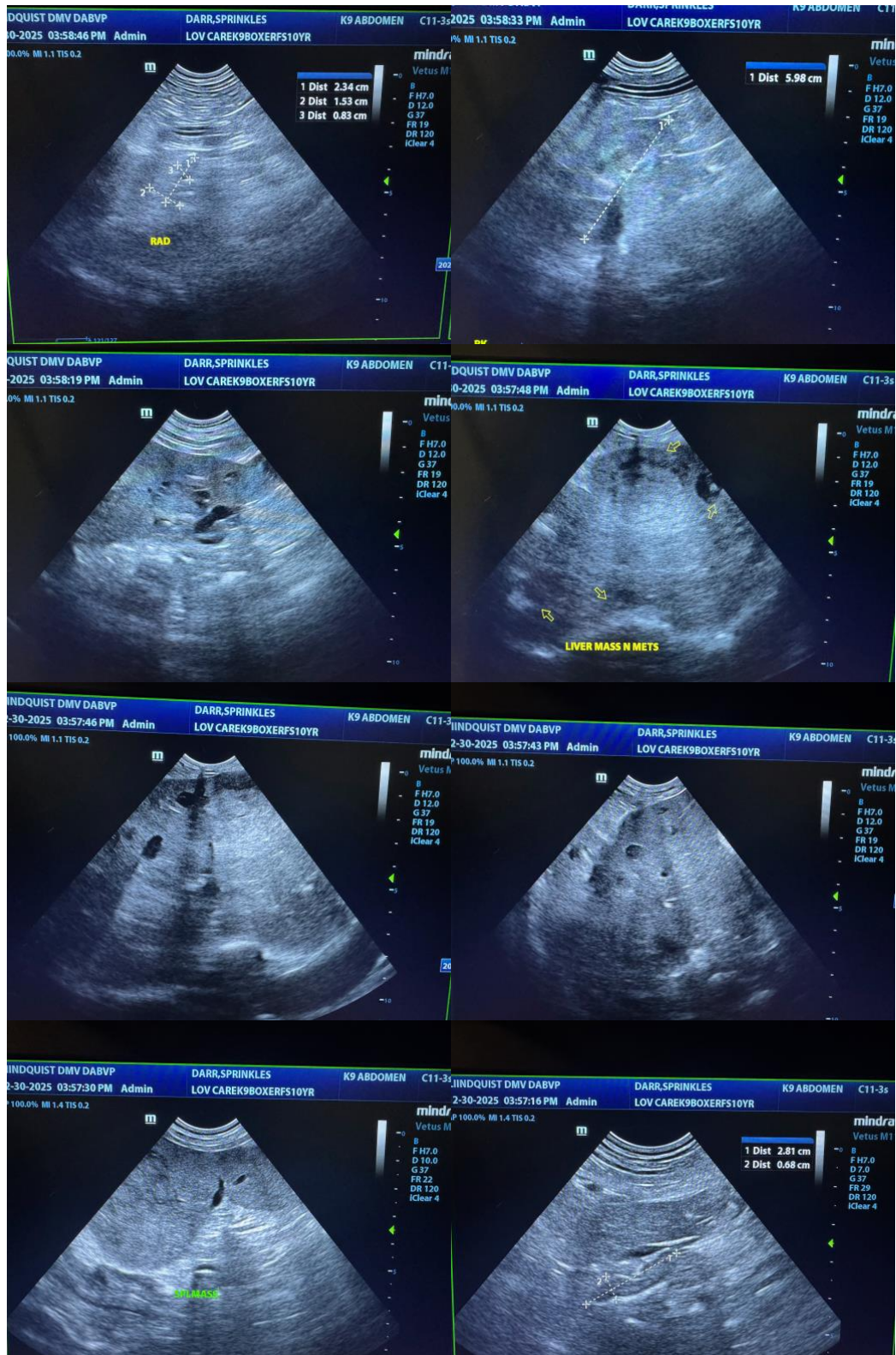
Dr. Steele

INVOICE

12874

DATE

12/30/25





PATIENT

Sprinkles Darr

SPECIES

Canine

BREED

Boxer Mix

SEX

Spayed Female

AGE

10 Years

WEIGHT

56 pounds

INTERPRETED BY

Eric Lindquist, DMV,
 DABVP(CFM), Cert.
 IVUSS

IMAGING PERFORMED BY

Eric Lindquist, DMV,
 DABVP(CFM), Cert.
 IVUSS

HOSPITAL NAME

Loving Care Veterinary
 Hospital

REFERRING VET

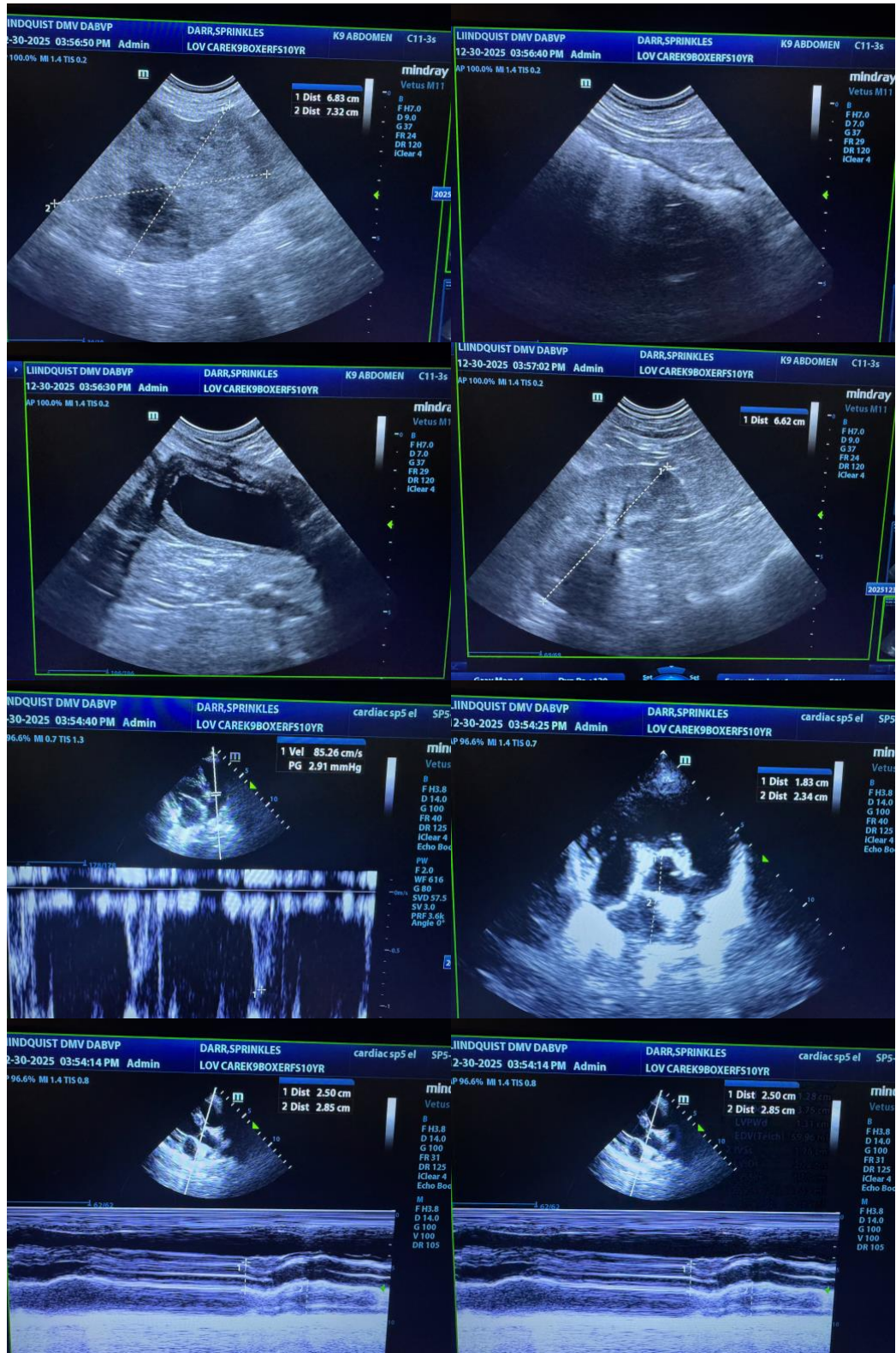
Dr. Steele

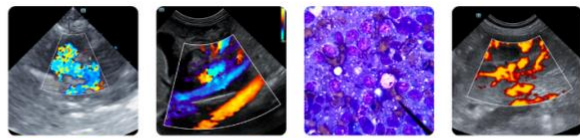
INVOICE

12874

DATE

12/30/25





PATIENT

Sprinkles Darr

SPECIES

Canine

BREED

Boxer Mix

SEX

Spayed Female

AGE

10 Years

WEIGHT

56 pounds

INTERPRETED BY

Eric Lindquist, DMV,
DABVP(CFM), Cert.
IVUSS

**IMAGING
PERFORMED BY**

Eric Lindquist, DMV,
DABVP(CFM), Cert.
IVUSS

HOSPITAL NAME

Loving Care Veterinary
Hospital

REFERRING VET

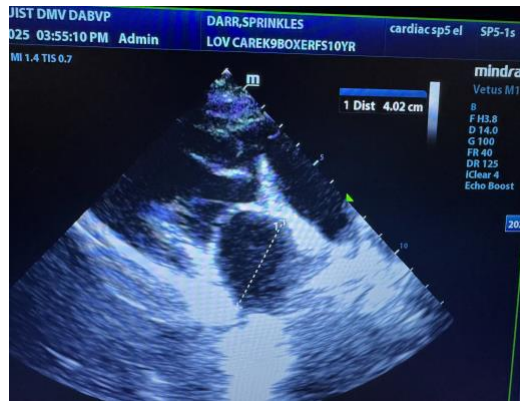
Dr. Steele

INVOICE

12874

DATE

12/30/25



The information and recommendations provided are based on the images presented by the referring veterinarian/sonographer. No evaluation can be communicated regarding pathology that was not visible in the image/video clips provided.

Thank you for this referral. If the clinical or image interpretation does not parallel your findings or if I can be of any further assistance, please contact me.

Eric Lindquist, DMV, DABVP(CFM), Cert. IVUSS,

CEO, Owner, Founder -- SonoPath.com

info@SonoPath.com