



**PATIENT**

Smudge Dibartolomeo

**SPECIES**

Feline

**BREED**

Himalayan

**SEX**

Neutered Male

**AGE**

8

**WEIGHT**

18.3 Pounds

**INTERPRETED BY**

Eric Lindquist, DMV,  
DABVP (CFM), Cert.  
IVUSS

**IMAGING PERFORMED BY**

Eric Lindquist, DMV,  
DABVP (CFM), Cert.  
IVUSS

**HOSPITAL NAME**

Franklin Lakes AH

**REFERRING VET**

Dr. Zilberman

**INVOICE**

35137

**DATE**

12/30/25

**PRESENTING CLINICAL SIGNS**

History: Chronic diarrhea, Wt loss.

Current Medications: B-12

**ULTRASONOGRAPHIC EXAMINATION OF THE ABDOMEN**

**Urinary System**

The **urinary bladder**, trigone, and pelvic urethra presented normal thicknesses and normal tone. The ureters were not visible which is normal. No uroliths or sediment were visualized and anechoic urine was present. No evidence of inflammatory or neoplastic changes was noted. Ureteral papillae were normal.

The **kidneys** revealed largely normal size and structure, corticomedullary definition and ratio (cortex 1/3 of medulla) were essentially maintained with some age-related loss of curvilinear patterns regarding the capsule and C/M junction (mild in the left kidney and moderate in the right kidney). The cortices presented largely uniform texture with some increased echogenicity expected for this age patient. Medullary structure differed distinctly from that of the cortex, and no evidence of pelvic dilation was present. The left kidney measured 4.35 cm. The right kidney measured 3.8 cm. A stable cortical infarct was noted at the cranial pole of the right kidney.

**Adrenal Glands**

Both **adrenal glands** were visualized and recognized as having normal shape, size, position and echogenicity for this breed. The phrenic vasculature, glandular echogenicity and detail were unremarkable. Capsule, cortex, and medullary definition were normal for this age patient. The adrenal glands measured 0.4 cm each.

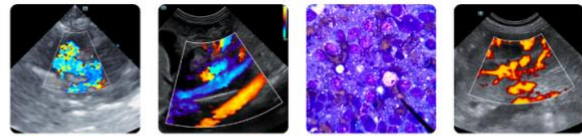
**Spleen**

The **spleen** presented a smooth homogeneous parenchyma hyperechoic to liver and renal cortical parenchyma. The capsule was smooth without noticeable expansion or deviation from within the spleen or adjacent pathology. The splenic vasculature demonstrated normal volume without signs of congestion or thrombosis. No sonographic evidence of acute or chronic inflammatory, neoplastic, or infarctual changes were noted.

**Liver**

The **liver** images submitted revealed subjectively normal liver size, contour, and structure. Parenchymal echogenicity was naturally coarse and hypoechoic to the spleen. Vascular and biliary tracts were of normal volume with no evidence of congestion. The gallbladder presented acceptably thin walls with primarily anechoic content. The cystic and common bile ducts were normal. No pathological hepatic lymphadenopathy was evident. No overt structural evidence of inflammatory, infiltrative or regenerative pathology was evident.

**Gastrointestinal**



**PATIENT**

Smudge Dibartolomeo

**SPECIES**

Feline

**BREED**

Himalayan

**SEX**

Neutered Male

**AGE**

8

**WEIGHT**

18.3 Pounds

**INTERPRETED BY**

Eric Lindquist, DMV,  
DABVP (CFM), Cert.  
IVUSS

**IMAGING  
PERFORMED BY**

Eric Lindquist, DMV,  
DABVP (CFM), Cert.  
IVUSS

**HOSPITAL NAME**

Franklin Lakes AH

**REFERRING VET**

Dr. Zilberman

**INVOICE**

35137

**DATE**

12/30/25

Examination of the **gastrointestinal tract** revealed a stomach and intestine free of stasis, of normal wall thickness, acceptable curvilinear mural detail, and peristaltic activity. Small and large intestine demonstrated normal luminal chyme and stool consistency respectively. No obstructive or overt infiltrative disease was noted. No associated abnormal lymphatic activity was noted.

***Pancreas***

The base and limbs of the **pancreas** were observed to be largely isoechoic to surrounding omental fat. Pancreatic duct and capsular contour were acceptably normal and parenchyma respected normal curvilinear patterns. No overt evidence of active inflammatory or neoplastic disease was noted.

***Free Abdomen***

A large amount of **abdominal fat** was noted in this patient.

**ULTRASONOGRAPHIC FINDINGS**

- Moderate degenerative right renal changes, mild in the left
- Large amount of abdominal fat
- No evidence of abdominal pathology

**INTERPRETATION OF THE FINDINGS & FURTHER RECOMMENDATIONS**

No cause of weight loss was evident. Maldigestion panel, three view chest radiographs and full CNS examination is recommended to examine for occult disease that could be responsible for the weight loss. Evaluation for competitive eating environments should also be considered.



**PATIENT**

Smudge Dibartolomeo

**SPECIES**

Feline

**BREED**

Himalayan

**SEX**

Neutered Male

**AGE**

8

**WEIGHT**

18.3 Pounds

**INTERPRETED BY**

Eric Lindquist, DMV,  
 DABVP (CFM), Cert.  
 IVUSS

**IMAGING PERFORMED BY**

Eric Lindquist, DMV,  
 DABVP (CFM), Cert.  
 IVUSS

**HOSPITAL NAME**

Franklin Lakes AH

**REFERRING VET**

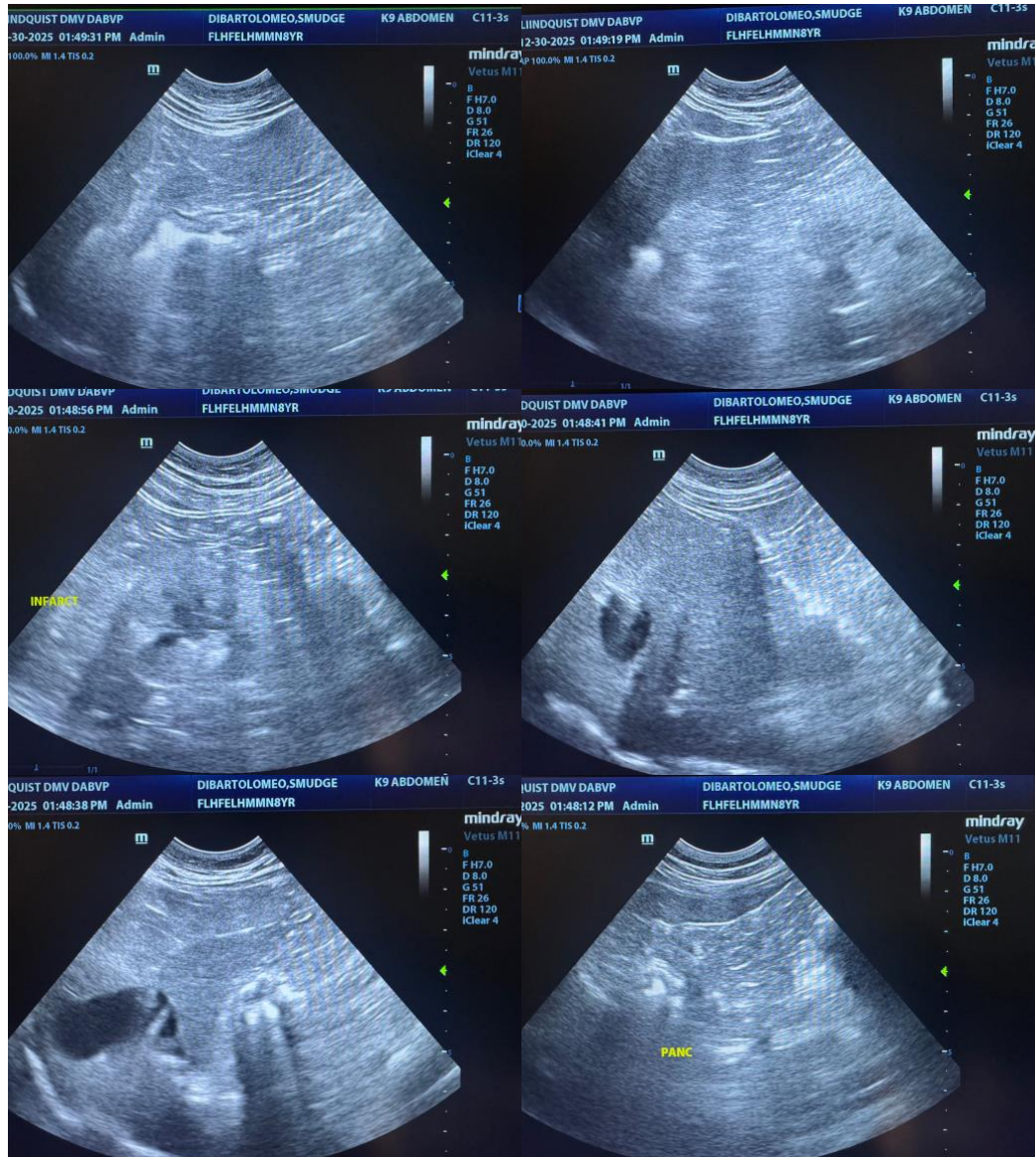
Dr. Zilberman

**INVOICE**

35137

**DATE**

12/30/25





**PATIENT**

Smudge Dibartolomeo

**SPECIES**

Feline

**BREED**

Himalayan

**SEX**

Neutered Male

**AGE**

8

**WEIGHT**

18.3 Pounds

**INTERPRETED BY**

Eric Lindquist, DMV,  
 DABVP (CFM), Cert.  
 IVUSS

**IMAGING PERFORMED BY**

Eric Lindquist, DMV,  
 DABVP (CFM), Cert.  
 IVUSS

**HOSPITAL NAME**

Franklin Lakes AH

**REFERRING VET**

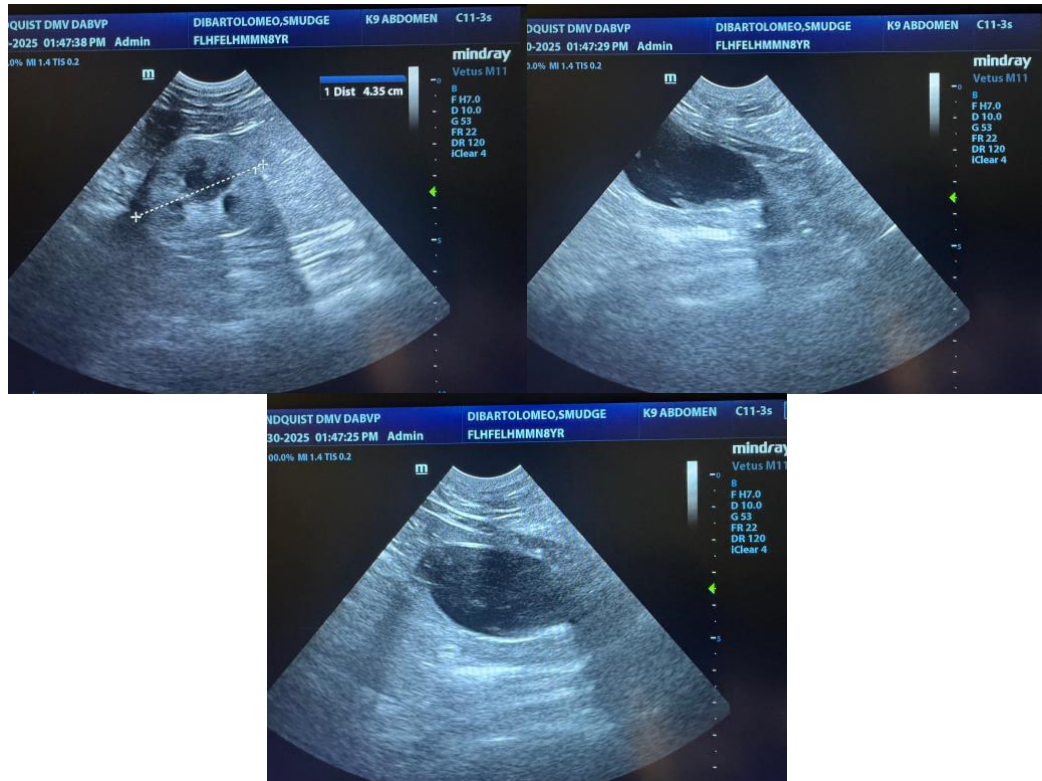
Dr. Zilberman

**INVOICE**

35137

**DATE**

12/30/25



**The information and recommendations provided are based on the images presented by the referring veterinarian/sonographer. No evaluation can be communicated regarding pathology that was not visible in the image/video clips provided.**

Thank you for this referral. If the clinical or image interpretation does not parallel your findings or if I can be of any further assistance please contact me.

**Eric Lindquist**, DMV, DABVP(CFM), Cert. IVUSS,  
 CEO, Owner, Founder -- SonoPath.com  
[info@SonoPath.com](mailto:info@SonoPath.com)