



PATIENT

Roxy Rago

SPECIES

Canine

BREED

Boxer

SEX

Spayed female

AGE

6 years

WEIGHT

68 lbs

INTERPRETED BY

Eric Lindquist, DMV
DABVP, Cert. IVUSS

IMAGING PERFORMED BY

Jenn

HOSPITAL NAME

Rockaway AH

REFERRING VET

Dr. Maniar

INVOICE

69653

DATE

12/30/25

PRESENTING CLINICAL SIGNS

History: recheck from 12/2 LE are now higher and Lipase is elevated
Abnormal PE/Chem/CBC/UA Results: WBC 19.25 ALT 218 ALP >2,000 Lipase 1717

ULTRASONOGRAPHIC EXAMINATION OF THE ABDOMEN

Urinary System

The **urinary bladder**, trigone, and pelvic urethra presented normal thicknesses and normal tone. The pelvic urethra was imaged 2.0 cm beyond the cystourethral junction and appeared normal. The ureters were not visible which is normal. No uroliths or sediment were visualized and anechoic urine was present. No evidence of inflammatory or neoplastic changes was noted. Ureteral papillae were normal.

The **left kidney** revealed normal size and structure, corticomedullary definition and ratio for this age. The cortices presented largely uniform texture with normal echogenic relationship to liver and spleen. Medullary structure differed distinctly from the cortex and no evidence of pelvic dilation was present. The capsule was acceptably uniform without significant irregularities. The left kidney measured 6.07 cm.

The **right kidney** revealed slight, irregular, dorsal contour measuring 6.8 cm in length. The right kidney also revealed a cortical infarct. Areas of mineralization were noted and slight pyelectasia.

Adrenal Glands

The **left adrenal gland** was visualized and recognized as having normal shape, size, position and echogenicity for this breed. The phrenic vasculature, glandular echogenicity and detail were unremarkable. Capsule, cortex, and medullary definition were normal for this age patient. The left adrenal gland measured 2.4 x 0.57 cm at the caudal pole and 0.63 cm at the cranial pole.

The **region of the right adrenal gland** was imaged with no evidence of pathology.

Spleen

The **spleen** presented a smooth homogeneous parenchyma hyperechoic to liver and renal cortical parenchyma. The capsule was smooth without noticeable expansion or deviation from within the spleen or adjacent pathology. The splenic vasculature demonstrated normal volume without signs of congestion or thrombosis. No sonographic evidence of acute or chronic inflammatory, neoplastic, or infarctual changes was noted.

Liver

The **liver** images submitted revealed subjectively normal liver size, contour, and structure. Parenchymal echogenicity was naturally coarse and hypoechoic to the spleen. Vascular and biliary tracts were of



PATIENT

Roxy Rago

SPECIES

Canine

BREED

Boxer

SEX

Spayed female

AGE

6 years

WEIGHT

68 lbs

INTERPRETED BY

Eric Lindquist, DMV
DABVP, Cert. IVUSS

IMAGING PERFORMED BY

Jenn

HOSPITAL NAME

Rockaway AH

REFERRING VET

Dr. Maniar

INVOICE

69653

DATE

12/30/25

normal volume with no evidence of congestion. The gallbladder presented acceptably thin walls with primarily anechoic content. The cystic and common bile ducts were normal. No pathological hepatic lymphadenopathy was evident. No overt structural evidence of inflammatory, infiltrative or regenerative pathology was evident.

Gastrointestinal

A minor amount of non-shadowing, non-obstructive ingesta was noted in the **stomach**. Transit of chyme into the small intestine was normal. Curvilinear patterns were maintained throughout the GI tract. No evidence of pathology. Small and large intestine demonstrated normal luminal chyme and stool consistency respectively. No obstructive or overt infiltrative disease was noted. No associated abnormal lymphatic activity was noted.

Pancreas

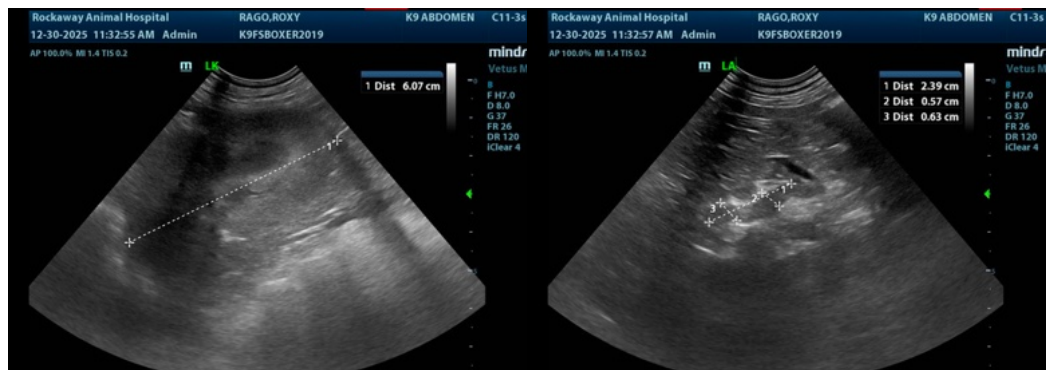
The base and limbs of the **pancreas** were observed to be largely isoechoic to surrounding omental fat. Pancreatic duct and capsular contour were acceptably normal and parenchyma respected normal curvilinear patterns. No overt evidence of active inflammatory or neoplastic disease was noted.

ULTRASONOGRAPHIC FINDINGS

- Structurally unremarkable abdomen other than a very full stomach.
- Moderate degenerative renal changes.
- Irregular contour to the right kidney is likely owing to infarcts.

INTERPRETATION OF THE FINDINGS & FURTHER RECOMMENDATIONS

The material in the stomach was progressively shadowing. If the patient was not post prandial, then retention of ingesta or soft foreign matter is possible in the stomach. Urinary work-up is warranted as well as blood pressure measurements if not already performed. There was no evidence of neoplasia.





PATIENT

Roxy Rago

SPECIES

Canine

BREED

Boxer

SEX

Spayed female

AGE

6 years

WEIGHT

68 lbs

INTERPRETED BY

Eric Lindquist, DMV
DABVP, Cert. IVUS

**IMAGING
PERFORMED BY**

Jenn

HOSPITAL NAME

Rockaway AH

REFERRING VET

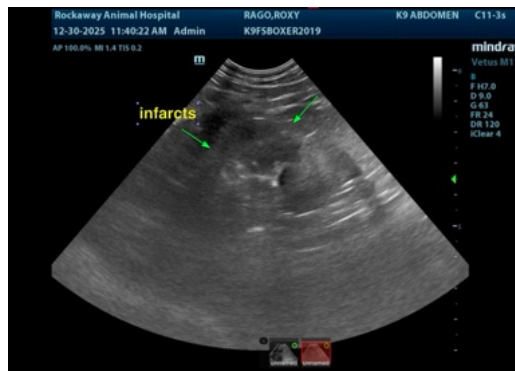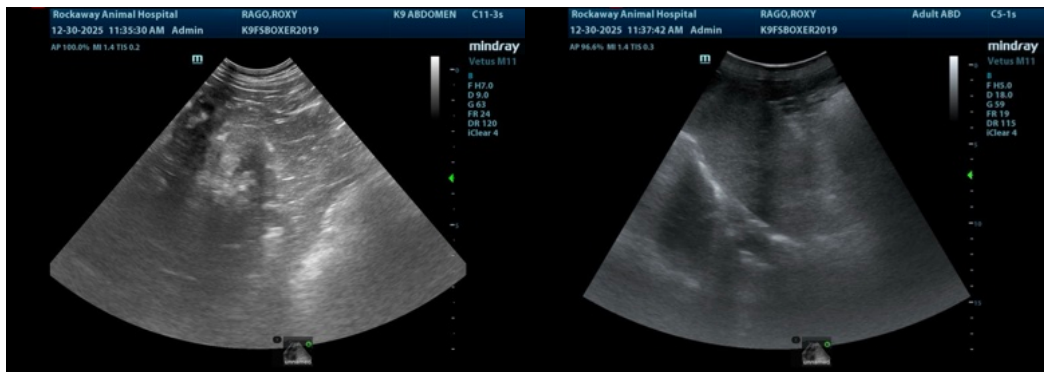
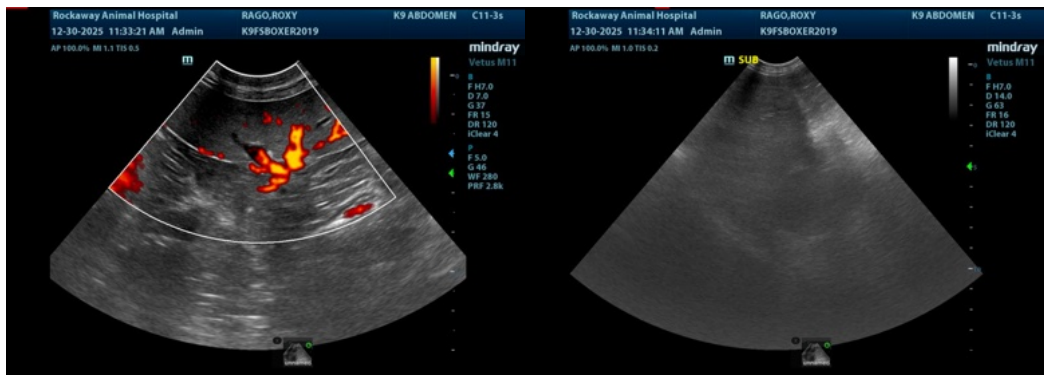
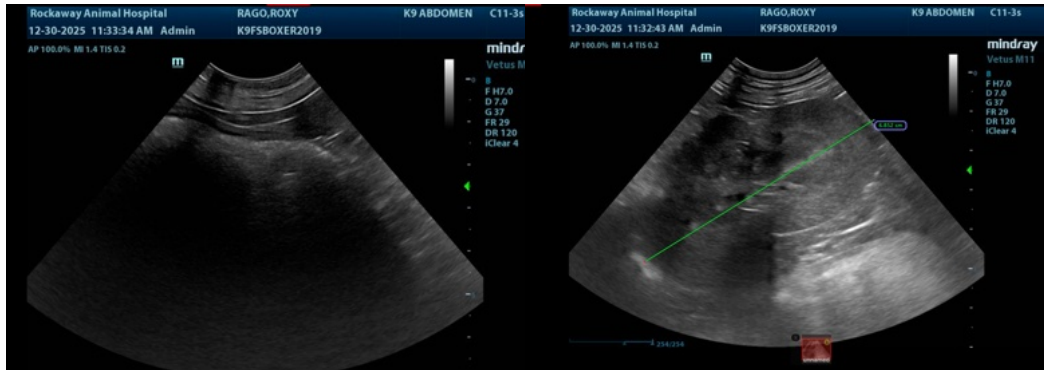
Dr. Maniar

INVOICE

69653

DATE

12/30/25





PATIENT

Roxy Rago

SPECIES

Canine

BREED

Boxer

SEX

Spayed female

AGE

6 years

WEIGHT

68 lbs

INTERPRETED BY

Eric Lindquist, DMV
DABVP, Cert. IVUSS

IMAGING PERFORMED BY

Jenn

HOSPITAL NAME

Rockaway AH

REFERRING VET

Dr. Maniar

INVOICE

69653

DATE

12/30/25

The information and recommendations provided are based on the images presented by the referring veterinarian/sonographer. No evaluation can be communicated regarding pathology that was not visible in the image/video clips provided.

Thank you for this referral. If the clinical or image interpretation does not parallel your findings or if I can be of any further assistance please contact me.

Eric Lindquist, DMV, DABVP, Cert. IVUSS, CEO of SonoPath.com

info@SonoPath.com