



**PATIENT**

Lucas Pizappi

**SPECIES**

Canine

**BREED**

Chihuahua

**SEX**

Neutered Male

**AGE**

14 Years 2 Months

**WEIGHT**

14.6 pounds

**INTERPRETED BY**

Eric Lindquist, DMV,  
DABVP(CFM), Cert.  
IVUSS

**IMAGING PERFORMED BY**

Eric Lindquist, DMV,  
DABVP(CFM), Cert.  
IVUSS

**HOSPITAL NAME**

Greenwood Lake  
Animal Hospital

**REFERRING VET**

Dr. Panchal

**INVOICE**

12884

**DATE**

12/30/25

**PRESENTING CLINICAL SIGNS**

Grade 4/6 murmur PU/PD. The patient is overweight.

Current medications: Joint supplement.

LDDST was not supportive of Cushing's. ↑ ALT 546 ↑ ALP 2614 ↑ GG 20

**ULTRASONOGRAPHIC EXAMINATION OF THE HEART**

CANINE CARDIAC PARAMETERS	MR VMAX (m/s)	TR VMAX (m/s)	LA/AO (M-Mode)	LA/AO (Heart Base; Swe)	FS (%)	EF (%)	EPSS (cm)
NORMAL PARAMETER	4.5-5.5	<2.7	1.3	Up to 1.6	28-40	40-100	<0.6
PATIENT	6.0	2.86	1.3	1.1	48	82	0.1
CANINE CARDIAC PARAMETERS	HR (BPM)	AV VMAX (m/s)	PV MAX (m/s)	BODY WEIGHT (kg)	LAD LA MAX 4 Chamber	LVIDd Avg; 2D and m-mode short axis (cm)	LVIDs Avg; 2D and m-mode short axis (cm)
NORMAL PARAMETER	50-100	0.7-1.7	0.7-1.6				
PATIENT	--	1.7	1.0	--	2.14	2.16	--

**Cardiac Presentation**

The echocardiogram in this patient demonstrated normal **left atrial** size based on 3 different LA measurement methods. Chamber volumes and echogenicity were normal. The cranial and caudal **mitral** valve leaflets presented vegetative thickening consistent with endocardiosis. Doppler indicated measurable insufficiency. The **left ventricle** presented normal thicknesses with linear contour and was not dilated nor restricted. The **myocardium** presented normal echogenicity without subjective evidence of significant fibrotic or ischemic disease. **Contractility** of the ventricular walls was adequate and in normal range for this patient evidenced by the fractional shortening measurement and subjective evaluation of the different regions of the myocardium. The **left ventricular outflow** tract demonstrated normal laminar flow and subjective structural integrity. The **right atrium** and auricle revealed normal size, structure and content. No evidence of masses was noted or chamber overload. **Tricuspid** valvular assessment demonstrated adequate linear morphology. The **right ventricle** was of normal size (1/3 diameter of LV), chordae structure, myocardial echogenicity and thickness. **Pulmonic** tract assessment revealed normal valve structure, laminar flow, and diameter (approx.1:1 pa/ao ratio). No visible **pericardial** or free pleura fluid was noted. No echographically detectable evidence of infiltrative disease was visible. The cranial **mediastinum and pericardial regions** were free of masses in the visible window.

**ULTRASONOGRAPHIC FINDINGS**



**PATIENT**

- Stage B1 valvular disease.

Lucas Pizappi

**INTERPRETATION OF THE FINDINGS & FURTHER RECOMMENDATIONS**

**SPECIES**

The heart is stable without clinical disease. No overt contraindication for anesthesia of brief to moderate duration. I suggest Torbutrol premed, Propofol induction, Isoflor maintenance or similar protocol if anesthesia is desired. Blood pressure, EKG and chest radiographs are recommended if not already performed. Target white coat negative systolic pressure of < 160 mmHg. If higher than this ACE-inhibitor is suggested to reach this level. Recheck echocardiogram is recommended in 6-12 months, earlier if murmur grade increases or clinical signs initiate.

Canine

**BREED**

Chihuahua

**SEX**

Neutered Male

**AGE**

14 Years 2 Months

**WEIGHT**

14.6 pounds

**INTERPRETED BY**

Eric Lindquist, DMV,  
 DABVP(CFM), Cert.  
 IVUSS

**IMAGING PERFORMED BY**

Eric Lindquist, DMV,  
 DABVP(CFM), Cert.  
 IVUSS

**HOSPITAL NAME**

Greenwood Lake  
 Animal Hospital

**REFERRING VET**

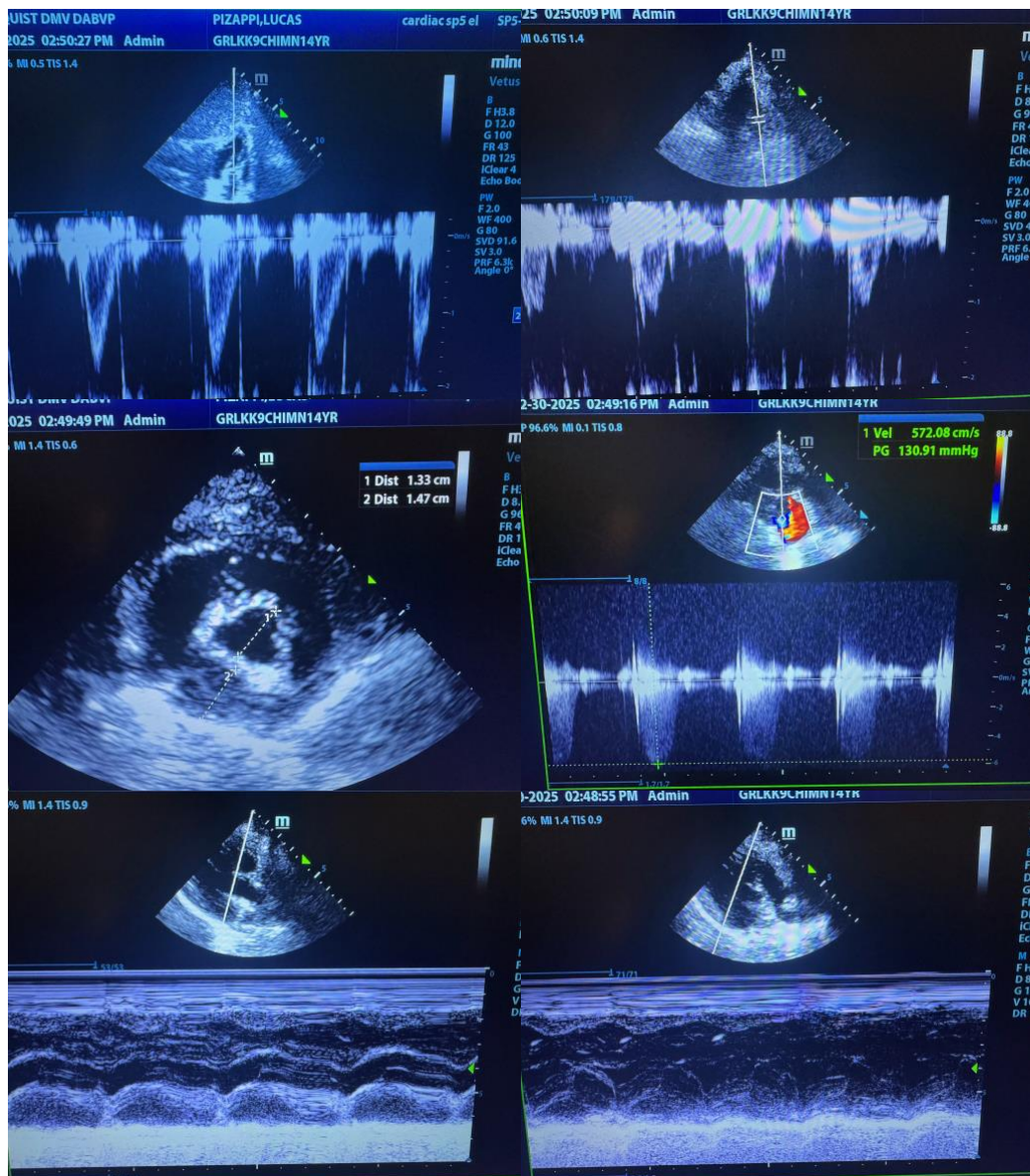
Dr. Panchal

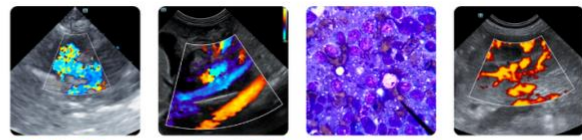
**INVOICE**

12884

**DATE**

12/30/25





**PATIENT**

Lucas Pizappi

**SPECIES**

Canine

**BREED**

Chihuahua

**SEX**

Neutered Male

**AGE**

14 Years 2 Months

**WEIGHT**

14.6 pounds

**INTERPRETED BY**

Eric Lindquist, DMV,  
 DABVP(CFM), Cert.  
 IVUSS

**IMAGING PERFORMED BY**

Eric Lindquist, DMV,  
 DABVP(CFM), Cert.  
 IVUSS

**HOSPITAL NAME**

Greenwood Lake  
 Animal Hospital

**REFERRING VET**

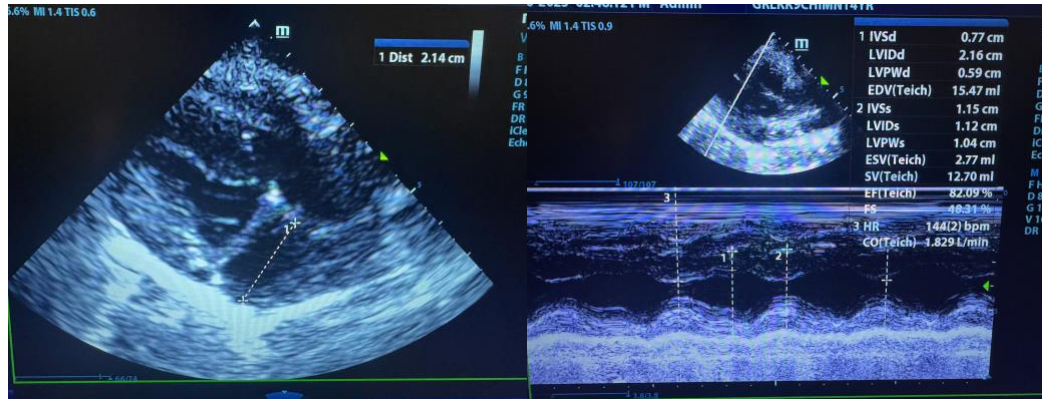
Dr. Panchal

**INVOICE**

12884

**DATE**

12/30/25



The information and recommendations provided are based on the images presented by the referring veterinarian/sonographer. No evaluation can be communicated regarding pathology that was not visible in the image/video clips provided.

Thank you for this referral. If the clinical or image interpretation does not parallel your findings or if I can be of any further assistance, please contact me.

**Eric Lindquist, DMV, DABVP(CFM), Cert. IVUSS,**

CEO, Owner, Founder -- SonoPath.com

[info@SonoPath.com](mailto:info@SonoPath.com)