



**PATIENT**

Hercules Amico

**SPECIES**

Canine

**BREED**

Morkie

**SEX**

Neutered Male

**AGE**

11 Years

**WEIGHT**

9 Pounds

**INTERPRETED BY**

Eric Lindquist, DMV,  
DABVP (CFM), Cert.  
IVUSS

**IMAGING PERFORMED BY**

Eric Lindquist, DMV,  
DABVP (CFM), Cert.  
IVUSS

**HOSPITAL NAME**

Franklin Lakes AH

**REFERRING VET**

Dr. Onesios/Dr. Ward

**INVOICE**

35140

**DATE**

12/30/25

**PRESENTING CLINICAL SIGNS**

History: hx of Intermittent GI Issues (diarrhea), recently ^ in frequency. Labs: NSF

**ULTRASONOGRAPHIC EXAMINATION OF THE ABDOMEN**

**Urinary System**

The **urinary bladder**, trigone, and pelvic urethra presented normal thicknesses and normal tone. The ureters were not visible which is normal. No uroliths or sediment were visualized and anechoic urine was present. No evidence of inflammatory or neoplastic changes was noted. Ureteral papillae were normal.

The **kidneys** revealed largely normal size and structure, corticomedullary definition and ratio (cortex 1/3 of medulla) were essentially maintained with some minor age-related loss of curvilinear patterns regarding the capsule and C/M junction. The cortices presented largely uniform texture with some increased echogenicity expected for this age patient. Medullary structure differed distinctly from that of the cortex, and no evidence of pelvic dilation was present. Mineralization was present in the kidneys. The left kidney measured 3.8 cm. The right kidney measured 4.05 cm.

**Adrenal Glands**

Both **adrenal glands** were visualized and recognized as having normal shape, size, position and echogenicity for this breed. The phrenic vasculature, glandular echogenicity and detail were unremarkable. Capsule, cortex, and medullary definition were normal for this age patient. The left adrenal gland measured 1.78 cm x 0.65 cm. The right adrenal gland measured 1.64 cm x 0.76 cm at the cranial pole and 0.55 cm at the caudal pole.

**Spleen**

The **spleen** presented a smooth homogeneous parenchyma hyperechoic to liver and renal cortical parenchyma. The capsule was smooth without noticeable expansion or deviation from within the spleen or adjacent pathology. The splenic vasculature demonstrated normal volume without signs of congestion or thrombosis. No sonographic evidence of acute or chronic inflammatory, neoplastic, or infarctual changes were noted.

**Liver**

The **liver** images submitted revealed subjectively normal liver size, contour, and structure. Parenchymal echogenicity was naturally coarse and hypoechoic to the spleen. Vascular and biliary tracts were of normal volume with no evidence of congestion. The gallbladder presented acceptably thin walls with primarily anechoic content. The cystic and common bile ducts were normal. No pathological hepatic lymphadenopathy was evident. No overt structural evidence of inflammatory, infiltrative or regenerative pathology was evident.

**Gastrointestinal**

Examination of the **gastrointestinal tract** revealed a stomach and intestine free of stasis, of normal wall thickness, acceptable curvilinear mural detail, and peristaltic activity. Small and large intestine



**PATIENT**

Hercules Amico

**SPECIES**

Canine

**BREED**

Morkie

**SEX**

Neutered Male

**AGE**

11 Years

**WEIGHT**

9 Pounds

**INTERPRETED BY**

Eric Lindquist, DMV,  
DABVP (CFM), Cert.  
IVUSS

**IMAGING PERFORMED BY**

Eric Lindquist, DMV,  
DABVP (CFM), Cert.  
IVUSS

**HOSPITAL NAME**

Franklin Lakes AH

**REFERRING VET**

Dr. Onesios/Dr. Ward

**INVOICE**

35140

**DATE**

12/30/25

demonstrated normal luminal chyme and stool consistency respectively. No obstructive or overt infiltrative disease was noted. No associated abnormal lymphatic activity was noted.

**Pancreas**

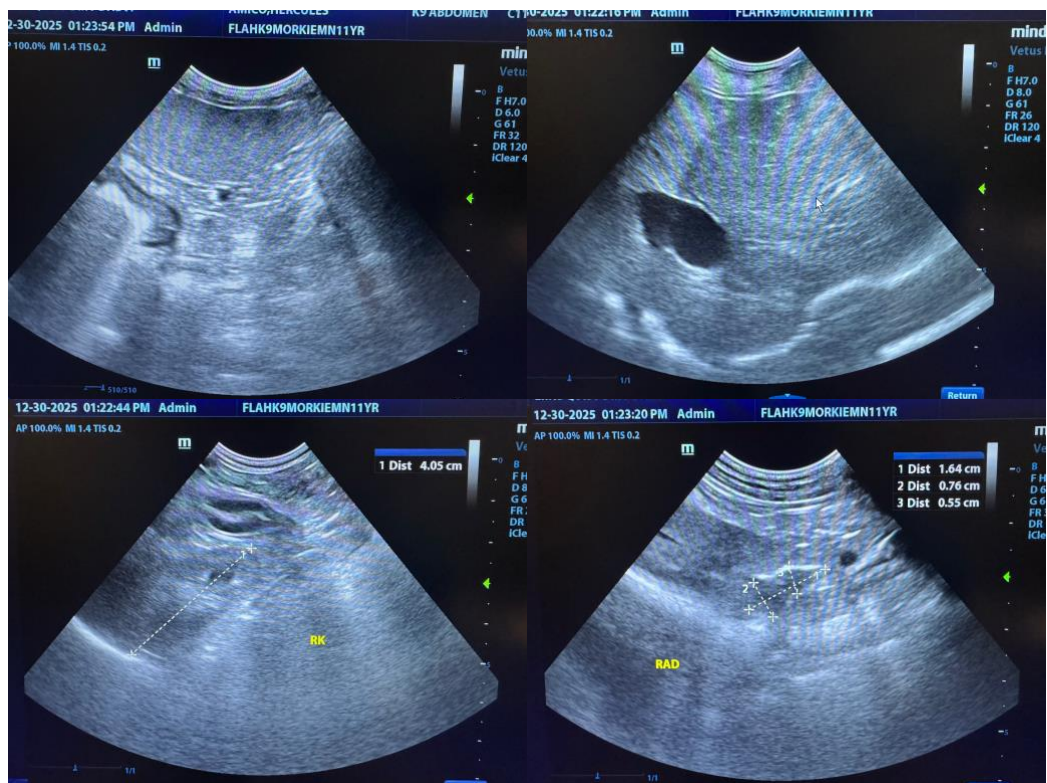
The base and limbs of the **pancreas** were observed to be largely isoechoic to surrounding omental fat. Some mild parenchymal remodeling, however, with mild deviation from curvilinear normalcy was observed. Pancreatic duct and capsular irregularities were present consistent with age related changes. If pain upon imaging (+ Murphy sign) was present or if the patient is focally painful in subxiphoid palpation, then low-grade smoldering chronic pancreatitis should be suspected.

**ULTRASONOGRAPHIC FINDINGS**

- Structurally unremarkable abdomen
- Age-related renal changes with mineralization
- Age-related pancreatic changes

**INTERPRETATION OF THE FINDINGS & FURTHER RECOMMENDATIONS**

No evidence of pathology. Dietary indiscretion, food intolerance, structurally insignificant inflammatory bowel or occult parasitism and occult Addison's are all potentials.





**PATIENT**

Hercules Amico

**SPECIES**

Canine

**BREED**

Morkie

**SEX**

Neutered Male

**AGE**

11 Years

**WEIGHT**

9 Pounds

**INTERPRETED BY**

Eric Lindquist, DMV,  
 DABVP (CFM), Cert.  
 IVUSS

**IMAGING PERFORMED BY**

Eric Lindquist, DMV,  
 DABVP (CFM), Cert.  
 IVUSS

**HOSPITAL NAME**

Franklin Lakes AH

**REFERRING VET**

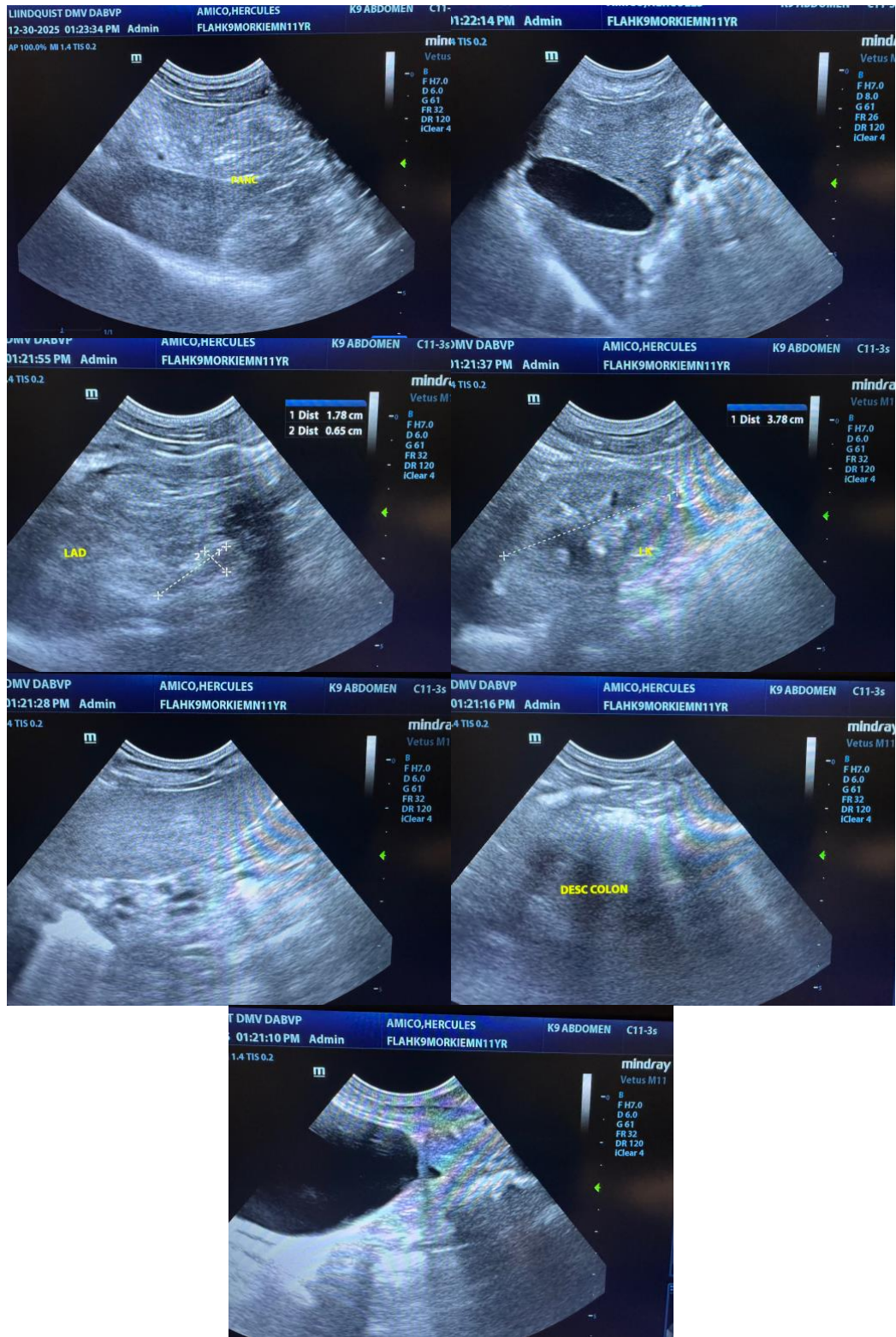
Dr. Onesios/Dr. Ward

**INVOICE**

35140

**DATE**

12/30/25





**PATIENT**

Hercules Amico

**SPECIES**

Canine

**BREED**

Morkie

**SEX**

Neutered Male

**AGE**

11 Years

**WEIGHT**

9 Pounds

**INTERPRETED BY**

Eric Lindquist, DMV,  
DABVP (CFM), Cert.  
IVUSS

**IMAGING  
PERFORMED BY**

Eric Lindquist, DMV,  
DABVP (CFM), Cert.  
IVUSS

**HOSPITAL NAME**

Franklin Lakes AH

**REFERRING VET**

Dr. Onesios/Dr. Ward

**INVOICE**

35140

**DATE**

12/30/25

**The information and recommendations provided are based on the images presented by the referring veterinarian/sonographer. No evaluation can be communicated regarding pathology that was not visible in the image/video clips provided.**

Thank you for this referral. If the clinical or image interpretation does not parallel your findings or if I can be of any further assistance please contact me.

**Eric Lindquist**, DMV, DABVP(CFM), Cert. IVUSS,  
CEO, Owner, Founder -- SonoPath.com  
[info@SonoPath.com](mailto:info@SonoPath.com)