



PATIENT

Guinness Hobbs

SPECIES

Canine

BREED

Labrador Retriever

SEX

Spayed female

AGE

9 years

WEIGHT

73 lbs

INTERPRETED BY

Eric Lindquist, DMV
DABVP, Cert. IVUSS

IMAGING PERFORMED BY

Jessica Bailes

HOSPITAL NAME

All Creatures Great
and Small Corvallis

REFERRING VET

Dr. Sadhiro

INVOICE

69722

DATE

12/30/25

PRESENTING CLINICAL SIGNS

History: Diagnosed w/ SQ hemangiosarcoma originating from R hock. Wanting to screen for mets prior to considering amputation

Abnormal PE/Chem/CBC/UA Results: Firm irregular rapidly growing SQ mass originating from R hock, otherwise NSF on exam Previous BW WNL Thoracic rads taken today: NSF - no metastatic pulmonary lesions noted

ULTRASONOGRAPHIC EXAMINATION OF THE ABDOMEN

Urinary System

The **urinary bladder**, trigone, and pelvic urethra presented normal thicknesses and normal tone. The ureters were not visible which is normal. No uroliths or sediment were visualized and anechoic urine was present. No evidence of inflammatory or neoplastic changes was noted. Ureteral papillae were normal.

The **kidneys** revealed normal size and structure, corticomedullary definition and ratio for this age. The cortices presented largely uniform texture with normal echogenic relationship to liver and spleen. Medullary structure differed distinctly from the cortex and no evidence of pelvic dilation was present. The capsules were acceptably uniform without significant irregularities. Slight pinpoint mineralization was noted. The right kidney measured 6.38 cm. The left kidney measured 6.46 cm.

The iliac trifurcation was unremarkable with no evidence of metastatic disease.

Adrenal Glands

Both **adrenal glands** were visualized and recognized as having normal shape, size, position and echogenicity for this breed. The phrenic vasculature, glandular echogenicity and detail were unremarkable. Capsule, cortex, and medullary definition were normal for this age patient. The left adrenal gland measured 2.02 x 0.54 cm at the cranial pole and 0.59 cm at the caudal pole. The right adrenal gland measured 2.0 x 0.44 cm at the cranial pole and 0.56 cm at the caudal pole.

Spleen

The **spleen** presented a smooth homogeneous parenchyma hyperechoic to liver and renal cortical parenchyma. The capsule was smooth without noticeable expansion or deviation from within the spleen or adjacent pathology. The splenic vasculature demonstrated normal volume without signs of congestion or thrombosis. No sonographic evidence of acute or chronic inflammatory, neoplastic, or infarctual changes was noted.

Liver

The **liver** images from right and left intercostal as well as subcostal views revealed subjectively normal liver size, contour, and structure. Some age-related parenchymal remodeling was noted but likely not clinically significant at this time. Vascular and biliary tracts were of normal volume and no evidence of



PATIENT

Guinness Hobbs

SPECIES

Canine

BREED

Labrador Retriever

SEX

Spayed female

AGE

9 years

WEIGHT

73 lbs

INTERPRETED BY

Eric Lindquist, DMV
DABVP, Cert. IVUSS

IMAGING PERFORMED BY

Jessica Bailes

HOSPITAL NAME

All Creatures Great
and Small Corvallis

REFERRING VET

Dr. Sadhiro

INVOICE

69722

DATE

12/30/25

congestion was noted. The gallbladder presented some dependent debris with essentially normal contour. The cystic and common bile ducts were normal. No overt evidence of active inflammatory, infiltrative or regenerative pathology was noted but should be paired with current or past LE elevations regarding any clinical significance to this presentation. The hepatic lymph nodes were unremarkable.

Gastrointestinal

There was some residual chyme and gas was noted in the **stomach**, yet not pathological. This is consistent with post prandial presentation. Transit of chyme into the small intestine was normal. Curvilinear patterns were maintained throughout the GI tract. No evidence of pathology. Small and large intestine demonstrated normal luminal chyme and stool consistency respectively. No obstructive or overt infiltrative disease was noted. No associated abnormal lymphatic activity was noted.

Pancreas

The base and limbs of the **pancreas** were observed to be largely isoechoic to surrounding omental fat. Pancreatic duct and capsular contour were acceptably normal and parenchyma respected normal curvilinear patterns. No overt evidence of active inflammatory or neoplastic disease was noted.

Heart

Rapid view of the heart revealed no evidence of pathology in the right auricle or pericardium. Contractility and volumes were normal.

ULTRASONOGRAPHIC FINDINGS

Unremarkable abdomen.

Minor renal mineralization.

INTERPRETATION OF THE FINDINGS & FURTHER RECOMMENDATIONS

There was no evidence of metastatic disease.



PATIENT

Guinness Hobbs

SPECIES

Canine

BREED

Labrador Retriever

SEX

Spayed female

AGE

9 years

WEIGHT

73 lbs

INTERPRETED BY

Eric Lindquist, DMV
DABVP, Cert. IVUSS

IMAGING PERFORMED BY

Jessica Bailes

HOSPITAL NAME

All Creatures Great and Small Corvallis

REFERRING VET

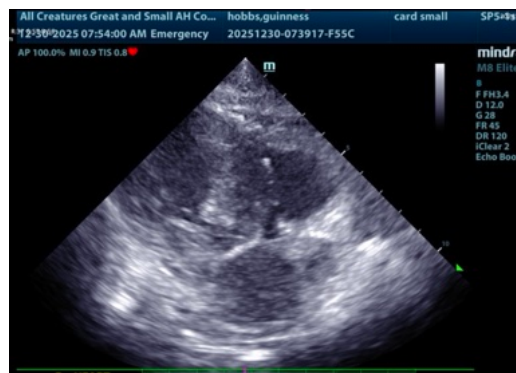
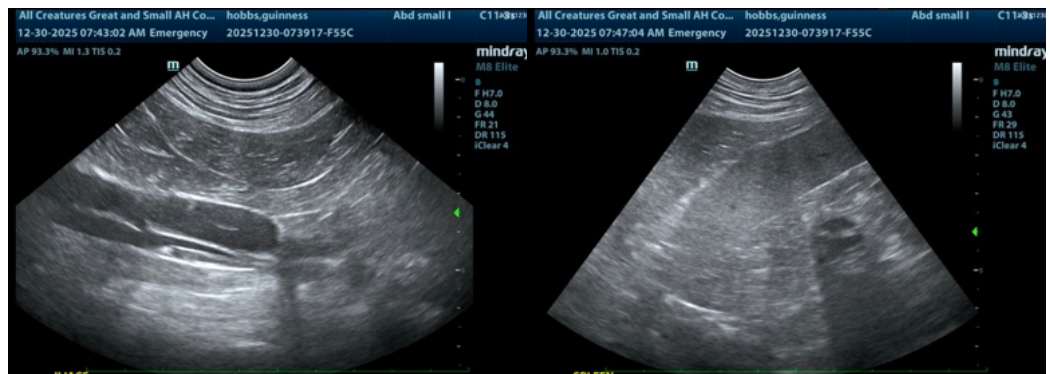
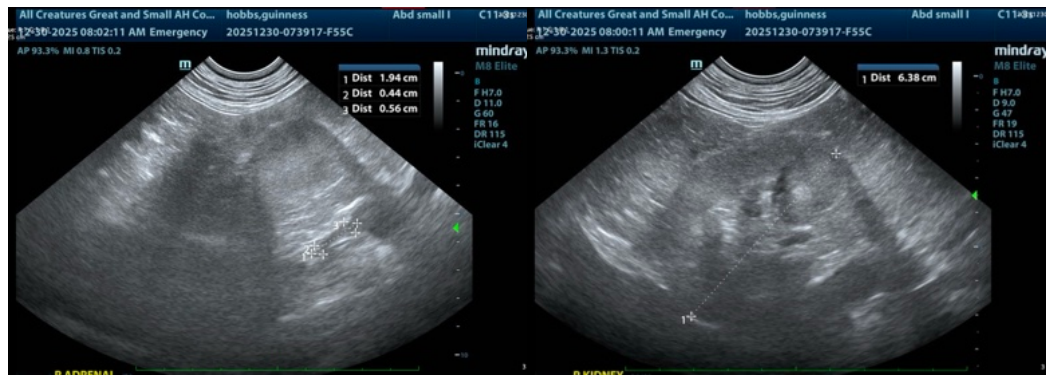
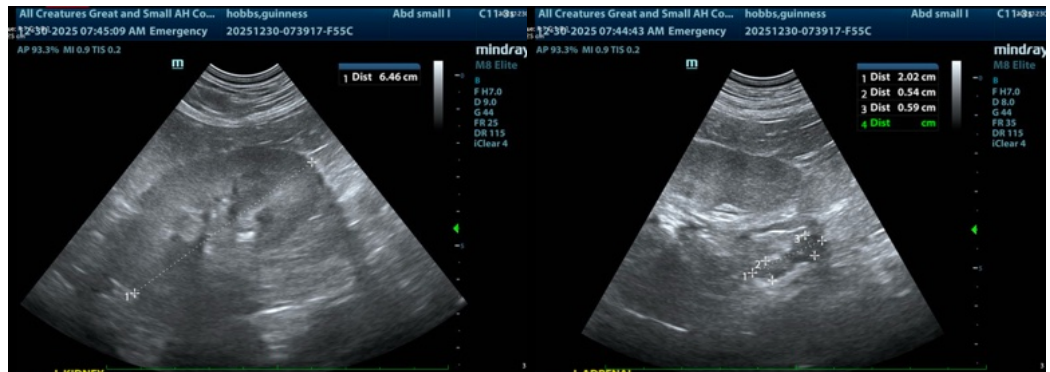Dr. Sadhiro

INVOICE

69722

DATE

12/30/25





PATIENT

Guinness Hobbs

SPECIES

Canine

BREED

Labrador Retriever

SEX

Spayed female

AGE

9 years

WEIGHT

73 lbs

INTERPRETED BY

Eric Lindquist, DMV
DABVP, Cert. IVUSS

IMAGING PERFORMED BY

Jessica Bailes

HOSPITAL NAME

All Creatures Great
and Small Corvallis

REFERRING VET

Dr. Sadhiro

INVOICE

69722

DATE

12/30/25

The information and recommendations provided are based on the images presented by the referring veterinarian/sonographer. No evaluation can be communicated regarding pathology that was not visible in the image/video clips provided.

Thank you for this referral. If the clinical or image interpretation does not parallel your findings or if I can be of any further assistance please contact me.

Eric Lindquist, DMV, DABVP (CFM), Cert. IVUSS, CEO of SonoPath.com

info@SonoPath.com