



PATIENT

Annie Barrington

SPECIES

Canine

BREED

Mixed

SEX

Spayed Female

AGE

10 Years

WEIGHT

63.5 lbs

INTERPRETED BY

Eric Lindquist, DMV,
DABVP (CFM), Cert.
IVUSS

IMAGING PERFORMED BY

Vincent Ravancho, CVT

HOSPITAL NAME

North Jersey Animal
Hospital

REFERRING VET

Dr. Hansen

INVOICE

72871

DATE

12/30/25

PRESENTING CLINICAL SIGNS

Hematuria, Hypostenuria. Blood visible in snow by O Clinical findings: retracted vulva Current medications: Proin 50mg PO SID

Abnormal PE/Chem/CBC/UA Results: U/A: PH 8.0 Blood 2+ WBC 2-5 Neg C+S USG 1.007

ULTRASONOGRAPHIC EXAMINATION OF THE ABDOMEN

Urinary System

The **urinary bladder**, trigone, and pelvic urethra presented normal thicknesses and normal tone. The ureters were not visible which is normal. No uroliths or sediment were visualized and anechoic urine was present. No evidence of inflammatory or neoplastic changes were noted. Ureteral papillae were normal. The pelvic urethra was imaged 2.0 cm beyond the cystourethral junction.

The **kidneys** revealed largely normal size and structure, corticomedullary definition and ratio (cortex 1/3 of medulla) were essentially maintained with some age-related loss of curvilinear patterns regarding the capsule and C/M junction. The cortices presented largely uniform texture with some increased echogenicity expected for his age patient. Medullary structure differed distinctly from that of the cortex and no evidence of pelvic dilation was present. Left kidney measured 6.77 cm. Right kidney measured 6.15 cm.

Adrenal Glands

Both **adrenal glands** were visualized and recognized as having normal shape, size, position and echogenicity for this breed. The phrenic vasculature, glandular echogenicity and detail were unremarkable. Capsule, cortex, and medullary definition were normal for this age patient. Left measured 2.03 cm x 0.66 cm at the cranial pole and 0.38 cm at the caudal pole. Right measured 0.60 cm in width.

Spleen

The **spleen** was largely smooth with subtle heterogeneous parenchymal changes while maintaining normal echogenic relationship to the liver and kidney. These changes are consistent with normal age-related alteration. The capsule was smooth without noticeable impingement from within the spleen or from pathology in the adjacent abdomen. The splenic vasculature demonstrated normal volume without signs of congestion or significant contraction. No evidence of active acute or chronic inflammatory, neoplastic, or infarctual changes were noted.

Liver

The **liver** images from right and left intercostal as well as subcostal views revealed subjectively normal liver size, contour, and structure. Some age-related parenchymal remodeling was noted but likely not clinically significant at this time. Vascular and biliary tracts were of normal volume and no evidence of congestion was noted. The gallbladder presented some dependent debris with essentially normal contour. The cystic and common bile ducts were normal. No overt evidence of active inflammatory, infiltrative or regenerative pathology was noted but should be paired with current or past LE elevations regarding any clinical significance to this presentation. The hepatic lymph nodes were unremarkable.



PATIENT

Annie Barrington

SPECIES

Canine

BREED

Mixed

SEX

Spayed Female

AGE

10 Years

WEIGHT

63.5 lbs

INTERPRETED BY

Eric Lindquist, DMV,
DABVP (CFM), Cert.
IVUSS

IMAGING PERFORMED BY

Vincent Ravancho, CVT

HOSPITAL NAME

North Jersey Animal
Hospital

REFERRING VET

Dr. Hansen

INVOICE

72871

DATE

12/30/25

Gastrointestinal

Examination of the **gastrointestinal tract** revealed a stomach and intestine free of stasis, of normal wall thickness, acceptable curvilinear mural detail, and peristaltic activity. Small and large intestine demonstrated normal luminal chyme and stool consistency respectively. No obstructive or overt infiltrative disease was noted. No associated abnormal lymphatic activity was noted.

Pancreas

The base and limbs of the **pancreas** were observed to be largely isoechoic to surrounding omental fat. Pancreatic duct and capsular contour were acceptably normal and parenchyma respected normal curvilinear patterns. No overt evidence of active inflammatory or neoplastic disease was noted.

ULTRASONOGRAPHIC FINDINGS

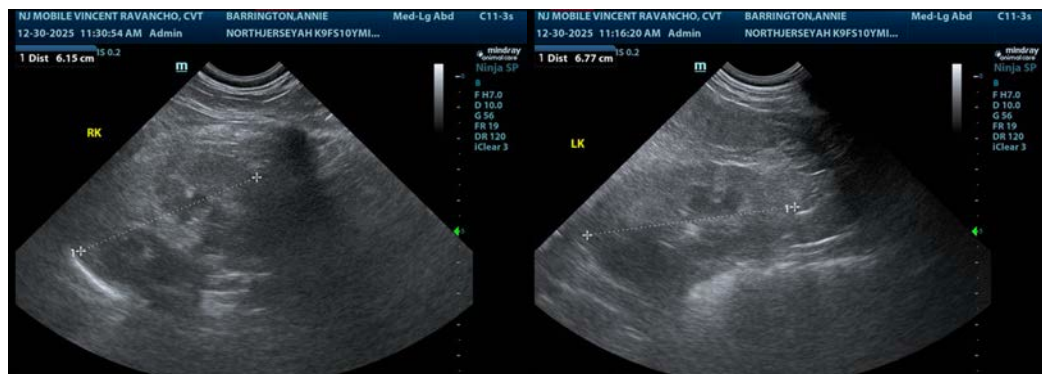
- Age related renal, splenic, and hepatic changes.

INTERPRETATION OF THE FINDINGS & FURTHER RECOMMENDATIONS

The cause of the urinary signs is unclear. Given the mildly elevated white count in the urine despite hyposthenuria, occult UTI with E.coli or similar, an ADH receptor inhibition may be an issue/medullary washout. Recommend antibiotic trial with Enrofloxacin or similar and reassessment of the urinalysis after 7-10 days. No other evidence of disease in the abdomen responsible for the clinical history. Urine culture and sensitivity could be considered. However, washout effect may affect an effective culture.

For an additional charge an internal medicine consult can be utilized through [Sonopath.com](http://sonopath.com). You can select the internal medicine drop down at <http://spa.sonopath.com/>.

One of the world's top internists & SonoPath associate Dr. Remo Lobetti BVSc, MMedVet, PhD, DECVIM can evaluate your case through SonoPath. <https://sonopath.com/resources/sonopath-services/internal-medicine-teleconsultation-services>





PATIENT

Annie Barrington

SPECIES

Canine

BREED

Mixed

SEX

Spayed Female

AGE

10 Years

WEIGHT

63.5 lbs

INTERPRETED BY

Eric Lindquist, DMV,
DABVP (CFM), Cert.
IVUSS

IMAGING PERFORMED BY

Vincent Ravancho, CVT

HOSPITAL NAME

North Jersey Animal
Hospital

REFERRING VET

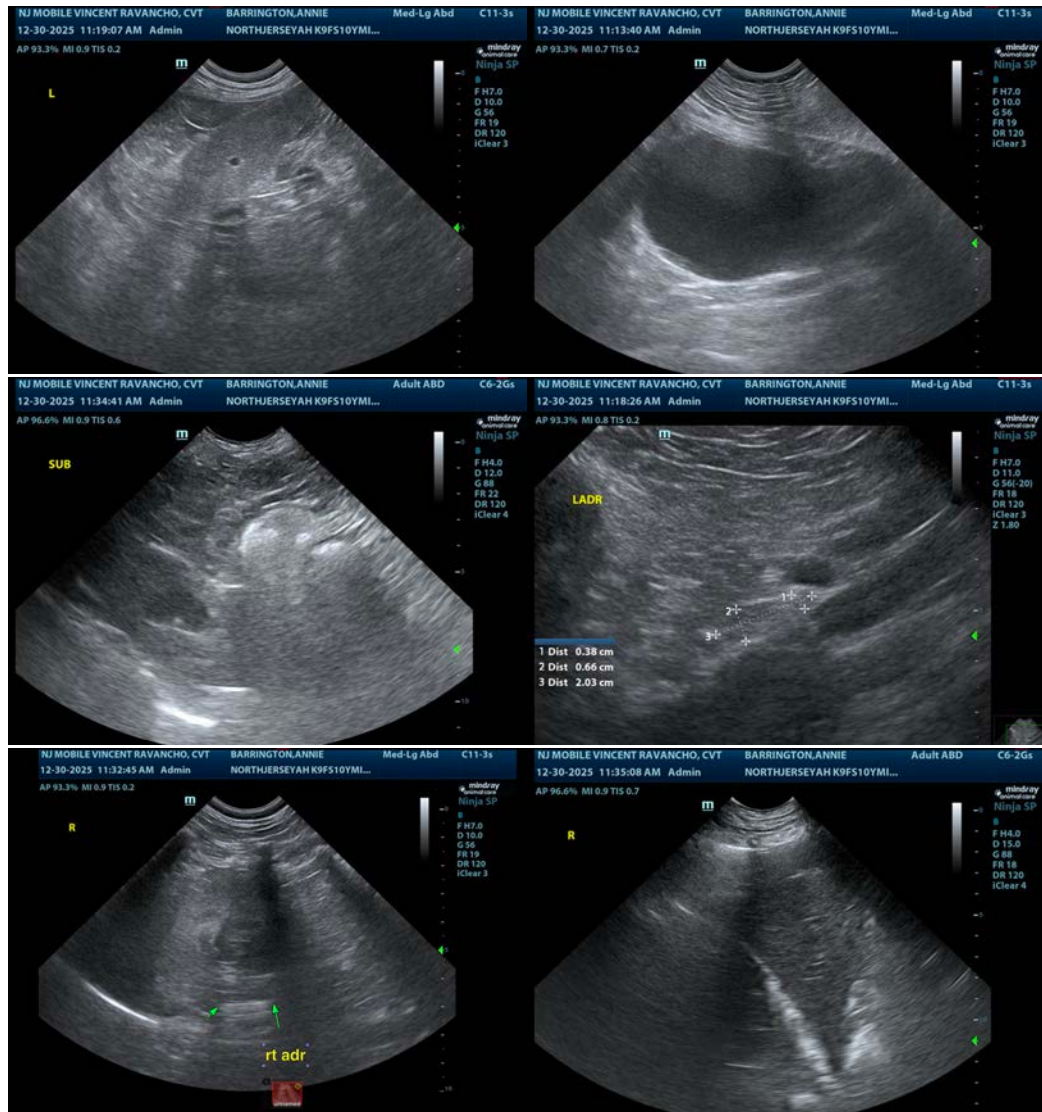
Dr. Hansen

INVOICE

72871

DATE

12/30/25



The information and recommendations provided are based on the images presented by the referring veterinarian/sonographer. No evaluation can be communicated regarding pathology that was not visible in the image/video clips provided.

Thank you for this referral. If the clinical or image interpretation does not parallel your findings or if I can be of any further assistance please contact me.

Eric Lindquist, DMV, DABVP(CFM), Cert. IVUSS,
CEO, Owner, Founder -- SonoPath.com
info@SonoPath.com



PATIENT

Annie Barrington

SPECIES

Canine

BREED

Mixed

SEX

Spayed Female

AGE

10 Years

WEIGHT

63.5 lbs

INTERPRETED BY

Eric Lindquist, DMV,
DABVP (CFM), Cert.
IVUSS

IMAGING PERFORMED BY

Vincent Ravancho, CVT

HOSPITAL NAME

North Jersey Animal
Hospital

REFERRING VET


Dr. Hansen

INVOICE

72871

DATE

12/30/25



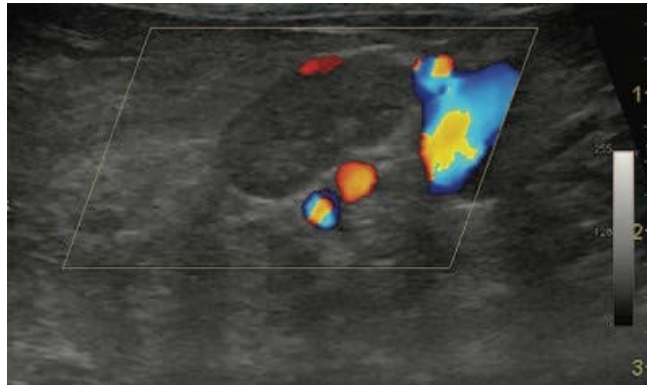
The following is an applicable excerpt from the *Curbside Guide to Diagnosis & Treatment of Sonographic Disease* offered by [SonoPath.com](http://sonopath.com) Lindquist, Frank, Lobetti, and Modler.

An essential quick guide for every general practitioner and sonographer.

<https://sonopath.com/products/curbside-guide-editing-due-release-12012015>

Polyuria and Polydipsia (PU/PD)

<http://www.sonopath.com/PUPD>



Long axis of the left adrenal gland in a cat with pituitary dependent hyperadrenocorticism and bilateral adrenal hyperplasia. There is mild increase in echogenicity and symmetrical enlargement with cranial and caudal pole heights of more than 5 mm. Note the Color Doppler signals are consistent with the phrenicoabdominal vessels and the junction of the renal vein and caudal vena cava.

Description: Polyuria and polydipsia (PU/PD) often occur together and are a common complaint in small animal practice. Given the many differential diagnoses for PU/PD and the diagnostic challenge associated with ruling in or out the various disease processes, one should follow a systematic approach when confronted with PU/PD cases. Causes can be categorized in two ways: 1) using an assessment of specific gravity, i.e., solute diuresis (specific gravity 1.008-1.024) and water diuresis (specific gravity 1.001-1.007); and 2) undertaking a clinical evaluation of diseases caused by primary renal disease or extrarenal causes of PU/PD. The following is a reference list of differential diagnoses one can use to categorize PU/PD according to renal or extrarenal disease:

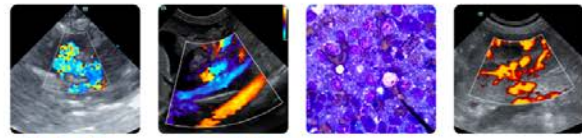
Renal disease

Extrarenal disease

Acute renal failure

Hyperadrenocorticism

Hypercalcemia



PATIENT

Annie Barrington

SPECIES

Canine

BREED

Mixed

SEX

Spayed Female

AGE

10 Years

WEIGHT

63.5 lbs

INTERPRETED BY

Eric Lindquist, DMV,
DABVP (CFM), Cert.
IVUSS

IMAGING PERFORMED BY

Vincent Ravancho, CVT

HOSPITAL NAME

North Jersey Animal
Hospital

REFERRING VET

Dr. Hansen

INVOICE

72871

DATE

12/30/25

Chronic renal failure

Glomerulonephritis

Primary glucosuria (Fanconi's)

Pyelonephritis

Nonazotemic renal disease

Leptospirosis

Hypoadrenocorticism

Diabetes Mellitus

Hyperthyroidism (cats)

Acromegaly

Pyometra

Postobstructive diuresis

Salt supplementation

Drugs (e.g. diuretics, prednisone)

Hypertension

Atypical Cushing's

Central diabetes insipidus

SARDS Nephrogenic diabetes insipidus

Medullary washout Psychogenic water intake

Hyponatremia

Hypokalemia

Liver failure

Pheochromocytoma

Polycythemia

Paraneoplastic

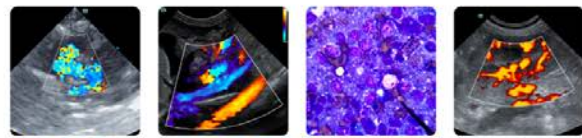
Pericardial effusion

A final diagnosis of psychogenic PU/PD is very rare and is always a diagnosis of exclusion.

Clinical Signs: Clinical signs include excessive thirst and urination. Whereas normal intake ranges from 60-80 ml/kg/day, excessive thirst is classified as drinking upwards of 100 ml/kg/day. Excessive urination is deemed to be a urine output greater than 50 ml/kg/day (normal output ranges from 20-40 ml/kg/day). The signs may manifest as abnormal intake behavior and even water seeking in profoundly polydipsic patients, as well as urinary accidents in the house.

Diagnostics: The diagnostic approach to PU/PD can be daunting given the large number of differentials listed above. First, one must evaluate signalment, patient history, and the results of a physical examination to determine clues to potential causes of PU/PD. For example, diabetes may be suspected in a middle- to older-aged dog experiencing weight loss and polyphagia, hyperthyroidism in older cats experiencing weight loss and polyphagia, and pyometra in intact female dogs and cats.

Prior to proceeding with expensive diagnostic tests, the presence of PU/PD should be confirmed by measuring water intake over a 2-3 day period at home. Urine specific gravity is also an important screening test as a concentrated urine sample rules out the presence of PU/PD.



PATIENT

Annie Barrington

SPECIES

Canine

BREED

Mixed

SEX

Spayed Female

AGE

10 Years

WEIGHT

63.5 lbs

INTERPRETED BY

Eric Lindquist, DMV,
DABVP (CFM), Cert.
IVUSS

IMAGING PERFORMED BY

Vincent Ravancho, CVT

HOSPITAL NAME

North Jersey Animal
Hospital

REFERRING VET

Dr. Hansen

INVOICE

72871

DATE

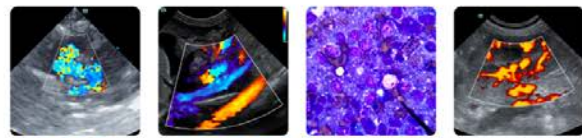
12/30/25

Basic workup: Many disease processes can be ruled out through basic blood work. The minimum database includes a CBC, biochemical profile, and urinalysis (UA). The UA is especially important for evaluating specific gravity, glucose or protein loss, and sediment that may indicate infection. A urine protein-creatinine (UP:C) and/or microalbumin test should be performed to assess for protein-losing nephropathy (PLE), especially in cases where the urine sample is not concentrated and a urine dipstick test may yield a false negative. One should take the systemic blood pressure to evaluate for hypertension. A urine culture should also be done to rule out infection and pyelonephritis, even if there is no evidence of the latter on the ultrasound. One may also consider a trial with antibiotics to see if the PU/PD resolves. It is also necessary to assess the total T4 and/or the free T4 in geriatric cats.

Abdominal ultrasound: The role of abdominal ultrasound is key in the diagnosis of PU/PD as it permits practitioners to evaluate the different organs for potential disease processes. For example, the kidneys can be evaluated for size, as they may be small in the face of chronic renal failure or normal to enlarged in cases of acute renal failure. The renal parenchymal echogenicity may be normal or increased in cases of renal disease, and a loss of corticomedullary distinction may also be present in such cases. Mild pyelectasia can be an indication of active or prior pyelonephritis, but may also be seen in patients treated with IV fluid therapy. Mild pelvic dilation can be present in patients with chronic renal disease. Patients with obstructed renal pelvises secondary to ureteroliths or strictures demonstrate significantly more dilation of the renal pelvis than those with pyelonephritis or who are undergoing fluid therapy.

The liver should be evaluated for multiple parameters. For example, the size will be subnormal in the face of cirrhosis, but enlarged in patients with Cushing's and diabetes. Echogenicity, hyperechogenicity, and homogeneity are characteristic of Cushing's disease and diabetes. The liver may be mottled, hypoechoic, or hyperechoic in cases of lymphoma, which can cause hypercalcemia and PU/PD; the notation of hepatic nodules may indicate liver failure or cirrhosis, benign nodular hyperplasia, or malignancy. The adrenal glands can be measured, as they are often—but not always—enlarged in cases of Cushing's disease, whereas they may be small in cases of Addison's. The presence of a mass can indicate an adrenal tumor causing Cushing's disease. The bladder should be assessed for wall thickness, as it may be increased secondary to chronic urinary tract infection (UTI) in cases of diabetes, Cushing's disease, and pyelonephritis. The presence of stones may be secondary to chronic UTI, Cushing's disease, and liver failure (the latter is especially indicated by the presence of ammonium biurate stones). It should be noted that an infection of the lower urinary tract does not cause PU/PD; however, this would predispose the patient to ascending pyelonephritis. The echogenicity of the spleen may be increased or decreased in cases of lymphoma, and the presence of nodules may indicate malignancy or benign nodular hyperplasia.

An abdominal ultrasound will provide information that helps diagnose many of these diseases, but a normal ultrasound does not definitively rule out all diseases, such as Cushing's, for example. Yet, by combining the information gathered from a basic workup and an abdominal ultrasound, one may be able to systematically rule out multiple disease processes or enable practitioners to choose appropriate additional testing.



PATIENT

Annie Barrington

Advanced blood testing: An ACTH stimulation test or low dose dexamethasone suppression test must be performed prior to assessing for diabetes insipidus or psychogenic polydipsia.

SPECIES

Canine

Evaluation of renal function: Early renal disease can cause PU/PD without resulting in an elevation in BUN or creatinine. Renal function can be assessed practically in hospital using an iohexal clearance test (preferable) or, less commonly, an endogenous creatinine clearance test. The disadvantage of the latter is that it requires 24-hour urine collection with a closed urinary catheter collection system. A more advanced and specific way to evaluate renal function involves using nuclear scintigraphy and measuring the glomerular filtration rate (GFR); however, this procedure is usually only available at select tertiary referral centers.

BREED

Mixed

SEX

Spayed Female

AGE

10 Years

The iohexal clearance test is easily administered and the results are calculated from a computerized model of the GFR. The protocol for administering the test is as follows: The patient should not be fed for 12 hours prior, but should be well hydrated. Give 300 mg/kg IV (slow push) and mark the time of injection to the nearest minute. Collect blood samples at 2, 3, and 4 hours to the nearest minute, and mark times on the samples. The serum samples should then be submitted to the Michigan State University Diagnostic Lab for a GFR study. Adverse effects of the iohexal are rare, but include anaphylactic / anaphylactoid reactions, hypotension, arrhythmias, acute renal failure, nausea, and vomiting. Pretreatment with diphenhydramine can reduce the occurrence of anaphylactic / anaphylactoid reactions. The normal values for dogs are a mean of 5.48 ml/kg/min and range of 2.89-8.07 ml/kg/min, and for cats, a mean of 1.94 ml/kg/min and range of 1.15-2.73 ml/kg/min.

WEIGHT

63.5 lbs

INTERPRETED BY

Eric Lindquist, DMV,
DABVP (CFM), Cert.
IVUSS

One performs an endogenous creatinine clearance by placing a urinary catheter with a closed collection system in the patient. All the urine should be collected and saved in a refrigerator for exactly 24 hours. The urine volume should be measured accurately with a graduated cylinder or syringe and recorded. An aliquot of urine (5 ml) is subsequently sent to the laboratory for a creatinine measurement. In addition, a serum sample is collected around the 12-hour point and submitted for creatinine analysis. The creatinine clearance is then estimated using an equation that considers the creatinine levels in both the serum and the urine, the time of urine collection, and the urine volume: $\text{Creatinine clearance} = \frac{\text{urine creatinine (mg/dl)} \times \text{urine volume (ml)}}{\{\text{time (min)} \times \text{serum creatinine (mg/dl)} \times \text{body weight (kg)}\}}$. Results are expressed in ml/min/kg. Normal values for dogs are 2.4-5 ml/min/kg and 1.9-5 ml/min/kg for cats. A decrease in the GFR by 66% correlates with isothermuria, and a decrease of 75% correlates with azotemia.

IMAGING PERFORMED BY

Vincent Ravancho, CVT

HOSPITAL NAME

North Jersey Animal
Hospital

REFERRING VET

Dr. Hansen

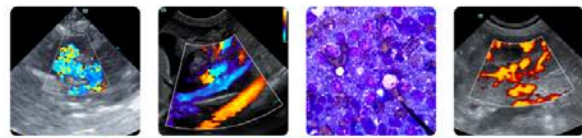
INVOICE

72871

DATE

12/30/25

If the estimated renal function is normal, then a low-dose dexamethasone suppression test (LDDST) or an ACTH stimulation test can be done to assess for Cushing's disease. In cases where the likelihood of Cushing's is low, a urine cortisol creatinine ratio (UCCR) can be run on a urine sample obtained at home. If the results are negative, Cushing's disease can be ruled out; however, if they are positive, they are not necessarily conclusive, and additional testing for Cushing's will be required. A PCR or serologic titers for leptospirosis can be considered if clinically appropriate. Once all causes of PU/PD other than central diabetes insipidus, primary nephrogenic diabetes insipidus, and psychogenic polydipsia (a diagnosis made by exclusion) have been ruled out, then one can either perform a modified water deprivation test or pursue an even more practical approach—trial therapy with vasopressin to assess response to ADH



PATIENT

Annie Barrington

supplementation. The modified water deprivation test (MWDT) is not typically recommended anymore, as it can result in rapid dehydration and acute renal decompensation in PU/PD patients, especially in those with nonazotemic renal disease.

SPECIES

Canine

Trial therapy with vasopressin: A trial with vasopressin therapy at home may not yield a definitive diagnosis, but can be less expensive and safer than performing a MWDT. The vasopressin can be given as an intracconjunctival drop twice daily; the urine specific gravity and water intake should be measured after one week. Alternatively, and likely easier, the vasopressin can be given as an oral tablet. Current dosage recommendations are 0.1 mg tablet/20 kg dog PO TID for 7 days or 0.2 mg tablet/40 kg dog PO TID for 7 days; urine specific gravity and water consumption should be reevaluated after this time. If the water intake dramatically decreases and the urine specific gravity increases by more than 50%, then this is strongly indicative of chronic kidney disease, provided Cushing's has been ruled out. It is recommended that one attempt to reestablish the medullary concentration gradient before trial therapy. This would entail gradually reducing the patient's water intake to within normal range (60-80 ml/kg/day) over several days prior to initiating the vasopressin therapy. This should only be done once the possibility of nonazotemic renal disease has been excluded using renal function testing.

BREED

Mixed

SEX

Spayed Female

AGE

10 Years

WEIGHT

63.5 lbs

INTERPRETED BY

Eric Lindquist, DMV,
DABVP (CFM), Cert.
IVUSS

Treatment: Treatment for secondary causes of PU/PD is based on the primary disease that is diagnosed. For example, specific therapy for cases of Cushing's disease, diabetes mellitus, or pyelonephritis would be implemented first before treating for PU/PD specifically. In other words, the actual resolution of PU/PD depends on the etiology. Therapy for central diabetes insipidus is based on the supplementation of an exogenous form of ADH. Vasopressin intranasal spray (1-4 drops in the conjunctival sac PO Q12-24hr, titrated to resolve the PU/PD) is most commonly used. Oral vasopressin can also be tried, although an exact dose is unknown and reported dosing strategies vary depending on the source (e.g. the dose range is ¼-½ of a 0.1-0.2 mg tablet PO Q12-24hr or 0.1-0.2 mg PO Q8hr; adjust as needed to control signs). Additional medical therapy for partial central diabetes insipidus consists of enhancing the effects of ADH at the level of the kidney using chlorpropamide or thiazide diuretics, and feeding the patient a diet low in sodium. Congenital nephrogenic diabetes insipidus is treated with salt restriction and thiazide diuretics. Psychogenic PU/PD can be managed with slow gradual water restriction. The therapies for partial central diabetes insipidus, primary nephrogenic diabetes insipidus, and psychogenic polyuria are not fully effective.

IMAGING PERFORMED BY

Vincent Ravancho, CVT

HOSPITAL NAME

North Jersey Animal
Hospital

REFERRING VET

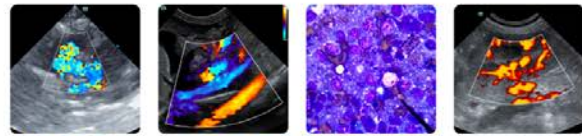
Dr. Hansen

INVOICE

72871

DATE

12/30/25



PATIENT

Annie Barrington

SPECIES

Canine

BREED

Mixed

SEX

Spayed Female

AGE

10 Years

WEIGHT

63.5 lbs

INTERPRETED BY

Eric Lindquist, DMV,
DABVP (CFM), Cert.
IVUSS

IMAGING PERFORMED BY

Vincent Ravancho, CVT

HOSPITAL NAME

North Jersey Animal
Hospital

REFERRING VET

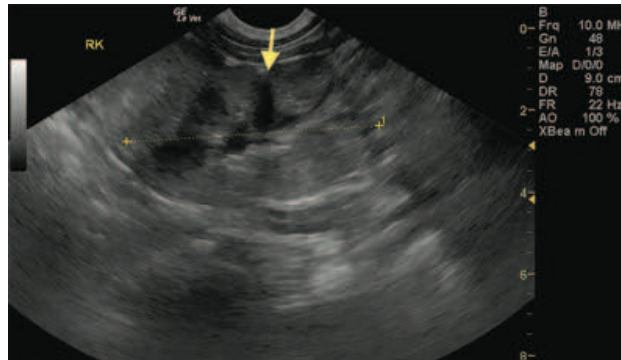
Dr. Hansen

INVOICE

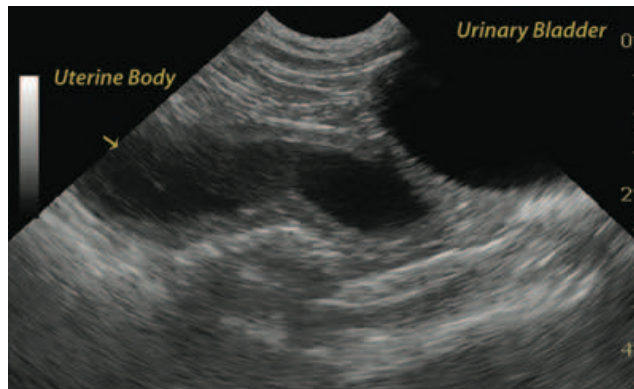
72871

DATE

12/30/25



Long axis of the right kidney in a 1 year old Boxer with congenital renal dysplasia. Note the enlargement, increased cortical echogenicity, abnormal corticomedullary ratio and disorganized arrangement of the renal pyramids (arrow). Similar changes were noted in the left kidney.



Long axis of the caudal abdomen in a dog with a pyometra. The uterine body (arrowed) is moderately dilated and filled with hypoechoic content. Note the minor cystic changes within the thickened uterine wall. The vertex of the urinary bladder is seen in the near field on the image right.

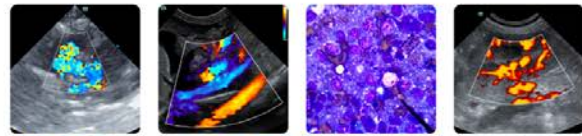
References:

Bartges J. H2O or K9P? Polyuria and polydipsia. Proceedings from the American College of Veterinary Internal Medicine, Charlotte, NC, June 4-7, 2003.

Bexfield NH, Heiene R, Gerritsen RJ, et al. Glomerular filtration rate estimated by 3 sample plasma clearance of Iohexal in 118 healthy dogs. *J Vet Intern Med* 2008;22:66-73.

Feldman EC and Nelson RW. Water metabolism and diabetes insipidus. In: Feldman EC and Nelson RW, eds. *Canine and Feline Endocrinology and Reproduction*, 2nd ed. Philadelphia, PA: WB Saunders; 1996:2-37.

Feldman EC. Polyuria and polydipsia. In: Ettinger SJ, Feldman EC, eds. *Textbook of Small Animal Internal Medicine*, 7th ed. Saint Louis, MO: Saunders Elsevier; 2010:156-59.



PATIENT

Annie Barrington

Lees, GE, Willard MD, Green RA. Urinary disorders. In: Willard MD, Tvedten H, and Turnwald G, eds. *Small Animal Clinical Diagnosis by Laboratory Methods, 2nd ed.* Philadelphia, PA: WB Saunders Company; 1994:115-46.

SPECIES

Canine

BREED

Mixed

Rijnberk A. Diabetes insipidus. In: Ettinger SJ, Feldman EC, eds. *Textbook of Small Animal Internal Medicine, 7th ed.* Saint Louis, MO: Saunders Elsevier; 2010:1716-22.

SEX

Spayed Female

Sanderson S. Current concepts for the management of chronic renal failure in the dog and cat – early diagnosis and supportive care. Proceedings from the World Small Animal Veterinary Association, Mexico City, Mexico, May 11-14, 2005.

AGE

10 Years

WEIGHT

63.5 lbs

INTERPRETED BY

Eric Lindquist, DMV,
DABVP (CFM), Cert.
IVUSS

**IMAGING
PERFORMED BY**

Vincent Ravancho, CVT

HOSPITAL NAME

North Jersey Animal
Hospital

REFERRING VET

Dr. Hansen

INVOICE

72871

DATE

12/30/25