



PATIENT

Charlie Holsinger

SPECIES

Canine

BREED

Labrador/Terrier Mix

SEX

Neutered male

AGE

6 years

WEIGHT

69 lbs

INTERPRETED BY

Eric Lindquist, DMV
DABVP, Cert. IVUSS

IMAGING PERFORMED BY

Dr. Ebersole

HOSPITAL NAME

Scanvet

REFERRING VET

Dr. Peyser

INVOICE

42431

DATE

12/30/22

PRESENTING CLINICAL SIGNS

History: Cervical US to assess thyroid gland. T-4 elevated. Patient is "gulping", hair coat changes and hind limb weakness. Brought to Specialty Clinic this summer for facial twitching and hind limb weakness; treated with steroids for presumed auto-immune disease. Off steroids for several months now.

Abnormal PE/Chem/CBC/UA Results: PE: dry flaky skin, generalized. BCS 5-6/9. CBC/Chem: all WNL. T-4 - 4.2 H

ULTRASONOGRAPHIC EXAMINATION OF THE THYROID

The left thyroid lobe measured 2.93 x 0.52 cm with a hypoechoic, fairly normal, non-expansive parathyroid measuring up to 0.52 cm. The right thyroid revealed parathyroids that measured 0.58 cm. The right thyroid lobe was uniform and measured 2.5 x 0.54 cm. The thyroid glands were imaged from long and short axis. There was no evidence of pathology. Some parathyroids on both glands appeared slight enlarged, yet non-expansive. This is likely a normal variant for this patient.

ULTRASONOGRAPHIC FINDINGS

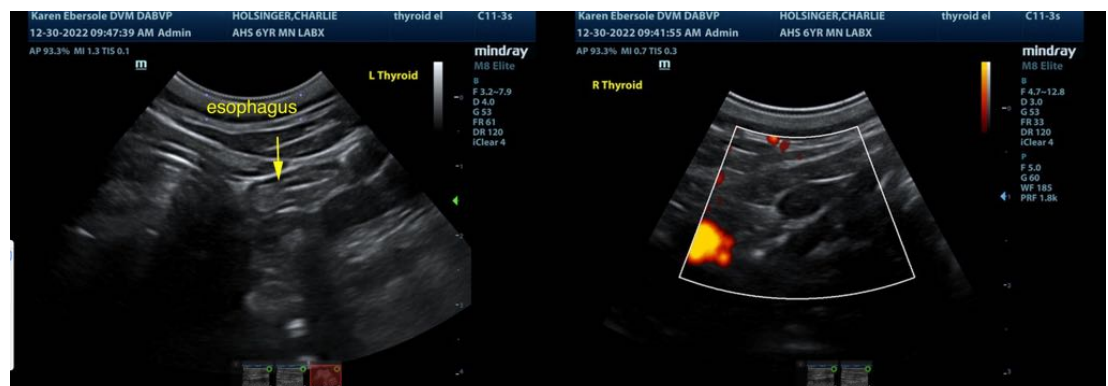
Normal thyroid glands, prominent parathyroids.

INTERPRETATION OF THE FINDINGS & FURTHER RECOMMENDATIONS

There was no evidence of pathology. Assessment for ingesta of thyroid hormone through neck meat or similar should be considered, yet there was no evidence of structural pathology regarding the thyroid glands. I cannot rule out ectopic thyroid tissue. Chest radiographs are warranted to assess for any cranial mediastinal masses that would be potentially indicative of ectopic thyroid carcinoma.

Internal medicine consult can be utilized through SonoPath.com. You can select the internal medicine drop down at <http://spa.sonopath.com/>.

One of the world's top internists & SonoPath associate Dr. Remo Lobetti BVSc, MMedVet, PhD, DECVIM can evaluate your case through SonoPath. <https://sonopath.com/resources/sonopath-services/internal-medicine-teleconsultation-services>





PATIENT

Charlie Holsinger

SPECIES

Canine

BREED

Labrador/Terrier Mix

SEX

Neutered male

AGE

6 years

WEIGHT

69 lbs

INTERPRETED BY

Eric Lindquist, DMV
DABVP, Cert. IVUSS

IMAGING PERFORMED BY

Dr. Ebersole

HOSPITAL NAME

Scanvet

REFERRING VET

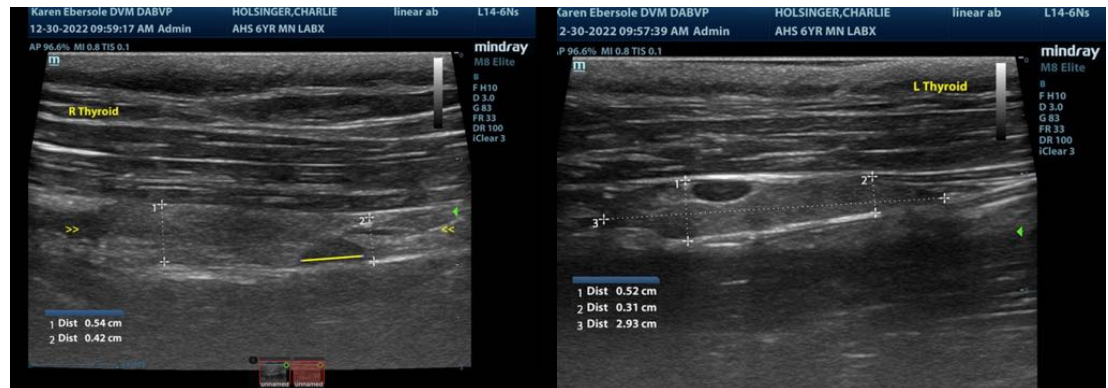Dr. Peyser

INVOICE

42431

DATE

12/30/22



The information and recommendations provided are based on the images presented by the referring veterinarian/sonographer. No evaluation can be communicated regarding pathology that was not visible in the image/video clips provided.

Thank you for this referral. If the clinical or image interpretation does not parallel your findings or if I can be of any further assistance please contact me.

Eric Lindquist, DMV, DABVP, Cert. IVUSS, CEO of SonoPath.com
info@SonoPath.com