



**PATIENT**

Zippy Boos

**PRESENTING CLINICAL SIGNS**

Anorexic lethargic and vomiting  
Abnormal PE/Chem/CBC/UA Results: No blood work available at time of scan

**SPECIES**

Feline

**ULTRASONOGRAPHIC EXAMINATION OF THE ABDOMEN**

**Urinary System**

**BREED**

DSH

The **urinary bladder**, trigone, and pelvic urethra presented normal thicknesses and normal tone. The ureters were not visible which is normal. No uroliths or sediment were visualized and anechoic urine was present. No evidence of inflammatory or neoplastic changes were noted. Ureteral papillae were normal.

**SEX**

Spayed Female

The **kidneys** revealed normal size and structure, corticomedullary definition and ratio for this age. The cortices presented largely uniform texture with normal echogenic relationship to liver and spleen. Medullary structure differed distinctly from the cortex and no evidence of pelvic dilation was present. The capsules were acceptably uniform without significant irregularities. The right kidney measured 3.31 cm. The left kidney measured 3.3 cm.

**AGE**

12 Years

**Adrenal Glands**

**WEIGHT**

4.5 kg

The **right adrenal gland** was visualized and recognized as having normal shape, size, position and echogenicity for this breed. The phrenic vasculature, glandular echogenicity and detail were unremarkable. Capsule, cortex, and medullary definition were normal for this age patient. The right adrenal gland measured 0.3 cm. The region of the **left adrenal gland** was unremarkable.

**Spleen**

**INTERPRETED BY**

Eric Lindquist, DMV  
DABVP, Cert. IVUSS

The **spleen** was folded upon itself, uniform.

**Liver**

**IMAGING PERFORMED BY**

Dr. Belan

The **liver** images from right and left intercostal as well as subcostal views revealed subjectively normal liver size, contour, and structure. Some age-related parenchymal remodeling was noted but likely not clinically significant at this time. Vascular and biliary tracts were of normal volume and no evidence of congestion was noted. The gallbladder presented some dependent debris with essentially normal contour. The cystic and common bile ducts were normal. No overt evidence of active inflammatory, infiltrative or regenerative pathology was noted but should be paired with current or past LE elevations regarding any clinical significance to this presentation. The hepatic lymph nodes were unremarkable.

**HOSPITAL NAME**

Alpine 24/7 VC

**Gastrointestinal**

**REFERRING VET**

Dr. Karagic

Examination of the **gastrointestinal tract** revealed a stomach and intestine free of stasis, of normal wall thickness, acceptable curvilinear mural detail, and peristaltic activity. Small and large intestine demonstrated normal luminal chyme and stool consistency respectively. No obstructive or overt infiltrative disease was noted. No associated abnormal lymphatic activity was noted.

**INVOICE**

33860

**Pancreas**

**DATE**

12/30/21

The base and limbs of the **pancreas** were observed to be largely isoechoic to surrounding omental fat. Some parenchymal remodeling, however, with mild deviation from curvilinear normalcy was observed. Pancreatic duct and capsular irregularities were present consistent with age related changes. If pain upon imaging (+ Murphy sign) was present or if the patient is focally painful in subxyphoid palpation then low-grade smoldering chronic pancreatitis should be suspected.



**PATIENT**

Zippy Boos

**ULTRASONOGRAPHIC FINDINGS**

- Geriatric abdomen

**SPECIES**

Feline

**INTERPRETATION OF THE FINDINGS & FURTHER RECOMMENDATIONS**

No evidence of significant structural disease. Possible low-grade pancreatitis given the chronic pancreatic changes. However, the changes were fairly mild. Supportive care should prove effective.

**BREED**

DSH

**SEX**

Spayed Female

**AGE**

12 Years

**WEIGHT**

4.5 kg

**INTERPRETED BY**

Eric Lindquist, DMV  
DABVP, Cert. IVUSS

**IMAGING PERFORMED BY**

Dr. Belan

**HOSPITAL NAME**

Alpine 24/7 VC

**REFERRING VET**

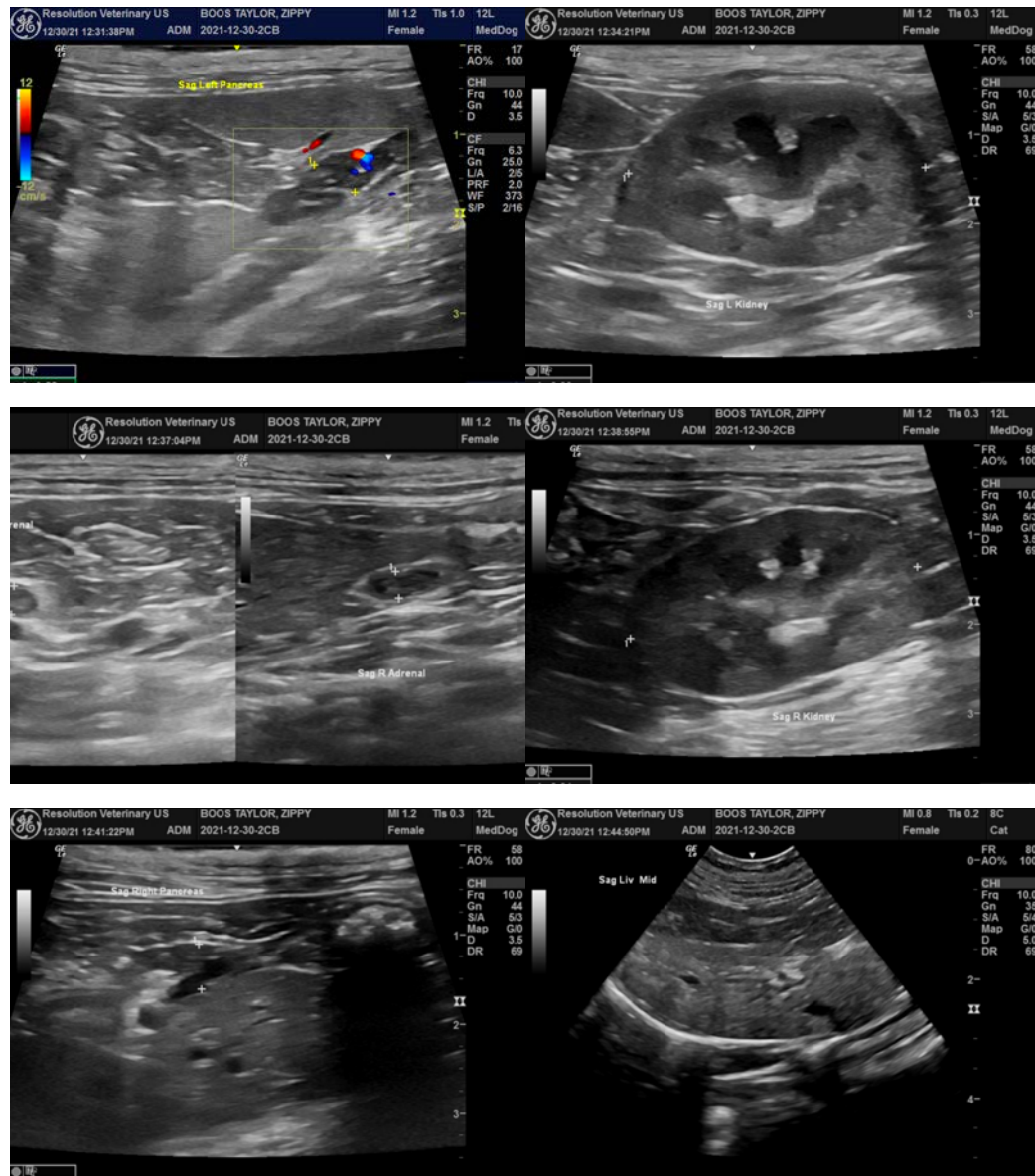
Dr. Karagic

**INVOICE**

33860

**DATE**

12/30/21





**PATIENT**

Zippy Boos

**SPECIES**

Feline

**BREED**

DSH

**SEX**

Spayed Female

**AGE**

12 Years

**WEIGHT**

4.5 kg

**INTERPRETED BY**

Eric Lindquist, DMV  
DABVP, Cert. IVUSS

**IMAGING PERFORMED BY**

Dr. Belan

**HOSPITAL NAME**

Alpine 24/7 VC

**REFERRING VET**

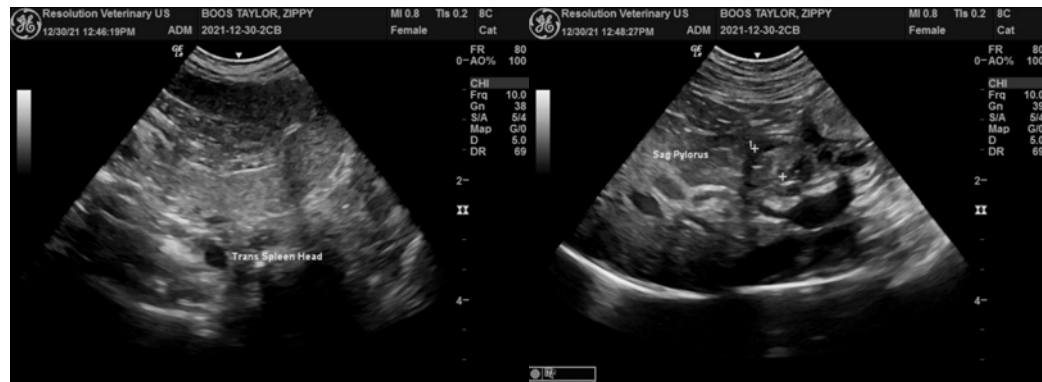
Dr. Karagic

**INVOICE**

33860

**DATE**

12/30/21



The information and recommendations provided are based on the images presented by the referring veterinarian. No evaluation can be communicated regarding pathology that was not visible in the image/video clips provided.

Thank you for this referral. If the clinical or image interpretation does not parallel your findings or if I can be of any further assistance please contact me.

Eric Lindquist, DMV, DABVP, Cert. IVUSS, CEO of SonoPath.com  
[info@SonoPath.com](mailto:info@SonoPath.com)