


**PATIENT**

Ziggy Alvarez-Cortez

**SPECIES**

Canine

**BREED**

Miniature Poodle X

**SEX**

Neutered Male

**AGE**

12 Years

**WEIGHT**

8.9 Pounds

**INTERPRETED BY**

 Eric Lindquist, DMV  
 DABVP, Cert. IVUSS

**IMAGING PERFORMED BY**

Jessica Bailes

**HOSPITAL NAME**

 All Creatures Great &  
 Small Corvallis

**REFERRING VET**

Dr. Beth Marszewski

**INVOICE**

33855

**DATE**

12/30/21

**PRESENTING CLINICAL SIGNS**

Prior hx of stable stage B1 valvular disease and severe dental disease. Last echo was performed 10/21 and was concerning for possible rupture chordae tendonae so recheck echo was rec'd in 1-3 months. BP was checked after last echo - was 150 systolic. Has been on vetmedin for the last year.

Abnormal PE/Chem/CBC/UA Results: grade 3/6 systolic murmur, severe dental disease BP rechecked today - 170 systolic on average. Scheduled for dental cleaning next week. Need to assess anesthetic risk.

**ULTRASONOGRAPHIC EXAMINATION OF THE HEART**

CANINE CARDIAC PARAMETERS	MR VMAX (m/s)	TR VMAX (m/s)	LA/AO (Boon method)	LA/AO (Heart Base; Swe)	FS (%)	EF (%)	EPSS (cm)
NORMAL PARAMETER	4.5-5.5	<2.7	1.3	<1.6	28-40	40-100	<0.6
PATIENT	5.9		1.01	1.33	35	66	NM
CANINE CARDIAC PARAMETERS	HR (BPM)	AV VMAX (m/s)	PV MAX (m/s)	BODY WEIGHT (kg)	LA 2D short axis Base view (cm)	LVIDd Avg; 2D and m-mode short axis (cm)	LVIDs Avg; 2D and m-mode short axis (cm)
NORMAL PARAMETER	50-100	0.7-1.7	0.7-1.6				
PATIENT		1.73	0.47		2.39	2.25	

**Cardiac Presentation**

The cardiac presentation revealed persistent mitral insufficiency. Left atrial and left ventricular internal diameters were normal. Moderate filling of the left atrium noted on color flow assessment. Contractility was adequately compensatory. Aortic outflow velocities were normal. Trivial tricuspid insufficiency noted, not clinically significant. Right atrial and right ventricular internal diameters were normal. Normal LA/RA ratio evident. Pericardial and pleural spaces were unremarkable.

**ULTRASONOGRAPHIC FINDINGS**

- Stable Stage B1 valvular disease

**INTERPRETATION OF THE FINDINGS & FURTHER RECOMMENDATIONS**

The heart is stable without clinical disease. No overt contraindication for anesthesia of brief to moderate duration. I suggest Torbutrol premed, Propofol induction, Isoflor maintenance or similar protocol if anesthesia is desired. Blood pressure recommended if not already performed and target white coat negative systolic pressure of < 160 mmHg. If higher than this ACE-inhibitor is suggested to reach this level. Recheck echocardiogram is recommended in 6 months, earlier if murmur grade increases or clinical signs initiate.



**PATIENT**

Ziggy Alvarez-Cortez

**SPECIES**

Canine

**BREED**

Miniature Poodle X

**SEX**

Neutered Male

**AGE**

12 Years

**WEIGHT**

8.9 Pounds

**INTERPRETED BY**

Eric Lindquist, DMV  
DABVP, Cert. IVUSS

**IMAGING PERFORMED BY**

Jessica Bailes

**HOSPITAL NAME**

All Creatures Great &  
Small Corvallis

**REFERRING VET**

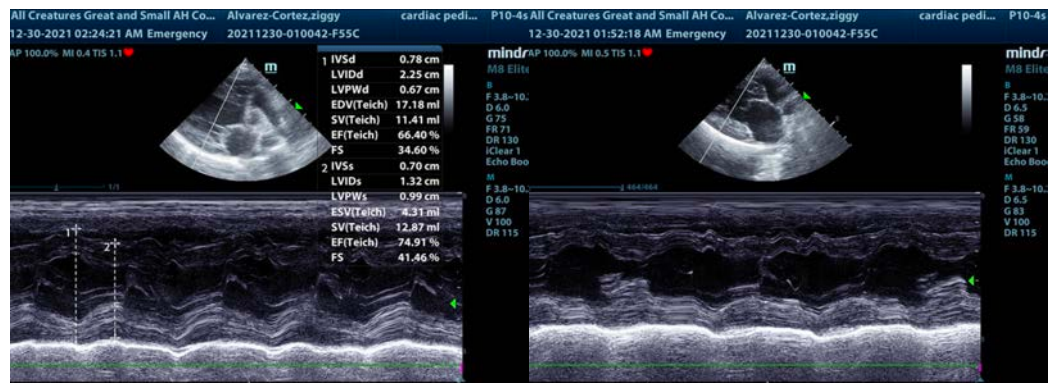
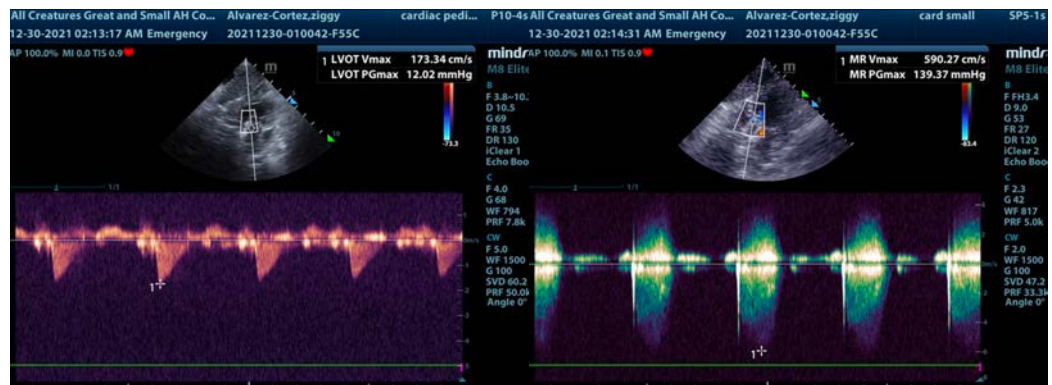
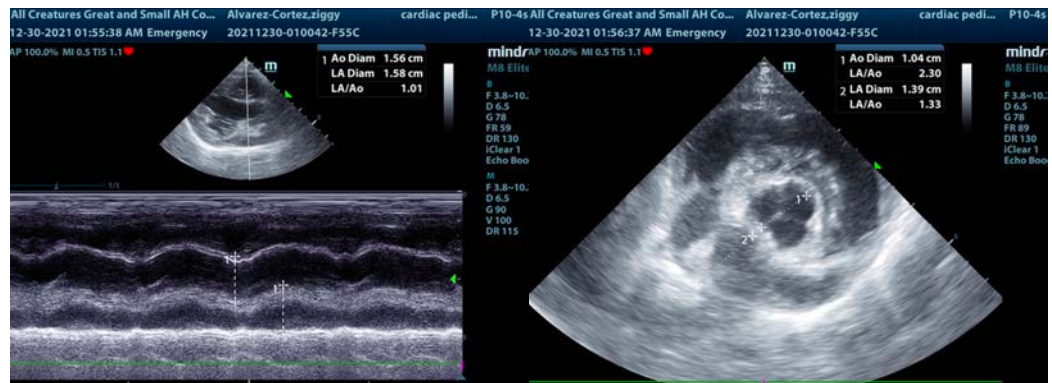
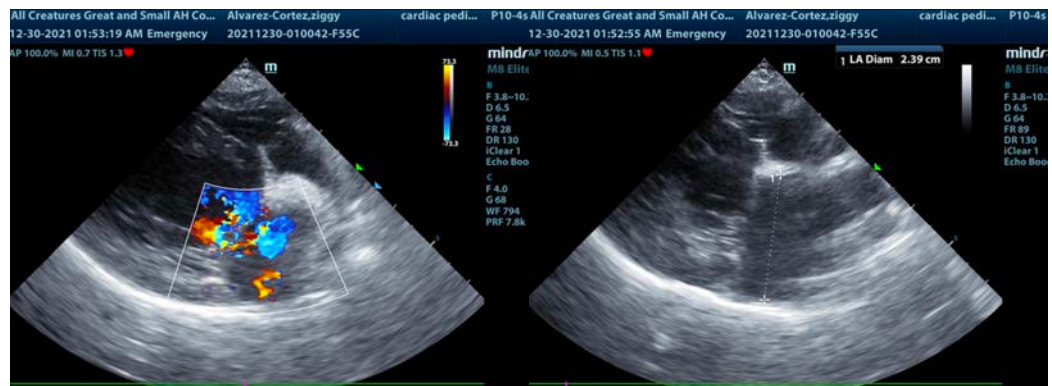
Dr. Beth Marszewski

**INVOICE**

33855

**DATE**

12/30/21





**PATIENT**

Ziggy Alvarez-Cortez

The information and recommendations provided are based on the images presented by the referring veterinarian. No evaluation can be communicated regarding pathology that was not visible in the image/video clips provided.

**SPECIES**

Canine

Thank you for this referral. If the clinical or image interpretation does not parallel your findings or if I can be of any further assistance please contact me.

**BREED**

Miniature Poodle X

**Eric Lindquist**, DMV, DABVP, Cert. IVUSS, CEO of SonoPath.com

[info@SonoPath.com](mailto:info@SonoPath.com)

**SEX**

Neutered Male

**AGE**

12 Years

**WEIGHT**

8.9 Pounds

**INTERPRETED BY**

Eric Lindquist, DMV  
DABVP, Cert. IVUSS

**IMAGING  
PERFORMED BY**

Jessica Bailes

**HOSPITAL NAME**

All Creatures Great &  
Small Corvallis

**REFERRING VET**

Dr. Beth Marszewski

**INVOICE**

33855

**DATE**

12/30/21