**DATE PRESENTING CLINICAL SIGNS**

12/30/21

PATIENT

History: Hematemesis and diarrhea. Cranial abdominal mass found on abdominal radiograph.

Kona Butzke

Lab Results: Attached separately.

SPECIES

Radiographs: Cranial abdominal mass with micro hepatica.

Canine

Date of Previous IntraPet Ultrasound: No previous IntraPet scans.

BREED

Sedation: Not required to complete full diagnostic ultrasound.

Labrador Retriever

Stat Report: Not requested.

Imaging Performed By: Rachel Brillhart, RDMS.

ULTRASONOGRAPHIC EXAMINATION OF THE ABDOMEN**SEX****Urinary System**

Spayed Female

The **urinary bladder**, trigone, and pelvic urethra presented normal thicknesses and normal tone. The ureters were not visible which is normal. No uroliths or sediment were visualized and anechoic urine was present. No evidence of inflammatory or neoplastic changes were noted. Ureteral papillae were normal.

AGE

10/6/16

The **kidneys** revealed normal size and structure, corticomedullary definition and ratio for this age. The cortices presented largely uniform texture with normal echogenic relationship to liver and spleen.

WEIGHT

85 Lbs.

Medullary structure differed distinctly from the cortex and no evidence of pelvic dilation was present. The capsules were acceptably uniform without significant irregularities. The left kidney measured 6.41 cm. The right kidney measured 6.36 cm.

INTERPRETED BY**Adrenal Glands**Eric Lindquist, DMV
DABVP, Cert. IVUSS

Both **adrenal glands** were visualized and recognized as having normal shape, size, position and echogenicity for this breed. The phrenic vasculature, glandular echogenicity and detail were unremarkable. Capsule, cortex, and medullary definition were normal for this age patient. The left adrenal gland measured 2.62 cm x 0.72 cm at the caudal pole and 0.61 cm at the cranial pole. The right adrenal gland measured 2.72 cm x 0.62 cm at the caudal pole and 0.8 cm at the cranial pole.

HOSPITAL NAME

Bayside AMC

Spleen

The **spleen** revealed minor heterogeneous parenchymal changes.

REFERRING VET

Dr. Sims

Liver

The **liver** images submitted revealed subjectively normal liver size, contour, and structure. Parenchymal echogenicity was naturally coarse and hypoechoic to the spleen. Vascular and biliary tracts were of normal volume with no evidence of congestion. The gallbladder presented acceptably thin walls with primarily anechoic content. The cystic and common bile ducts were normal. No pathological hepatic lymphadenopathy was evident. No overt structural evidence of inflammatory, infiltrative or regenerative pathology was evident.

INVOICE

13258

Gastrointestinal

The **upper gastrointestinal tract** revealed a minor amount of luminal fluid. No overt obstruction. Minor focal intestinal thickening present. The small intestine and colon were unremarkable.

Pancreas

*See Free Abdomen section

Free Abdomen

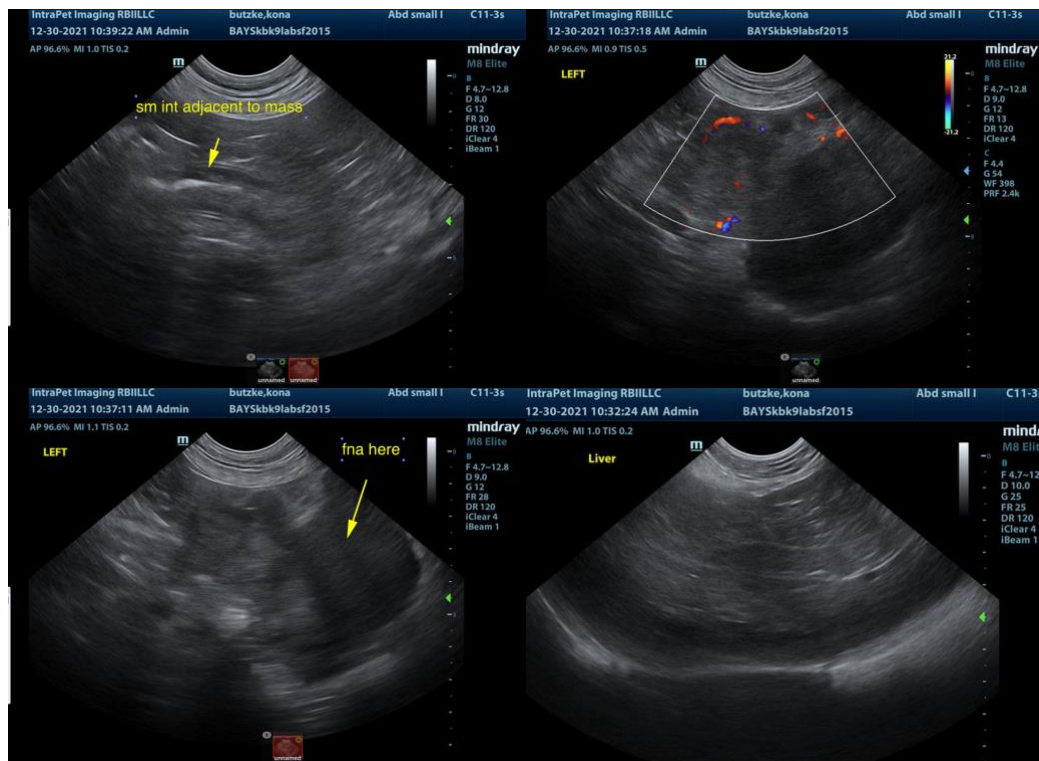
The left cranial abdomen revealed a mixed hypoechoic parenchymal mass (7.0 cm x 5.6 cm) with peripheral inflammation. The mass was undifferentiated. The mass appeared to be deriving from the caudal aspect of the left pancreatic limb. The mass impinges upon the adjacent intestine yet did not appear to directly involve it.

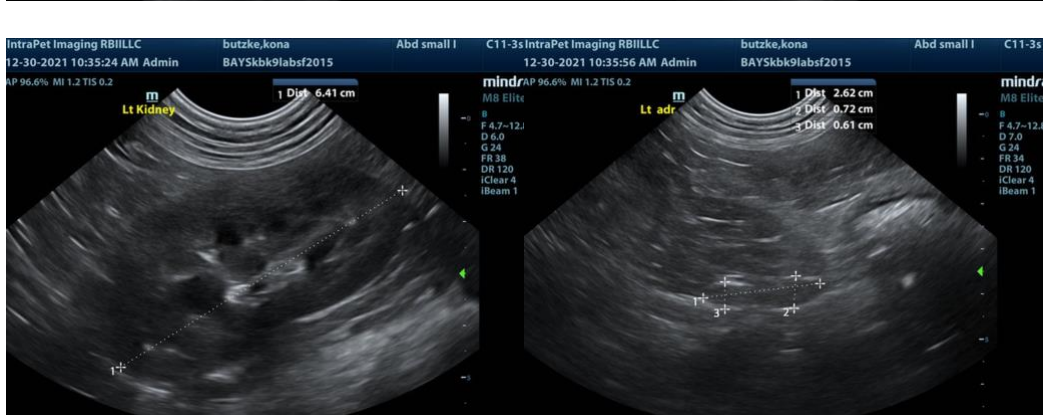
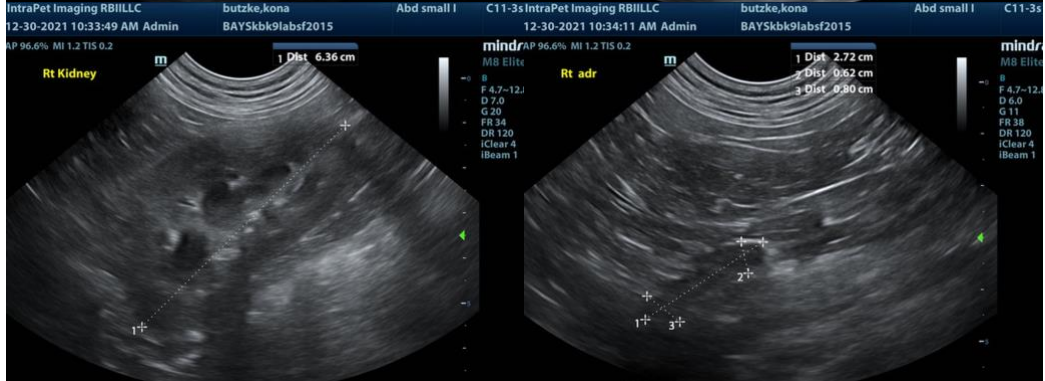
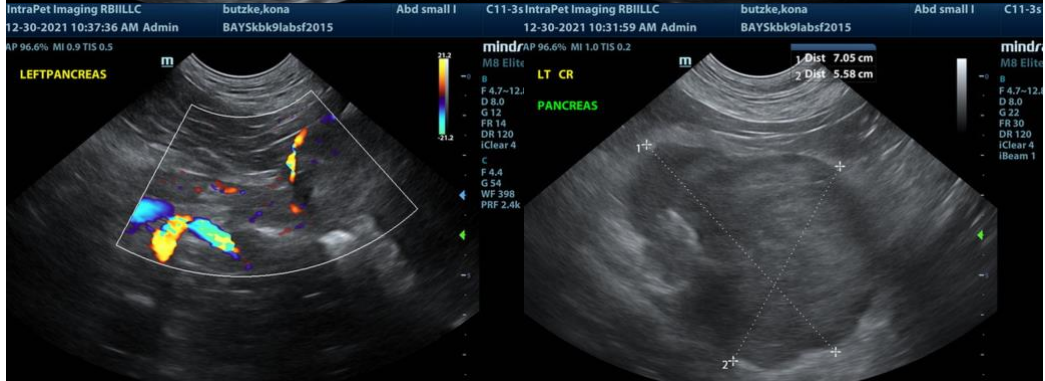
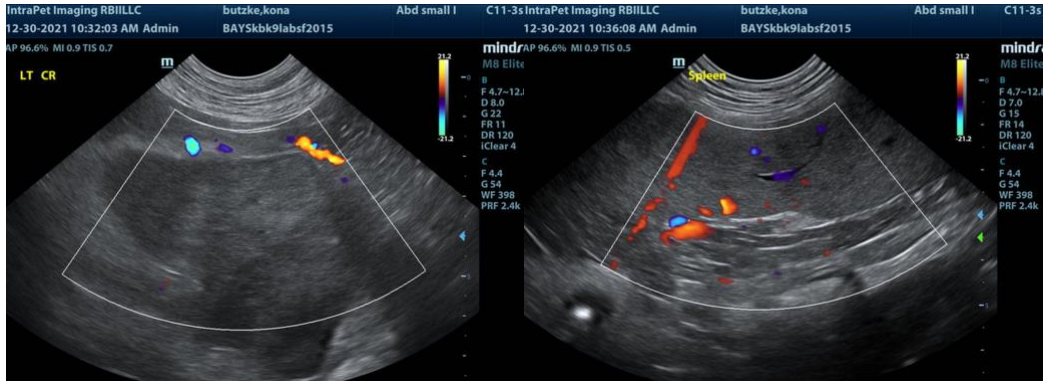
ULTRASONOGRAPHIC FINDINGS

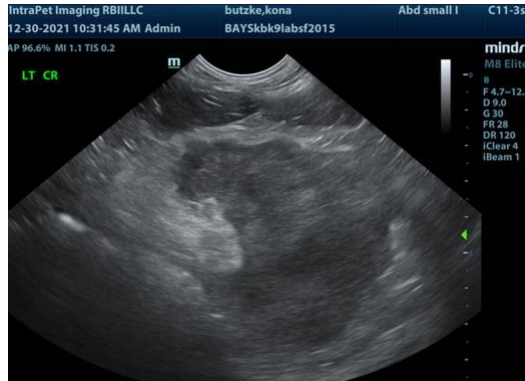
- Left cranial parenchymal mass, appears resectable. Pancreatic necrosis versus carcinoma or round cell neoplasia.
- Concurrent gastritis
- Heterogeneous spleen

INTERPRETATION OF THE FINDINGS & FURTHER RECOMMENDATIONS

Exploratory surgery recommended. Ultrasound guided FNA could be considered for cursory evaluation from a cytological standpoint. The mass does appear to be fairly vascular, diminishing the potential for simple necrosis. Guarded prognosis, depending on cytology results and surgical outcome.







The information and recommendations provided are based on the images presented by the referring veterinarian. No evaluation can be communicated regarding pathology that was not visible in the image/video clips provided.

Thank you for this referral. If the clinical or image interpretation does not parallel your findings or if I can be of any further assistance please contact me.

Eric Lindquist, DMV, DABVP, Cert. IVUSS, CEO of SonoPath.com
Eric.Lindquist@SonoPath.com