



## PATIENT

Marcus Selvaraju

## SPECIES

Canine

## BREED

Chihuahua Mix

## SEX

Neutered male

## AGE

5 years

## WEIGHT

9.25 lbs

## INTERPRETED BY

Eric Lindquist, DMV  
DABVP, Cert. IVUSS

## IMAGING PERFORMED BY

Dr, Casper

## HOSPITAL NAME

Hometown AH Florida

## REFERRING VET

Dr. Hopkins

## INVOICE

69311

## DATE

12/3/25

## PRESENTING CLINICAL SIGNS

History of microhepatica on rads, chest rads NSF. Elevated post-prandial bile acids. Remaining fasted bloodwork/Tt4/UA WNL

Abnormal PE/Chem/CBC/UA Results: See attached bloodwork/Rad results

## ULTRASONOGRAPHIC EXAMINATION OF THE ABDOMEN

### Urinary System

The **urinary bladder**, trigone, and pelvic urethra presented normal thicknesses and normal tone. The ureters were not visible which is normal. No uroliths or sediment were visualized and anechoic urine was present. No evidence of inflammatory or neoplastic changes was noted. Ureteral papillae were normal.

The **kidneys** revealed normal size and structure, corticomedullary definition and ratio for this age. The cortices presented largely uniform texture with normal echogenic relationship to liver and spleen. Medullary structure differed distinctly from the cortex and no evidence of pelvic dilation was present. The capsules were acceptably uniform without significant irregularities. The left kidney measured 3.6 cm. The right kidney measured 3.7 cm.

### Adrenal Glands

Both **adrenal glands** were visualized and recognized as having normal shape, size, position and echogenicity for this breed. The phrenic vasculature, glandular echogenicity and detail were unremarkable. Capsule, cortex, and medullary definition were normal for this age patient. The right adrenal gland measured 0.7 cm at the cranial pole and 0.47 cm at the caudal pole. The left adrenal gland measured 0.5 cm.

### Spleen

The **spleen** in this patient was mildly enlarged with uniform parenchyma and was folded upon itself cranially. This is a positional variant and is not pathological. There was no evidence of significant disease.

### Liver

The **liver** was mildly subnormal in size with uniform parenchyma. The portal vein was visualized prior to the portal hilus. In one view a potential, dorsally directed abnormal vessel was noted. However, further imaging is necessary. The gallbladder presented acceptably thin walls with primarily anechoic content. The cystic and common bile ducts were normal. No pathological hepatic lymphadenopathy was evident.

### Gastrointestinal

Examination of the **gastrointestinal tract** revealed a stomach and intestine free of stasis, of normal wall thickness, acceptable curvilinear mural detail, and peristaltic activity. Small and large intestine



## PATIENT

Marcus Selvaraju

## SPECIES

Canine

## BREED

Chihuahua Mix

## SEX

Neutered male

## AGE

5 years

## WEIGHT

9.25 lbs

## INTERPRETED BY

Eric Lindquist, DMV  
DABVP, Cert. IVUSS

## IMAGING PERFORMED BY

Dr, Casper

## HOSPITAL NAME

Hometown AH Florida

## REFERRING VET

Dr. Hopkins

## INVOICE

69311

## DATE

12/3/25

demonstrated normal luminal chyme and stool consistency respectively. No obstructive or overt infiltrative disease was noted. No associated abnormal lymphatic activity was noted.

## *Pancreas*

The base and limbs of the **pancreas** were observed to be largely isoechoic to surrounding omental fat. Pancreatic duct and capsular contour were acceptably normal and parenchyma respected normal curvilinear patterns. No overt evidence of active inflammatory or neoplastic disease was noted.

## ULTRASONOGRAPHIC FINDINGS

Mildly subnormal liver size. Potential abnormal vessel.

## INTERPRETATION OF THE FINDINGS & FURTHER RECOMMENDATIONS

The best view of the portal hilus was obscured by underlying gas. Further imaging of the portal hilus in SDEP 13 in particular and 14 with increased depth and more dorsal approach. Otherwise, CT evaluation is warranted. Given the relatively minor increase in bile acids, portal hypoplasia/microvascular dysplasia is most likely. However, I cannot completely rule out a shunt at this time. Moreover, given that no other criteria outside of the liver is supportive for portosystemic shunting such as renal calculi and bladder calculi, the probability of a shunt is low or the shunt may have a minor shunt fraction. Medical management may be the best approach; however, I do strongly recommend further imaging of the portal hilus in SDEP 12-14 with slight increased depth.

## **Hepatic Support for Bile Acid Elevation +/- Hepatic Encephalopathy**

**Royal Canin Hepatic Support diet or Hills L/D, Metronidazole** (7.5 mg/kg PO bid) over the next 14 days, **Lactulose** (Oral: 3.1-3.7 g/5 ml lactulose in a syrup base) long term to target 2-3 soft stools/day, with a **high-quality protein supplement** of minor amount of **yogurt or cheddar cheese**. Monitor bile acids, with attention paid to dropping albumin, BUN or cholesterol. Same and nutraceuticals as needed. **Ursodiol** (10-15 mg/kg p.o. q24h) can be considered as hepatoprotectant and to enhance bile flow. **Zinc** serum level keep between 200–500 ug/dl. If deficient then Tx zinc acetate 1-3 mg/kg/day. Gastrointestinal protectants are recommended if the patient is anorexic.



**PATIENT**

Marcus Selvaraju

**SPECIES**

Canine

**BREED**

Chihuahua Mix

**SEX**

Neutered male

**AGE**

5 years

**WEIGHT**

9.25 lbs

**INTERPRETED BY**

Eric Lindquist, DMV  
DABVP, Cert. IUUS

**IMAGING PERFORMED BY**

Dr. Casper

**HOSPITAL NAME**

Hometown AH Florida

**REFERRING VET**

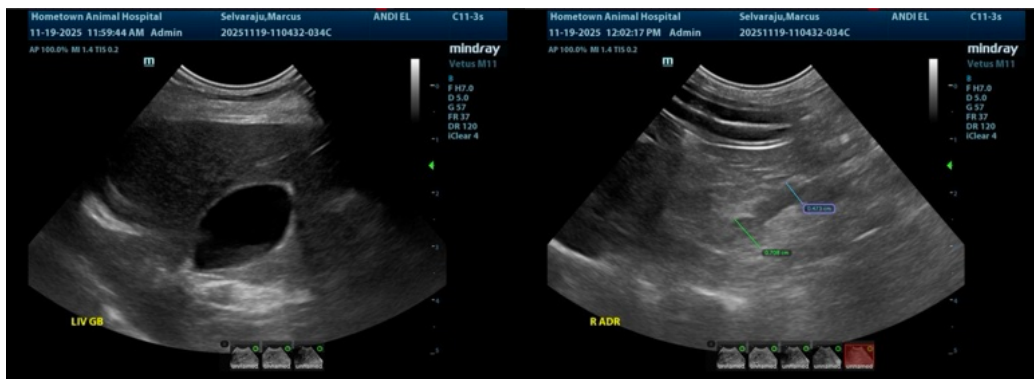
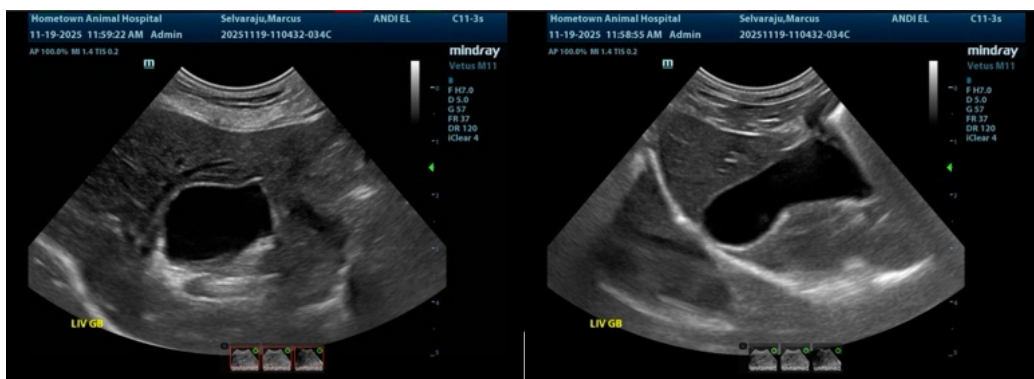
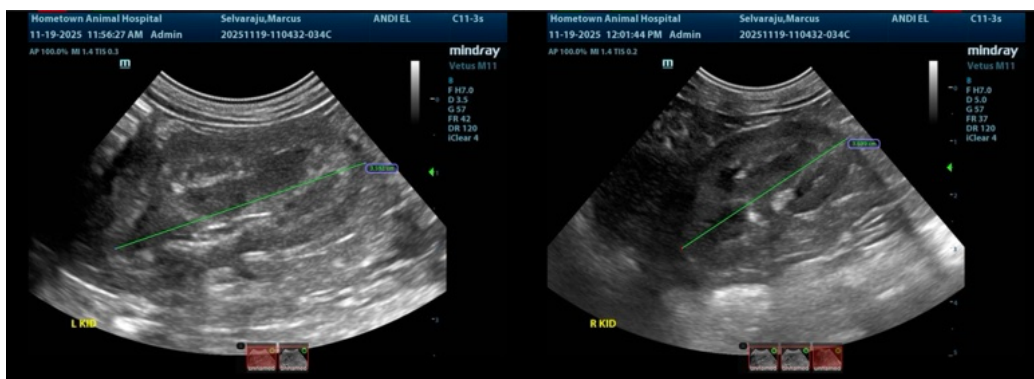
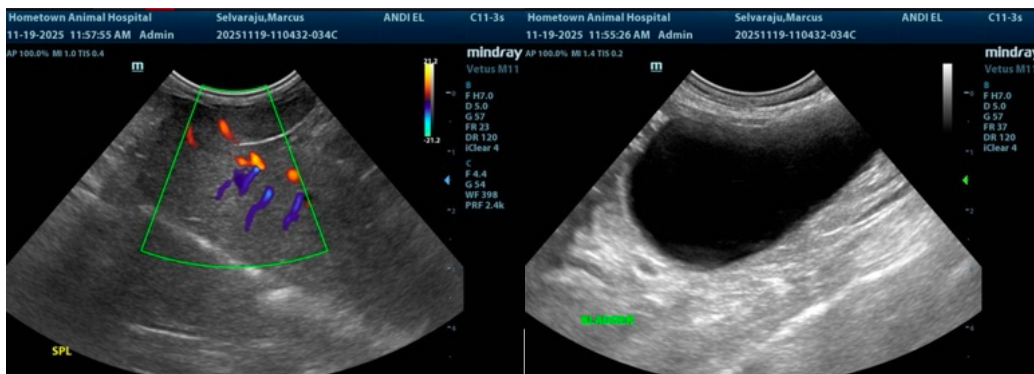
Dr. Hopkins

**INVOICE**

69311

**DATE**

12/3/25





## PATIENT

Marcus Selvaraju

## SPECIES

Canine

## BREED

Chihuahua Mix

## SEX

Neutered male

## AGE

5 years

## WEIGHT

9.25 lbs

## INTERPRETED BY

Eric Lindquist, DMV  
DABVP, Cert. IVUSS

## IMAGING PERFORMED BY

Dr. Casper

## HOSPITAL NAME

Hometown AH Florida

## REFERRING VET

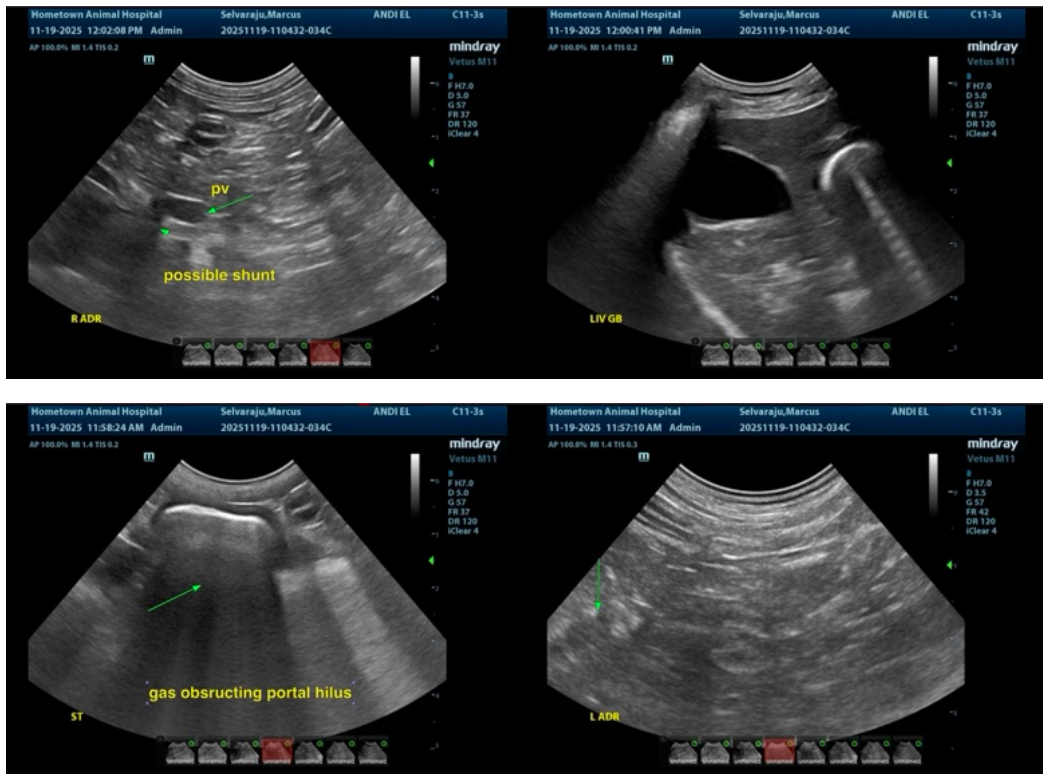
Dr. Hopkins

## INVOICE

69311

## DATE

12/3/25



The information and recommendations provided are based on the images presented by the referring veterinarian/sonographer. No evaluation can be communicated regarding pathology that was not visible in the image/video clips provided.

Thank you for this referral. If the clinical or image interpretation does not parallel your findings or if I can be of any further assistance please contact me.

Eric Lindquist, DMV, DABVP (CFM), Cert. IVUSS, CEO of SonoPath.com

[info@SonoPath.com](mailto:info@SonoPath.com)

## ADDENDUM 12/3/25

11/18/25 Post prandial bile acids were 49.7.

19 videos and 5 still images were submitted:

The liver was persistently of mild subnormal size, yet the portal vein, vena cava ratio was 1:1. The portal vein measured 0.55 cm and vena cava 0.56 cm (SDEP 13 position). Branching of the portal vein appeared to be normal, this would be a negative predicative factor for extrahepatic portosystemic shunting. The intrahepatic approaches revealed adequate parenchymal evacuation to rule out intrahepatic shunts.



## PATIENT

Marcus Selvaraju

## SPECIES

Canine

## BREED

Chihuahua Mix

## SEX

Neutered male

## AGE

5 years

## WEIGHT

9.25 lbs

## INTERPRETED BY

Eric Lindquist, DMV  
DABVP, Cert. IVUSS

## IMAGING PERFORMED BY

Dr, Casper

## HOSPITAL NAME

Hometown AH Florida

## REFERRING VET

Dr. Hopkins

## INVOICE

69311

## DATE

12/3/25

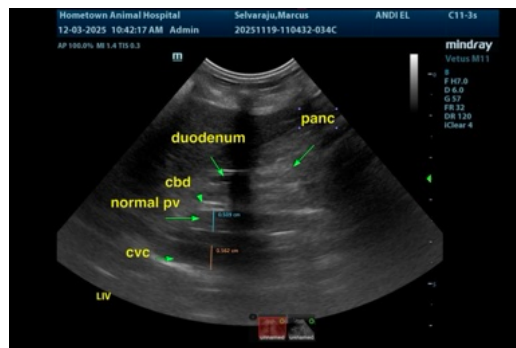
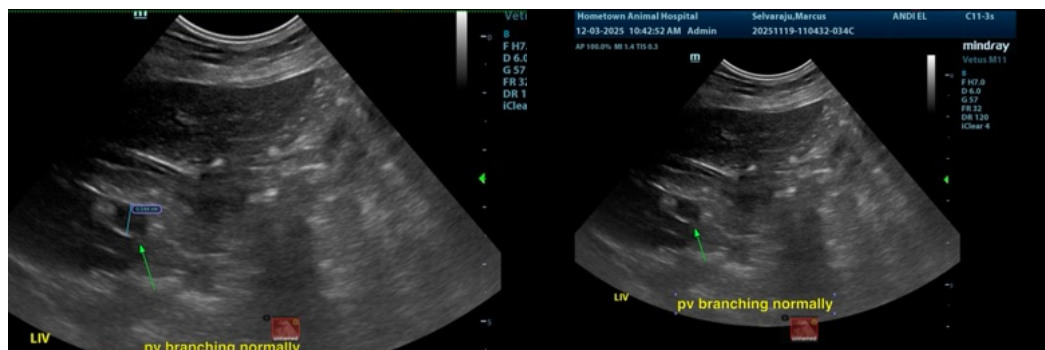## DIAGNOSIS

Microhepatica without macroscopic shunting.

Normal portal vein to vena cava ratio, likely portal hypoplasia or microvascular dysplasia.

## COMMENTS

Liver biopsy is necessary for further definition.



The information and recommendations provided are based on the images presented by the referring veterinarian/sonographer. No evaluation can be communicated regarding pathology that was not visible in the image/video clips provided.

Thank you for this referral. If the clinical or image interpretation does not parallel your findings or if I can be of any further assistance please contact me.

Eric Lindquist, DMV, DABVP (CFM), Cert. IVUSS, CEO of SonoPath.com

[info@SonoPath.com](mailto:info@SonoPath.com)