



## PATIENT

Coco Nazzaro

## SPECIES

Canine

## BREED

Aussie

## SEX

Neutered Male

## AGE

7 Years

## WEIGHT

32 pounds

## INTERPRETED BY

Eric Lindquist, DMV,  
DABVP(CFM), Cert.  
IVUSS

## IMAGING PERFORMED BY

Jenn

## HOSPITAL NAME

Rockaway Animal  
Hospital

## REFERRING VET

Dr. Maniar

## INVOICE

12536

## DATE

12/03/25

## PRESENTING CLINICAL SIGNS

Vomiting, anorexia

Abnormal PE/Chem/CBC/UA Results: WBC 21.94 Lipase 560

## ULTRASONOGRAPHIC EXAMINATION OF THE ABDOMEN

### Urinary System

The **urinary bladder**, trigone, and pelvic urethra (to a depth of 2.0 cm) presented normal thicknesses and normal tone. The ureters were not visible which is normal. No uroliths or sediment were visualized, and anechoic urine was present. No evidence of inflammatory or neoplastic changes were noted. Ureteral papillae were normal.

The **kidneys** revealed normal size and structure, corticomedullary definition and ratio for this age. The cortices presented largely uniform texture with normal echogenic relationship to liver and spleen. Medullary structure differed distinctly from the cortex and no evidence of pelvic dilation was present. The capsules were acceptably uniform without significant irregularities. The left kidney measured 4.73 cm in length. The right kidney measured 5.66 cm in length.

### Adrenal Glands

Both **adrenal glands** were not visualized.

### Spleen

The **spleen** presented slightly enlarged with mild scalloping contour.

### Liver

The **liver** images from right and left intercostal as well as subcostal views revealed subjectively normal liver size, contour, and structure. Some minor age-related parenchymal remodeling was noted but likely not clinically significant at this time. Vascular and biliary tracts were of normal volume, and no evidence of congestion was noted. The gallbladder presented some dependent debris with essentially normal contour. The cystic and common bile ducts were normal. No overt evidence of active inflammatory, infiltrative or regenerative pathology was noted but should be paired with current or past LE elevations regarding any clinical significance to this presentation. The hepatic lymph nodes were unremarkable.

### Gastrointestinal

The **stomach** was empty in this patient. The pylorus was patent. Development of the upper gastrointestinal tract was also noted. The small intestine and colon were unremarkable.

### Pancreas

Regional inflammation was significant around the **pancreas** with areas of hypoechoic ill-defined parenchyma and regional hyperechoic steatitis. Suspect pancreatitis pattern extended for at least 6.0 to 8.0 cm around the right pancreatic base and left pancreatic base extending into the mid limbs of the pancreas. Slight areas of free fluid were noted.

## ULTRASONOGRAPHIC FINDINGS



## PATIENT

Coco Nazzaro

- Extensive pancreatitis.
- Age-related hepatic changes.
- Empty stomach.
- Enlarged spleen.

## SPECIES

Canine

## BREED

Aussie

## SEX

Neutered Male

## AGE

7 Years

## WEIGHT

32 pounds

## INTERPRETED BY

Eric Lindquist, DMV,  
DABVP(CFM), Cert.  
IUUS

## IMAGING PERFORMED BY

Jenn

## HOSPITAL NAME

Rockaway Animal  
Hospital

## REFERRING VET

Dr. Maniar

## INVOICE

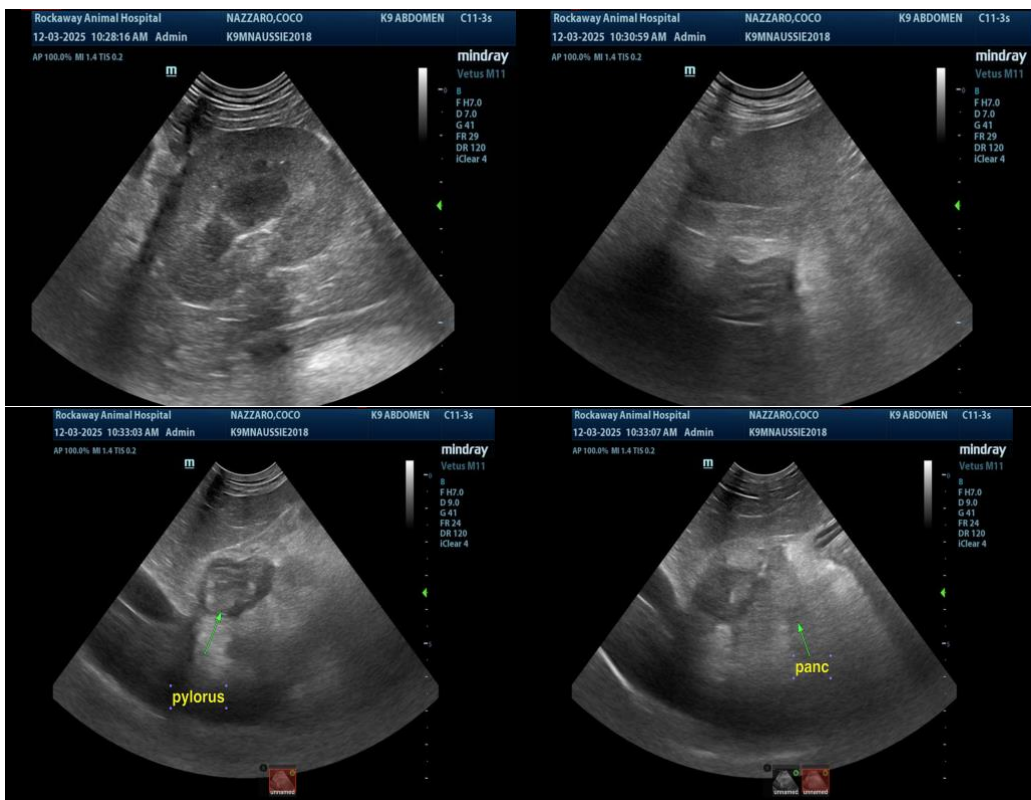
12536

## DATE

12/03/25

## INTERPRETATION OF THE FINDINGS & FURTHER RECOMMENDATIONS

IV fluid support, plasma expanders, pain management and broad spectrum antibiotics are all indicated.





## PATIENT

Coco Nazzaro

## SPECIES

Canine

## BREED

Aussie

## SEX

Neutered Male

## AGE

7 Years

## WEIGHT

32 pounds

## INTERPRETED BY

Eric Lindquist, DMV,  
DABVP(CFM), Cert.  
IVUSS

## IMAGING PERFORMED BY

Jenn

## HOSPITAL NAME

Rockaway Animal  
Hospital

## REFERRING VET

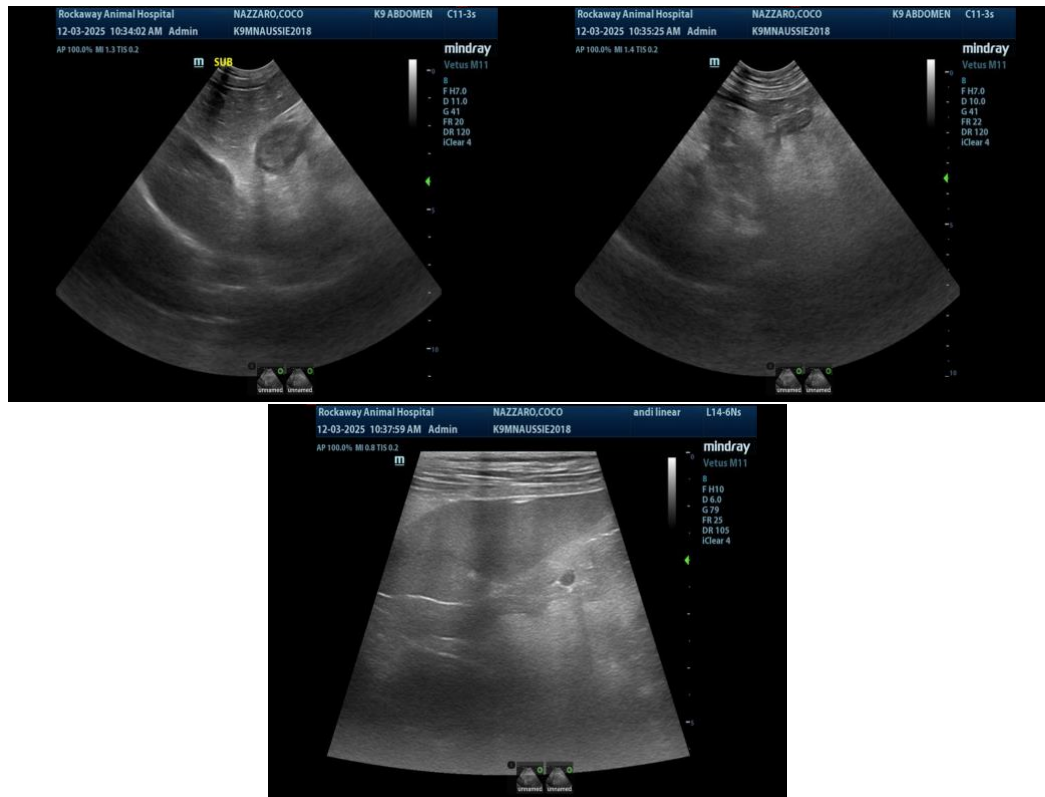Dr. Maniar

## INVOICE

12536

## DATE

12/03/25



The information and recommendations provided are based on the images presented by the referring veterinarian/sonographer. No evaluation can be communicated regarding pathology that was not visible in the image/video clips provided.

Thank you for this referral. If the clinical or image interpretation does not parallel your findings or if I can be of any further assistance, please contact me.

**Eric Lindquist, DMV, DABVP(CFM), Cert. IVUSS,**

CEO, Owner, Founder -- SonoPath.com

[info@SonoPath.com](mailto:info@SonoPath.com)