



## PATIENT

Chloe Vuitton Cornell

## SPECIES

Canine

## BREED

Lab

## SEX

Spayed Female

## AGE

12 Years

## WEIGHT

62.1

## INTERPRETED BY

Eric Lindquist, DMV,  
DABVP (CFM), Cert.  
IVUSS

## IMAGING PERFORMED BY

Dr. Laura Klaassen

## HOSPITAL NAME

Animal Care Group of  
Lake Oswego

## REFERRING VET

Dr. Laura Klaassen

## INVOICE

72302

## DATE

12/3/25

## PRESENTING CLINICAL SIGNS

Pre-anesthetic lab work showed elevated alk p no clinical signs

Abnormal PE/Chem/CBC/UA Results: AKP 1031 all other liver/kidney values normal USG 1.024, 3+ protein

## ULTRASONOGRAPHIC EXAMINATION OF THE ABDOMEN

### Urinary System

The **urinary bladder**, trigone, and pelvic urethra presented normal thicknesses and normal tone. The ureters were not visible which is normal. No uroliths or sediment were visualized and anechoic urine was present. No evidence of inflammatory or neoplastic changes were noted. Ureteral papillae were normal. The pelvic urethra was imaged 2.0 cm beyond the cystourethral junction.

The iliac trifurcation was unremarkable.

The **right kidney** revealed normal size and structure, corticomedullary definition and ratio for this age. The cortices presented largely uniform texture with normal echogenic relationship to liver and spleen. Medullary structure differed distinctly from the cortex and no evidence of pelvic dilation was present. The capsules were acceptably uniform without significant irregularities. Right kidney measured 6.4 cm.

No **left kidney** present.

### Adrenal Glands

Both **adrenal glands** were visualized and recognized as having normal shape, size, position and echogenicity for this breed. The phrenic vasculature, glandular echogenicity and detail were unremarkable. Capsule, cortex, and medullary definition were normal for this age patient. Left adrenal gland measured 0.72 cm. Right adrenal gland measured 0.90 cm at the cranial pole and 0.50 cm at the caudal pole.

### Spleen

The **spleen** was folded upon itself cranially. It presented a smooth homogeneous parenchyma hyperechoic to liver and renal cortical parenchyma. The capsule was smooth without noticeable expansion or deviation from within the spleen or adjacent pathology. The splenic vasculature demonstrated normal volume without signs of congestion or thrombosis. No sonographic evidence of acute or chronic inflammatory, neoplastic, or infarctual changes were noted.

### Liver

The **liver** was uniformly swollen with minor, excessive gallbladder debris and over distension with dependent and suspended bile without evidence of overt mucocele formation. However, excessive sludge was present. The liver presented coarse architecture with mildly increased portal markings and subtle, mixed echogenic changes. This is consistent with vacuolar hepatopathy and some level of remodeling and history of inflammatory component. There was no overt suspicion of neoplasia.

### Gastrointestinal

Examination of the **gastrointestinal tract** revealed a stomach and intestine free of stasis, of normal wall thickness, acceptable curvilinear mural detail, and peristaltic activity. Small and large intestine



## PATIENT

Chloe Vuitton Cornell

## SPECIES

Canine

## BREED

Lab

## SEX

Spayed Female

## AGE

12 Years

## WEIGHT

62.1

## INTERPRETED BY

Eric Lindquist, DMV,  
DABVP (CFM), Cert.  
IVUSS

## IMAGING PERFORMED BY

Dr. Laura Klaassen

## HOSPITAL NAME

Animal Care Group of  
Lake Oswego

## REFERRING VET

Dr. Laura Klaassen

## INVOICE

72302

## DATE

12/3/25

demonstrated normal luminal chyme and stool consistency respectively. No obstructive or overt infiltrative disease was noted. No associated abnormal lymphatic activity was noted.

## Pancreas

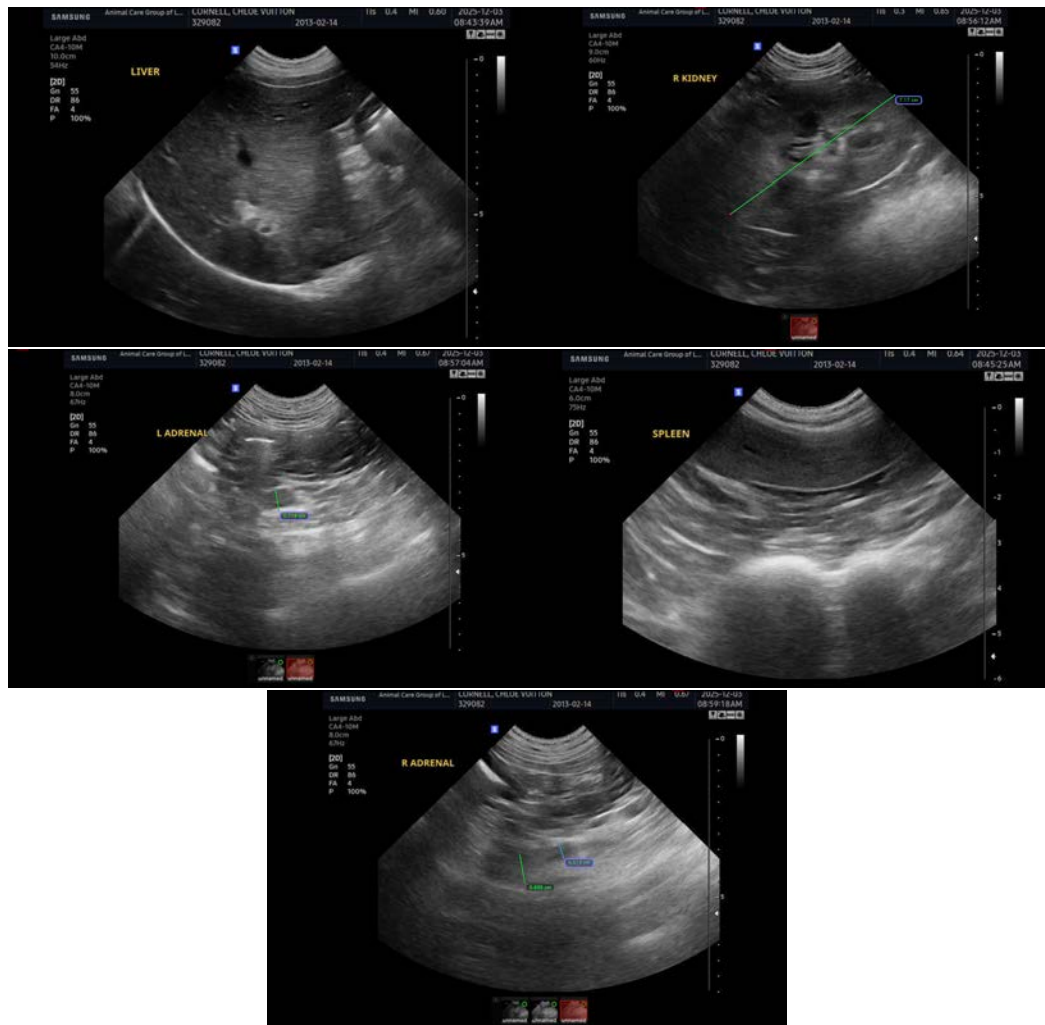
The base and limbs of the **pancreas** were observed to be largely isoechoic to surrounding omental fat. Pancreatic duct and capsular contour were acceptably normal and parenchyma respected normal curvilinear patterns. No overt evidence of active inflammatory or neoplastic disease was noted.

## ULTRASONOGRAPHIC FINDINGS

- Left kidney aplasia.
- Unremarkable abdomen otherwise.

## INTERPRETATION OF THE FINDINGS & FURTHER RECOMMENDATIONS

No evidence of pathology. No contraindication to anesthetic procedure if necessary. Largely age related changes expected for this breed and age.





## PATIENT

Chloe Vuitton Cornell

The information and recommendations provided are based on the images presented by the referring veterinarian/sonographer. No evaluation can be communicated regarding pathology that was not visible in the image/video clips provided.

## SPECIES

Canine

Thank you for this referral. If the clinical or image interpretation does not parallel your findings or if I can be of any further assistance please contact me.

## BREED

Lab

**Eric Lindquist**, DMV, DABVP(CFM), Cert. IVUSS,  
CEO, Owner, Founder -- SonoPath.com  
[info@SonoPath.com](mailto:info@SonoPath.com)

## SEX

Spayed Female

## AGE

12 Years

## WEIGHT

62.1

## INTERPRETED BY

Eric Lindquist, DMV,  
DABVP (CFM), Cert.  
IVUSS

## IMAGING PERFORMED BY

Dr. Laura Klaassen

## HOSPITAL NAME

Animal Care Group of  
Lake Oswego

## REFERRING VET

Dr. Laura Klaassen

## INVOICE

72302

## DATE

12/3/25