



PATIENT

Charlie Sermon

SPECIES

Canine

BREED

Min Pin

SEX

Neutered Male

AGE

8

WEIGHT

18.8

INTERPRETED BY

Eric Lindquist, DMV,
DABVP(CFM), Cert.
IVUSS

IMAGING PERFORMED BY

Jenn

HOSPITAL NAME

Rockaway Animal
Hospital

REFERRING VET

Dr. Dubos

INVOICE

12539

DATE

12/03/25

PRESENTING CLINICAL SIGNS

New murmur 4/6 L sided apcal HM coughing 1.4lb weight loss coombs pending

Abnormal PE/Chem/CBC/UA Results: Platelets low 72 ALT 129 4dx neg

ULTRASONOGRAPHIC EXAMINATION OF THE HEART & ABDOMEN

CANINE CARDIAC PARAMETERS	MR VMAX (m/s)	TR VMAX (m/s)	LA/AO (M-Mode)	LA/AO (Heart Base; Swe)	FS (%)	EF (%)	EPSS (cm)
NORMAL PARAMETER	4.5-5.5	<2.7	1.3	Up to 1.6	28-40	40-100	<0.6
PATIENT	6.0	--	1.1	1.3	42	76	NM
CANINE CARDIAC PARAMETERS	HR (BPM)	AV VMAX (m/s)	PV MAX (m/s)	BODY WEIGHT (kg)	LAD LA MAX 4 Chamber	LVIDd Avg; 2D and m-mode short axis (cm)	LVIDs Avg; 2D and m-mode short axis (cm)
NORMAL PARAMETER	50-100	0.7-1.7	0.7-1.6				
PATIENT	142	1.5	1.1	--	2.3	2.4	--

Cardiac Presentation

The echocardiogram in this patient demonstrated normal **left atrial** size based on 3 different LA measurement methods. Chamber volumes and echogenicity were normal. The cranial and caudal **mitral** valve leaflets presented vegetative thickening consistent with endocardiosis. Doppler indicated measurable insufficiency. The **left ventricle** presented normal thicknesses with linear contour and was not dilated nor restricted. The **myocardium** presented normal echogenicity without subjective evidence of significant fibrotic or ischemic disease. **Contractility** of the ventricular walls was adequate and in normal range for this patient evidenced by the fractional shortening measurement and subjective evaluation of the different regions of the myocardium. The **left ventricular outflow** tract demonstrated normal laminar flow and subjective structural integrity. The **right atrium** and auricle revealed normal size, structure and content. No evidence of masses was noted or chamber overload. **Tricuspid** valvular assessment demonstrated adequate linear morphology. The **right ventricle** was of normal size (1/3 diameter of LV), chordae structure, myocardial echogenicity and thickness. **Pulmonic** tract assessment revealed normal valve structure, laminar flow, and diameter (approx.1:1 pa/ao ratio). No visible **pericardial** or free pleura fluid was noted. No echographically detectable evidence of infiltrative disease was visible. The cranial **mediastinum and pericardial regions** were free of masses in the visible window.

Urinary System

The **urinary bladder**, trigone, and pelvic urethra (to a depth of 2.0 cm) presented normal thicknesses and normal tone. The ureters were not visible which is normal. No uroliths or sediment were



PATIENT

Charlie Sermon

SPECIES

Canine

BREED

Min Pin

SEX

Neutered Male

AGE

8

WEIGHT

18.8

INTERPRETED BY

Eric Lindquist, DMV,
DABVP(CFM), Cert.
IVUSS

IMAGING PERFORMED BY

Jenn

HOSPITAL NAME

Rockaway Animal
Hospital

REFERRING VET

Dr. Dubos

INVOICE

12539

DATE

12/03/25

visualized, and anechoic urine was present. No evidence of inflammatory or neoplastic changes were noted. Ureteral papillae were normal.

The **kidneys** revealed largely normal size and structure, corticomedullary definition and ratio (cortex 1/3 of medulla) were essentially maintained with some age-related loss of curvilinear patterns regarding the capsule and C/M junction. The cortices presented largely uniform texture with some increased echogenicity expected for his age patient. Medullary structure differed distinctly from that of the cortex. Slight mineralizations were noted bilaterally. The left kidney measured 4.05 cm in length. The right kidney measured 3.94 cm in length.

Adrenal Glands

Both **adrenal glands** were visualized and recognized as having normal shape, size, position and echogenicity for this breed. The phrenic vasculature, glandular echogenicity and detail were unremarkable. Capsule, cortex, and medullary definition were normal for this age patient. The left adrenal gland measured 1.5 cm x 0.42 cm width at the caudal pole and 0.51 cm width at the cranial pole. The right adrenal gland measured 1.7 cm x 0.66 cm width at the caudal pole and 0.78 cm width at the cranial pole.

Spleen

The **spleen** presented a smooth homogeneous parenchyma hyperechoic to liver and renal cortical parenchyma. The capsule was smooth without noticeable expansion or deviation from within the spleen or adjacent pathology. The splenic vasculature demonstrated normal volume without signs of congestion or thrombosis. No sonographic evidence of acute or chronic inflammatory, neoplastic, or infarctual changes were noted.

Liver

The **liver** images submitted revealed subjectively normal liver size, contour, and structure. Parenchymal echogenicity was naturally coarse and hypoechoic to the spleen. Vascular and biliary tracts were of normal volume with no evidence of congestion. The gallbladder presented acceptably thin walls with primarily anechoic content. The cystic and common bile ducts were normal. No pathological hepatic lymphadenopathy was evident. No overt structural evidence of inflammatory, infiltrative or regenerative pathology was evident.

Gastrointestinal

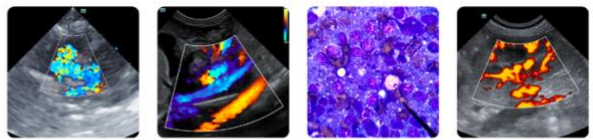
The **stomach** revealed retention of ingesta in the pyloric antrum. The small intestine and colon were unremarkable.

Pancreas

The base and limbs of the **pancreas** were observed to be largely isoechoic to surrounding omental fat. Pancreatic duct and capsular contour were acceptably normal and parenchyma respected normal curvilinear patterns. No overt evidence of active inflammatory or neoplastic disease was noted.

ULTRASONOGRAPHIC FINDINGS

- Stage B1 valvular disease.
- Age-related renal changes with slight mineralization.
- Mild delayed outflow gastric pattern.



PATIENT

Charlie Sermon

SPECIES

Canine

BREED

Min Pin

SEX

Neutered Male

AGE

8

WEIGHT

18.8

INTERPRETED BY

Eric Lindquist, DMV,
DABVP(CFM), Cert.
IVUSS

IMAGING PERFORMED BY

Jenn

HOSPITAL NAME

Rockaway Animal
Hospital

REFERRING VET

Dr. Dubos

INVOICE

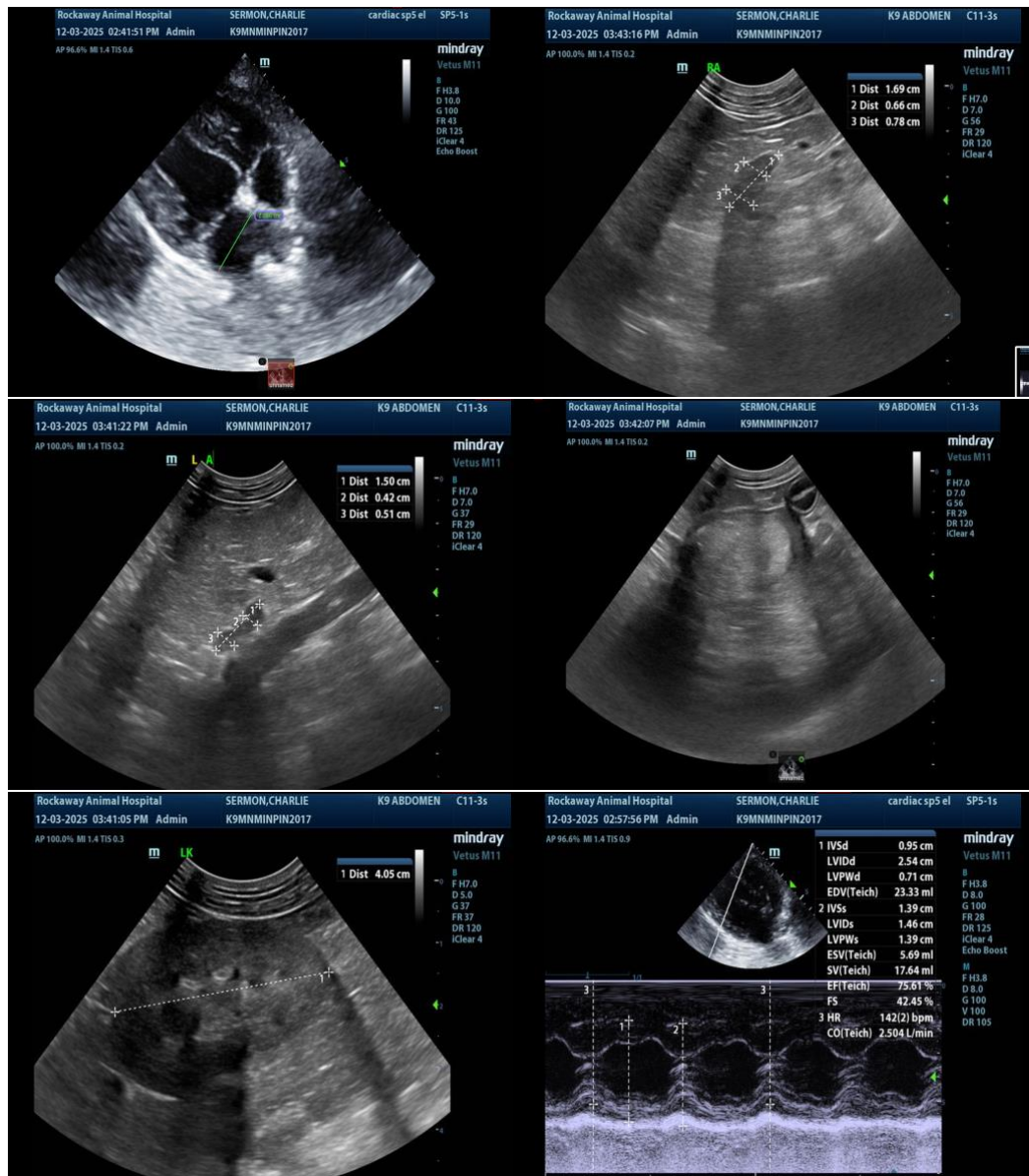
12539

DATE

12/03/25

INTERPRETATION OF THE FINDINGS & FURTHER RECOMMENDATIONS

The cause of the weight loss is unclear. Maldigestion panel, three view chest radiographs and full CNS examination is recommended to examine for occult disease that could be responsible for the weight loss. Evaluation for competitive eating environments should also be considered.





PATIENT

Charlie Sermon

SPECIES

Canine

BREED

Min Pin

SEX

Neutered Male

AGE

8

WEIGHT

18.8

INTERPRETED BY

Eric Lindquist, DMV,
DABVP(CFM), Cert.
IVUSS

**IMAGING
PERFORMED BY**

Jenn

HOSPITAL NAME

Rockaway Animal
Hospital

REFERRING VET

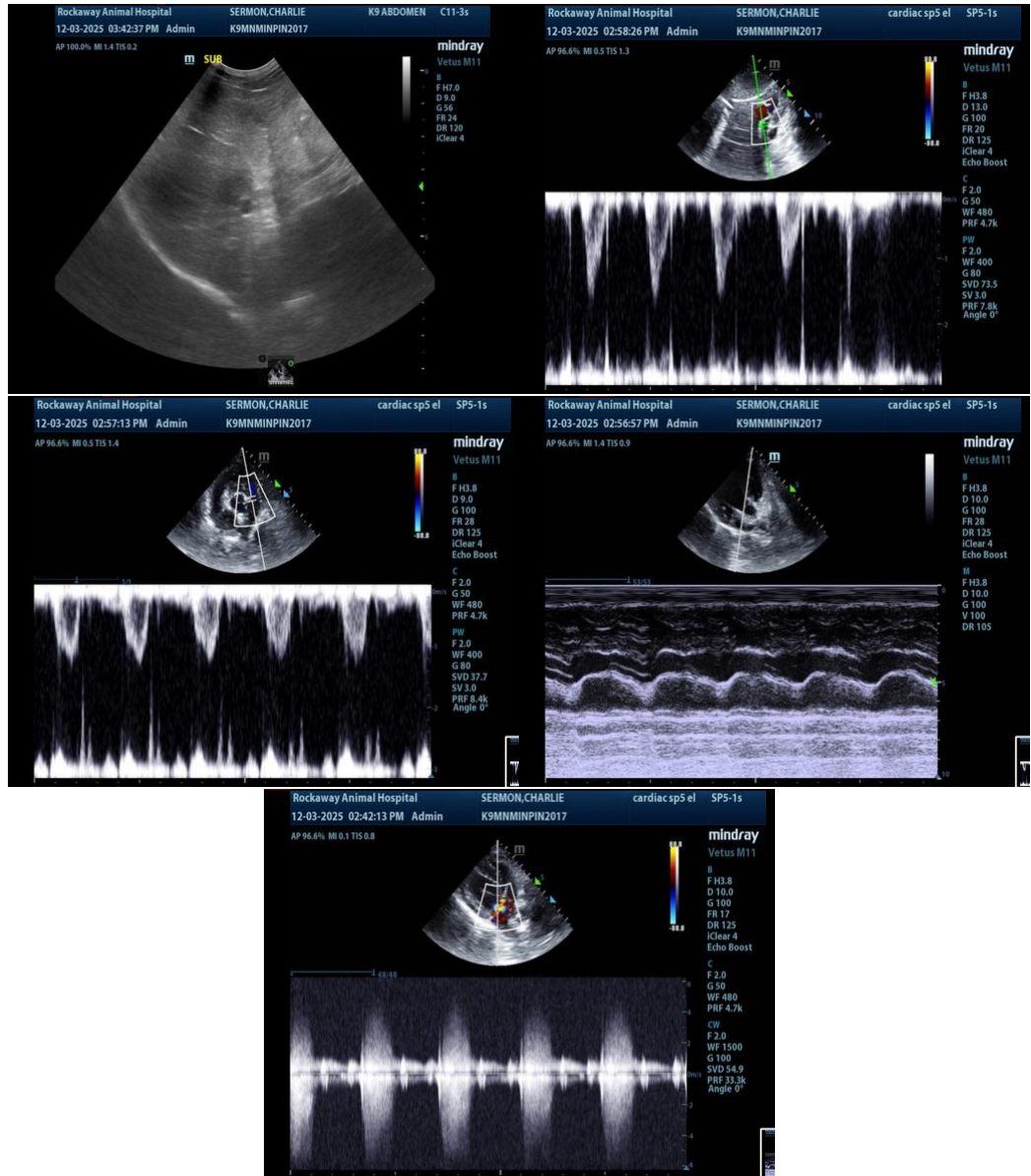
Dr. Dubos

INVOICE

12539

DATE

12/03/25



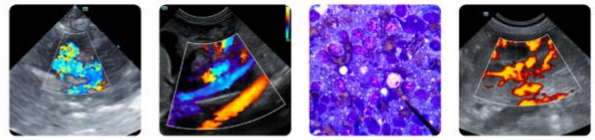
The information and recommendations provided are based on the images presented by the referring veterinarian/sonographer. No evaluation can be communicated regarding pathology that was not visible in the image/video clips provided.

Thank you for this referral. If the clinical or image interpretation does not parallel your findings or if I can be of any further assistance, please contact me.

Eric Lindquist, DMV, DABVP(CFM), Cert. IVUSS,

CEO, Owner, Founder -- SonoPath.com

info@SonoPath.com



PATIENT

Charlie Sermon

SPECIES

Canine

BREED

Min Pin

SEX

Neutered Male

AGE

8

WEIGHT

18.8

INTERPRETED BY

Eric Lindquist, DMV,
DABVP(CFM), Cert.
IVUSS

IMAGING PERFORMED BY

Jenn

HOSPITAL NAME

Rockaway Animal
Hospital

REFERRING VET

Dr. Dubos

INVOICE

12539

DATE

12/03/25