

**DATE PRESENTING CLINICAL SIGNS**

12/3/21 History: follow up scan, positive cadet braf test.

**PATIENT**

Reggie Newman

Current Medications: Gabapentin 200mg q 8hrs, Piroxicam.  
 Date of Previous IntraPet Ultrasound: 8-6-21 & 6-22-21.  
 Sedation: Not required to complete full diagnostic ultrasound.  
 Stat Report: Not requested.

**SPECIES**

Canine

**BREED**

Mixed Breed

**SEX**

Neutered Male

**AGE**

10/30/2009

**WEIGHT**

23 Lbs.

**INTERPRETED BY**Eric Lindquist, DMV  
DABVP, Cert. IVUSS**IMAGING PERFORMED BY**

Rachel Brillhart RDMS

**HOSPITAL NAME**

Companion ACC

**REFERRING VET**

Dr. Johnston

**INVOICE**

12835

**LIMITED ULTRASONOGRAPHIC EXAMINATION OF THE URINARY SYSTEM**

The urinary bladder presented anechoic urine and normal wall thickness. The bladder wall measured 0.32 cm at minimal repletion. Trace concretions noted (up to 1.0 mm).

The prostate was uniform, measuring 1.29 cm.

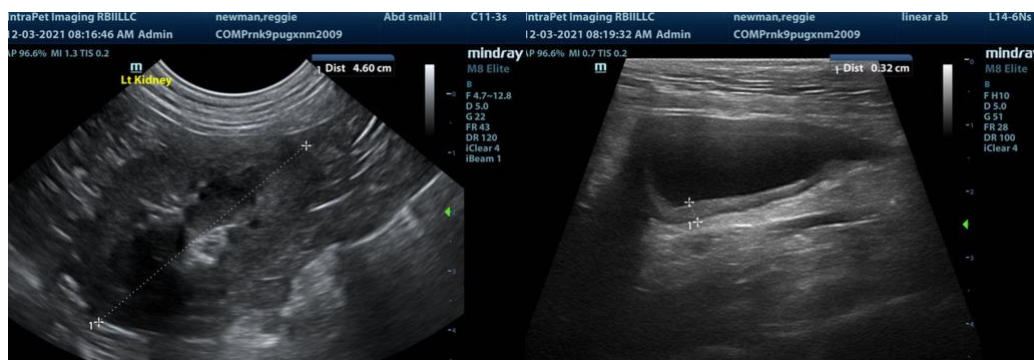
The kidneys revealed minor degenerative changes. The right kidney measured 4.63 cm. The left kidney measured 4.6 cm. Trace mineralization was note din the kidneys, non-obstructive.

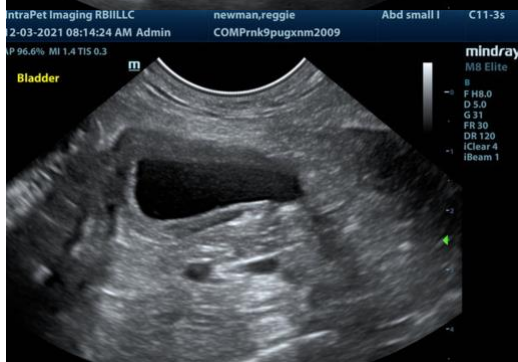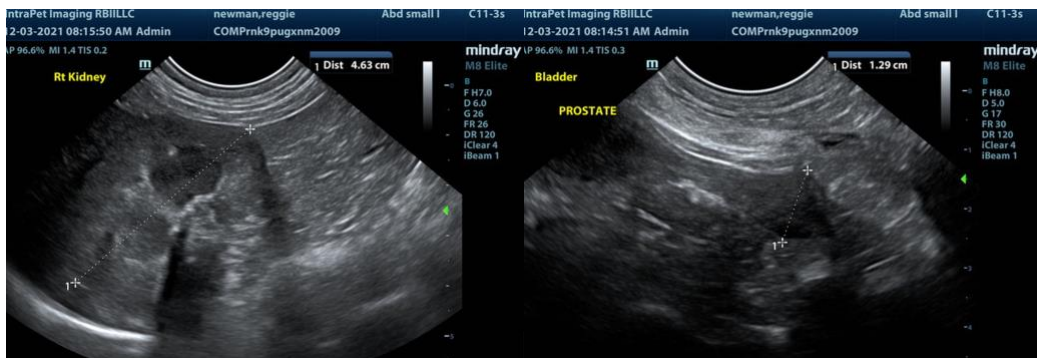
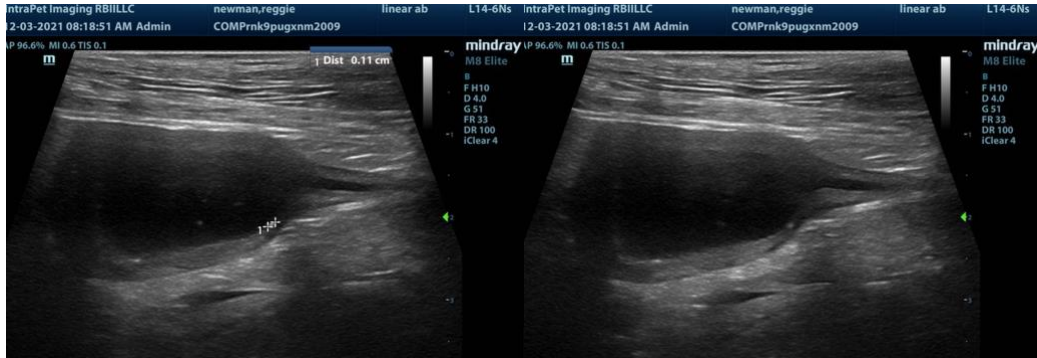**ULTRASONOGRAPHIC FINDINGS**

- Trace bladder concretion
- Age-related renal changes with trace mineralization

**INTERPRETATION OF THE FINDINGS & FURTHER RECOMMENDATIONS**

No evidence of significant disease. Treatment/management should be based on urinalysis results.





The information and recommendations provided are based on the images presented by the referring veterinarian. No evaluation can be communicated regarding pathology that was not visible in the image/video clips provided.

Thank you for this referral. If the clinical or image interpretation does not parallel your findings or if I can be of any further assistance please contact me.

**Eric Lindquist**, DMV, DABVP, Cert. IVUSS, CEO of SonoPath.com  
 Eric.Lindquist@SonoPath.com