



**PATIENT**

Cami Battaglino

**SPECIES**

Canine

**BREED**

Beagle Mix

**SEX**

Spayed Female

**AGE**

12

**WEIGHT**

43

**INTERPRETED BY**

Eric Lindquist, DMV,  
DABVP(CFM), Cert.  
IVUSS

**IMAGING PERFORMED BY**

Jenn

**HOSPITAL NAME**

Rockaway Animal  
Hospital

**REFERRING VET**

Dr. Maniar

**INVOICE**

12843

**DATE**

12/29/25

**PRESENTING CLINICAL SIGNS**

Bloody diarrhea, coughing had prev abd u/s 12/4

Abnormal PE/Chem/CBC/UA Results: BUN 40 ALP 235 Lipase 501

**ULTRASONOGRAPHIC EXAMINATION OF THE HEART & ABDOMEN**

CANINE CARDIAC PARAMETERS	MR VMAX (m/s)	TR VMAX (m/s)	LA/AO (M-Mode)	LA/AO (Heart Base; Swe)	FS (%)	EF (%)	EPSS (cm)
NORMAL PARAMETER	4.5-5.5	<2.7	1.3	Up to 1.6	28-40	40-100	<0.6
PATIENT	--	--	1.0	1.4	45	90	0.3
CANINE CARDIAC PARAMETERS	HR (BPM)	AV VMAX (m/s)	PV MAX (m/s)	BODY WEIGHT (kg)	LAD LA MAX 4 Chamber	LVIDd Avg; 2D and m-mode short axis (cm)	LVIDs Avg; 2D and m-mode short axis (cm)
NORMAL PARAMETER	50-100	0.7-1.7	0.7-1.6				
PATIENT	80	--	--	--	3.1	2/3	--

**Cardiac Presentation**

The echocardiogram in this patient demonstrated normal **left atrial** size based on 3 separate methods of LA evaluation. The cranial and caudal **mitral** valve leaflets presented normal linear structure, extension in systole, and union in diastole with normal kinesis. The **left ventricle** presented normal thicknesses with linear contour and was not dilated nor restricted. The **myocardium** presented normal echogenicity without subjective evidence of significant fibrotic or ischemic disease. **Contractility** of the ventricular walls was adequate and in normal range for this patient evidenced by the fractional shortening measurement and subjective evaluation of the different regions of the myocardium. The **left ventricular outflow** tract demonstrated normal laminar flow and subjective structural integrity. The **right atrium** and auricle revealed normal size, structure and content. No evidence of masses was noted. **Tricuspid** valvular assessment demonstrated adequate linear morphology and kinesis. The **right ventricle** was of normal size (1/3 diameter of LV), chordae structure, myocardial echogenicity and thickness. **Pulmonary outflow** tract assessment revealed normal valve structure, laminar flow, and diameter (approx.1:1 pa/ao ratio). No visible **pericardial** or free pleura fluid was noted. The cranial **mediastinum** and **pericardial** and **extra-cardiac** regions were free of masses in the visible window.

**Urinary System**

The **urinary bladder**, trigone, and pelvic urethra presented normal thicknesses and normal tone. The ureters were not visible which is normal. No uroliths or sediment were visualized, and anechoic urine was present. No evidence of inflammatory or neoplastic changes were noted. Ureteral papillae were normal.



## PATIENT

Cami Battaglino

## SPECIES

Canine

## BREED

Beagle Mix

## SEX

Spayed Female

## AGE

12

## WEIGHT

43

## INTERPRETED BY

Eric Lindquist, DMV,  
DABVP(CFM), Cert.  
IVUSS

## IMAGING PERFORMED BY

Jenn

## HOSPITAL NAME

Rockaway Animal  
Hospital

## REFERRING VET

Dr. Maniar

## INVOICE

12843

## DATE

12/29/25

The **kidneys** revealed largely normal size and structure, corticomedullary definition and ratio (cortex 1/3 of medulla) were essentially maintained with some age-related loss of curvilinear patterns regarding the capsule and C/M junction. The cortices presented largely uniform texture with some increased echogenicity expected for his age patient. Medullary structure differed distinctly from that of the cortex. Slight mineralizations were noted bilaterally. The left kidney measured 5.8 cm in length. The right kidney measured 6.0 cm in length.

### **Adrenal Glands**

Both **adrenal glands** were visualized and recognized as having normal shape, size, position and echogenicity for this breed. The phrenic vasculature, glandular echogenicity and detail were unremarkable. Capsule, cortex, and medullary definition were normal for this age patient. The left adrenal gland measured 2.22 cm x 0.56 cm width at the caudal pole and 0.58 cm width at the cranial pole.

### **Spleen**

The **spleen** presented a smooth homogeneous parenchyma hyperechoic to liver and renal cortical parenchyma. The capsule was smooth without noticeable expansion or deviation from within the spleen or adjacent pathology. The splenic vasculature demonstrated normal volume without signs of congestion or thrombosis. No sonographic evidence of acute or chronic inflammatory, neoplastic, or infarctual changes were noted.

### **Liver**

The **liver** was uniformly swollen with minor, excessive gallbladder debris and over distension with dependent and suspended bile without evidence of overt mucocele formation. However, excessive sludge was present. The liver presented coarse architecture with mildly increased portal markings and subtle, mixed echogenic changes. This is consistent with vacuolar hepatopathy and some level of remodeling and history of inflammatory component. There was no overt suspicion of neoplasia.

### **Gastrointestinal**

Examination of the **gastrointestinal tract** revealed a stomach and intestine free of stasis, of normal wall thickness, acceptable curvilinear mural detail, and peristaltic activity. Small and large intestine demonstrated normal luminal chyme and stool consistency respectively. No obstructive or overt infiltrative disease was noted. No associated abnormal lymphatic activity was noted.

### **Pancreas**

The base and limbs of the **pancreas** were observed to be largely isoechoic to surrounding omental fat. Pancreatic duct and capsular contour were acceptably normal and parenchyma respected normal curvilinear patterns. No overt evidence of active inflammatory or neoplastic disease was noted.

## **ULTRASONOGRAPHIC FINDINGS**

- Normal echocardiogram.
- Structurally unremarkable abdomen with largely age-related changes.
- Benign hepatopathy.

## **INTERPRETATION OF THE FINDINGS & FURTHER RECOMMENDATIONS**

The cough in this patient is noncardiogenic in origin. No evidence of significant disease was present.



**PATIENT**

Cami Battaglino

**SPECIES**

Canine

**BREED**

Beagle Mix

**SEX**

Spayed Female

**AGE**

12

**WEIGHT**

43

**INTERPRETED BY**

Eric Lindquist, DMV,  
DABVP(CFM), Cert.  
IVUSS

**IMAGING PERFORMED BY**

Jenn

**HOSPITAL NAME**

Rockaway Animal  
Hospital

**REFERRING VET**

Dr. Maniar

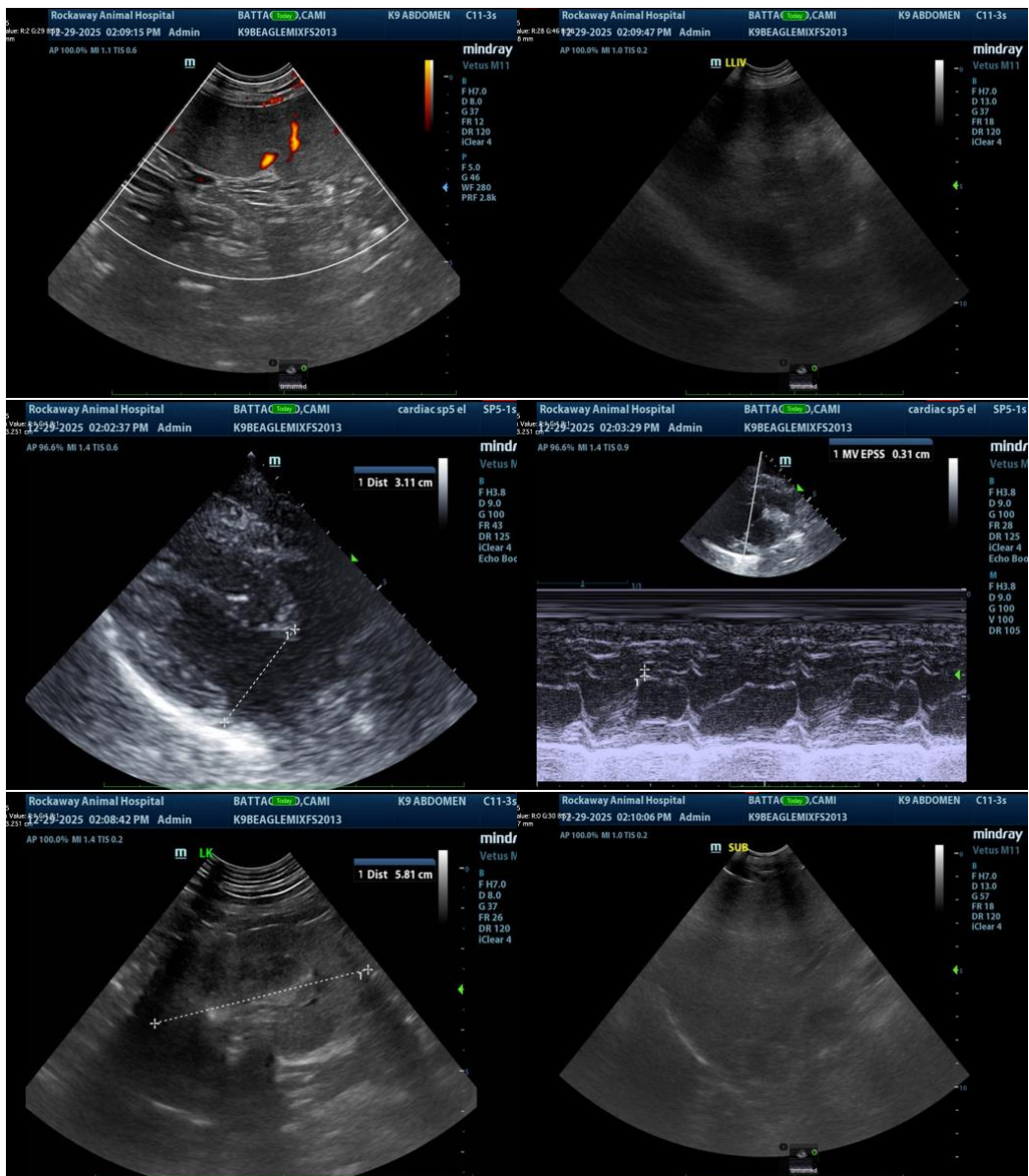
**INVOICE**

12843

**DATE**

12/29/25

Differentials for diarrhea include occult parasitism, dietary indiscretion, dietary intolerance, antibiotic responsive colitis, intestinal dysbiosis and occult Addison's should all be considered as causes of diarrhea in this patient. A hydrolyzed diet trial may be in this patient's best interest +/- probiotics. 24-hour NPO and reintroduction of bland diet indicated. I recommend a baseline cortisol or ACTH stimulation test, a fresh fecal smear and fecal floatation analysis if not already performed. Note that recent research has shown that indiscriminate use of antibiotics may actually cause harm. Most acute cases of diarrhea will respond to probiotic therapy, fiber, and gastrointestinal diets over the next 3-5 days.





**PATIENT**

Cami Battaglino

**SPECIES**

Canine

**BREED**

Beagle Mix

**SEX**

Spayed Female

**AGE**

12

**WEIGHT**

43

**INTERPRETED BY**

Eric Lindquist, DMV,  
DABVP(CFM), Cert.  
IVUSS

**IMAGING  
PERFORMED BY**

Jenn

**HOSPITAL NAME**

Rockaway Animal  
Hospital

**REFERRING VET**

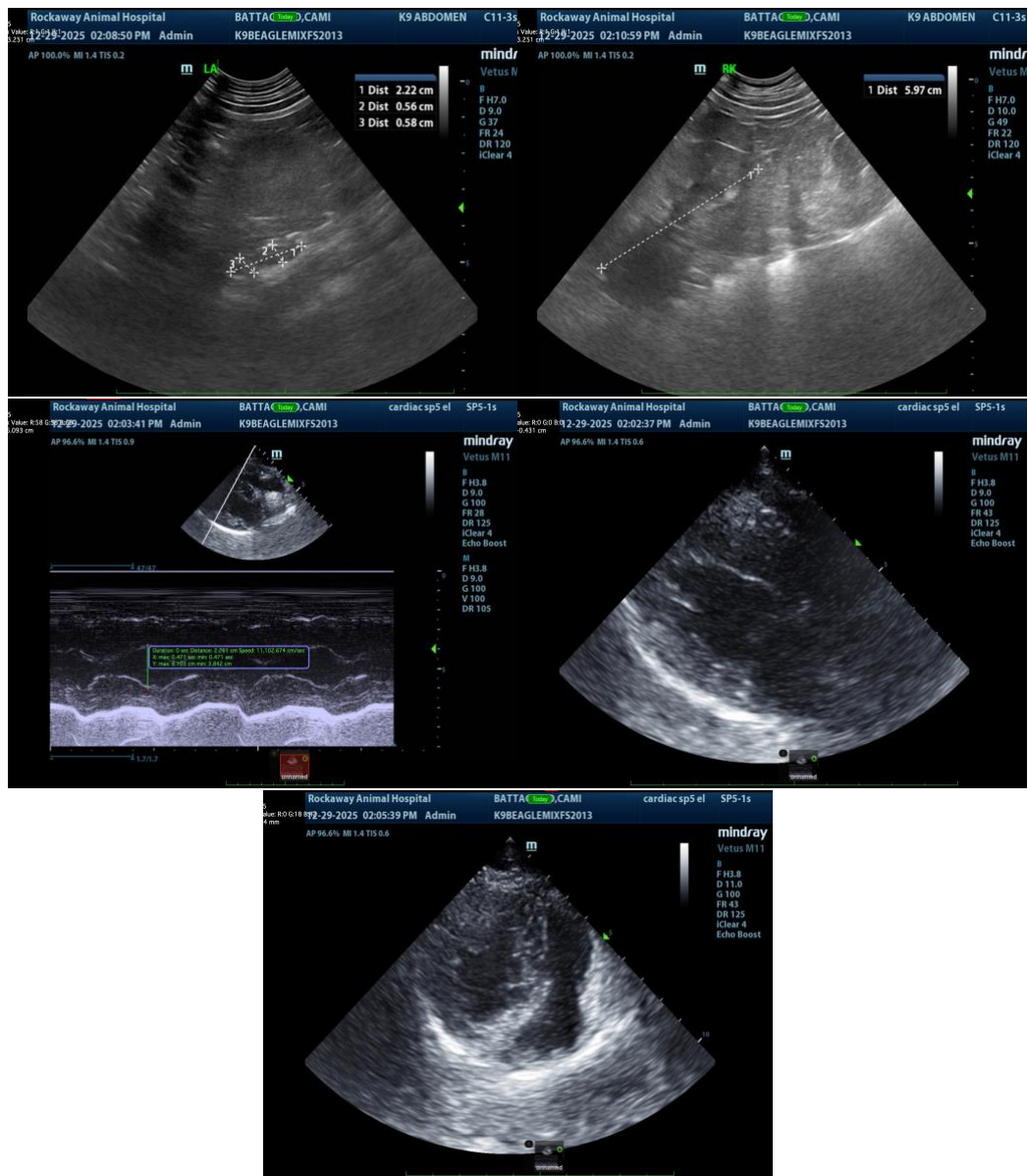
Dr. Maniar

**INVOICE**

12843

**DATE**

12/29/25



The information and recommendations provided are based on the images presented by the referring veterinarian/sonographer. No evaluation can be communicated regarding pathology that was not visible in the image/video clips provided.

Thank you for this referral. If the clinical or image interpretation does not parallel your findings or if I can be of any further assistance, please contact me.

Eric Lindquist, DMV, DABVP(CFM), Cert. IVUSS,

CEO, Owner, Founder -- SonoPath.com

[info@SonoPath.com](mailto:info@SonoPath.com)



## PATIENT

Cami Battaglino

## SPECIES

Canine

## BREED

Beagle Mix

## SEX

Spayed Female

## AGE

12

## WEIGHT

43

## INTERPRETED BY

Eric Lindquist, DMV,  
DABVP(CFM), Cert.  
IVUSS

## IMAGING PERFORMED BY

Jenn

## HOSPITAL NAME

Rockaway Animal  
Hospital

## REFERRING VET

Dr. Maniar

## INVOICE

12843

## DATE

12/29/25