



PATIENT

Big Fat Tony Feuer

SPECIES

Feline

BREED

Domestic Shorthair

SEX

Neutered male

AGE

14 years

WEIGHT

7.2 lbs

INTERPRETED BY

Eric Lindquist, DMV
DABVP, Cert. IVUSS

IMAGING PERFORMED BY

Michelle Roche

HOSPITAL NAME

Fredon AH

REFERRING VET

Dr. Roche

INVOICE

69641

DATE

12/29/25

PRESENTING CLINICAL SIGNS

History: Not eating, weight loss
Abnormal PE/Chem/CBC/UA Results: Jaundice, BCS 3/9, severe dehydration. bw unremarkable 11/12/25.

ULTRASONOGRAPHIC EXAMINATION OF THE ABDOMEN

Urinary System

The **urinary bladder**, trigone, and pelvic urethra presented normal thicknesses and normal tone. The ureters were not visible which is normal. No uroliths or sediment were visualized and anechoic urine was present. No evidence of inflammatory or neoplastic changes was noted. Ureteral papillae were normal.

The **kidneys** revealed largely normal size and structure, corticomedullary definition and ratio (cortex 1/3 of medulla) were essentially maintained with some age-related loss of curvilinear patterns regarding the capsule and C/M junction. The cortices presented largely uniform texture with some increased echogenicity expected for this age patient. Medullary structure differed distinctly from that of the cortex and no evidence of pelvic dilation was present. The left kidney measured 4.26 cm. The right kidney measured 4.75 cm.

Adrenal Glands

Both **adrenal glands** were visualized and recognized as having normal shape, size, position and echogenicity for this breed. The phrenic vasculature, glandular echogenicity and detail were unremarkable. Capsule, cortex, and medullary definition were normal for this age patient.

Spleen

The **spleen** in this patient was uniform, yet volume contracted. Hydration status should be assessed.

Liver

The **liver** revealed multiple, hepatic masses with severe, irregular hepatomegaly and nodular changes. The gallbladder presented acceptably thin walls with primarily anechoic content. The cystic and common bile ducts were normal. No pathological hepatic lymphadenopathy was evident.

Gastrointestinal

Examination of the **gastrointestinal tract** revealed a stomach and intestine free of stasis, of normal wall thickness, acceptable curvilinear mural detail, and peristaltic activity. Small and large intestine demonstrated normal luminal chyme and stool consistency respectively. No obstructive or overt infiltrative disease was noted. No associated abnormal lymphatic activity was noted.



PATIENT

Big Fat Tony Feuer

SPECIES

Feline

BREED

Domestic Shorthair

SEX

Neutered male

AGE

14 years

WEIGHT

7.2 lbs

INTERPRETED BY

Eric Lindquist, DMV
DABVP, Cert. IVUSS

IMAGING PERFORMED BY

Michelle Roche

HOSPITAL NAME

Fredon AH

REFERRING VET

Dr. Roche

INVOICE

69641

DATE

12/29/25

Pancreas

The **pancreas** revealed pancreatic edema was noted, yet no primary pancreatic pathology was noted.

Free Abdomen

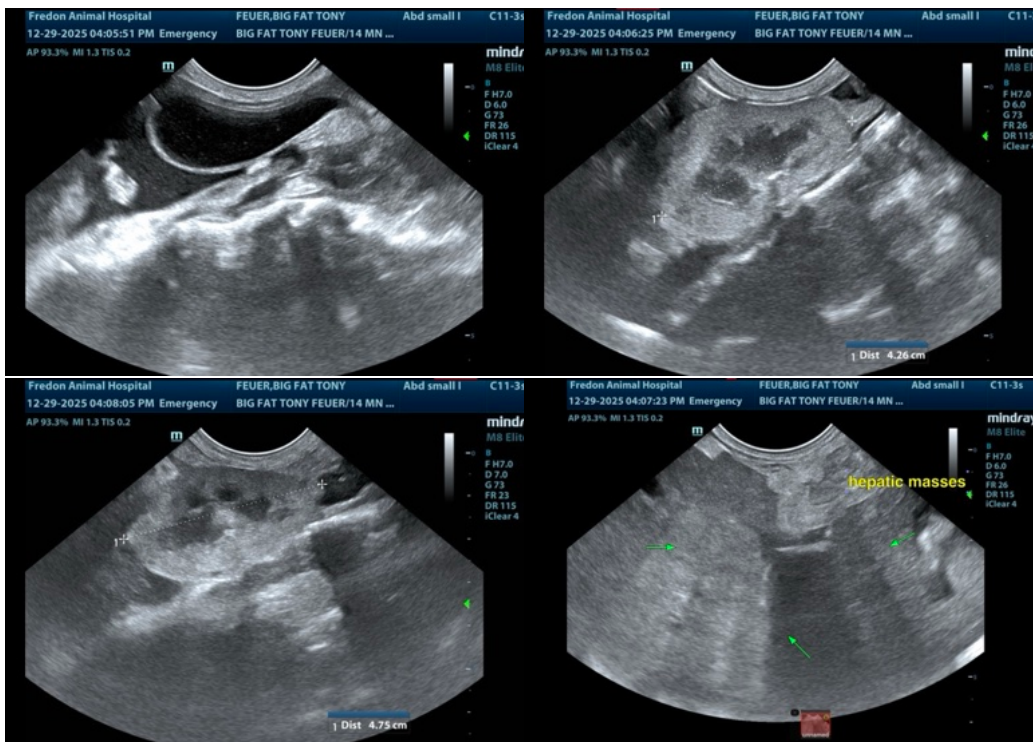
A large amount of echogenic fluid was noted in the midabdomen.

ULTRASONOGRAPHIC FINDINGS

Diffuse hepatic neoplasia with secondary ascites owing to portal hypertension or paraneoplastic effusion.

INTERPRETATION OF THE FINDINGS & FURTHER RECOMMENDATIONS

The prognosis is poor. Humane euthanasia should be considered in this patient or hospice management.





PATIENT

Big Fat Tony Feuer

SPECIES

Feline

BREED

Domestic Shorthair

SEX

Neutered male

AGE

14 years

WEIGHT

7.2 lbs

INTERPRETED BY

Eric Lindquist, DMV
DABVP, Cert. IVUSS

IMAGING PERFORMED BY

Michelle Roche

HOSPITAL NAME

Fredon AH

REFERRING VET

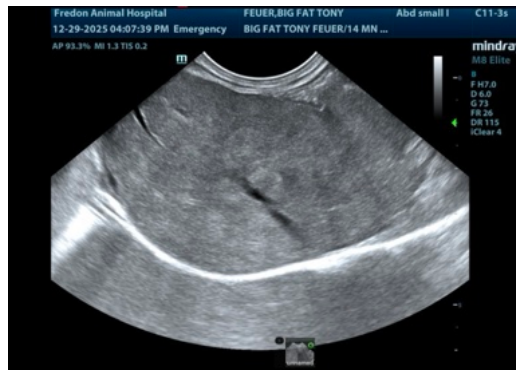Dr. Roche

INVOICE

69641

DATE

12/29/25



The information and recommendations provided are based on the images presented by the referring veterinarian/sonographer. No evaluation can be communicated regarding pathology that was not visible in the image/video clips provided.

Thank you for this referral. If the clinical or image interpretation does not parallel your findings or if I can be of any further assistance please contact me.

Eric Lindquist, DMV, DABVP (CFM), Cert. IVUSS, CEO of SonoPath.com

info@SonoPath.com