



PATIENT

Jitters Porter

PRESENTING CLINICAL SIGNS

Hx of not eating normally for her, weight loss, chronic renal failure stage 1
Abnormal PE/Chem/CBC/UA Results: sending off today snap ProBNP: WNL

SPECIES

Feline

ULTRASONOGRAPHIC EXAMINATION OF THE ABDOMEN

Urinary System

BREED

DSH

The **urinary bladder**, trigone, and pelvic urethra presented normal thicknesses and normal tone. The ureters were not visible which is normal. No uroliths or sediment were visualized and anechoic urine was present. No evidence of inflammatory or neoplastic changes were noted. Ureteral papillae were normal.

SEX

Spayed Female

The **kidneys** revealed largely normal structure. Corticomedullary definition and ratio (cortex 1/3 of medulla) were essentially maintained with some age-related loss of curvilinear patterns regarding the capsule and C/M junction. The cortices presented largely uniform texture with some increased echogenicity expected for his age patient. Medullary structure differed distinctly from that of the cortex and no evidence of pelvic dilation was present. Mineralization noted in both kidneys. The left kidney measured 3.02 cm. The right kidney measured 2.58 cm, slightly subnormal in size. Degenerative changes were mild to moderate on both kidneys. However, the kidneys do not appear end stage.

AGE

14 Years

Adrenal Glands

WEIGHT

7.1 Pounds

Both **adrenal glands** were visualized and recognized as having normal shape, size, position and echogenicity for this breed. The phrenic vasculature, glandular echogenicity and detail were unremarkable. Capsule, cortex, and medullary definition were normal for this age patient. The left adrenal gland measured 0.40 cm.

INTERPRETED BY

Eric Lindquist, DMV

DABVP, Cert. IVUSS

Spleen

The **spleen** presented a smooth homogeneous parenchyma hyperechoic to liver and renal cortical parenchyma. The capsule was smooth without noticeable expansion or deviation from within the spleen or adjacent pathology. The splenic vasculature demonstrated normal volume without signs of congestion or thrombosis. No sonographic evidence of acute or chronic inflammatory, neoplastic, or infarctual changes were noted.

IMAGING PERFORMED BY

Dr. Jenny Parrish

Liver

The **liver** images submitted revealed subjectively normal liver size, contour, and structure. Parenchymal echogenicity was naturally coarse and hypoechoic to the spleen. Vascular and biliary tracts were of normal volume with no evidence of congestion. The gallbladder presented acceptably thin walls with primarily anechoic content. The cystic and common bile ducts were normal. No pathological hepatic lymphadenopathy was evident. No overt structural evidence of inflammatory, infiltrative or regenerative pathology was evident.

HOSPITAL NAME

Local Mobile Vet

REFERRING VET

Dr. Jenny Parrish

Gastrointestinal

The **gastrointestinal tract** revealed minor variable thickening and echogenic submucosal changes most consistent with low grade end result of chronic GI disease such as IBD and may be related to malassimilation of nutrients if any weight loss is present. No obvious neoplastic patterns were noted and luminal content as unremarkable.

INVOICE

43838

DATE

12/29/22



PATIENT

Pancreas

Jitters Porter

The right limb of the **pancreas** was mildly hypoechoic and irregular. Enhanced surrounding mesentery noted.

SPECIES

ULTRASONOGRAPHIC FINDINGS

Feline

- Minor variable intestinal thickening
- Prominent irregular right pancreatic limb
- Moderate degenerative renal changes

BREED

INTERPRETATION OF THE FINDINGS & FURTHER RECOMMENDATIONS

DSH

No obvious evidence of neoplasia. Both prerenal and renal disease are likely playing a role in any history of azotemia, as the kidneys do not appear end stage. 72-hour IV fluid protocol indicated. Full thickness intestinal biopsies may be optimal. Recheck sonogram in 72-hours to ensure adequate resolution.

SEX

Spayed Female

Maldigestion panel, three view chest radiographs and full CNS examination is recommended to examine for occult disease that could be responsible for the weight loss. Evaluation for competitive eating environments should also be considered.

AGE

14 Years

WEIGHT

7.1 Pounds

INTERPRETED BY

Eric Lindquist, DMV

DABVP, Cert. IVUSS

IMAGING PERFORMED BY

Dr. Jenny Parrish

HOSPITAL NAME

Local Mobile Vet

REFERRING VET

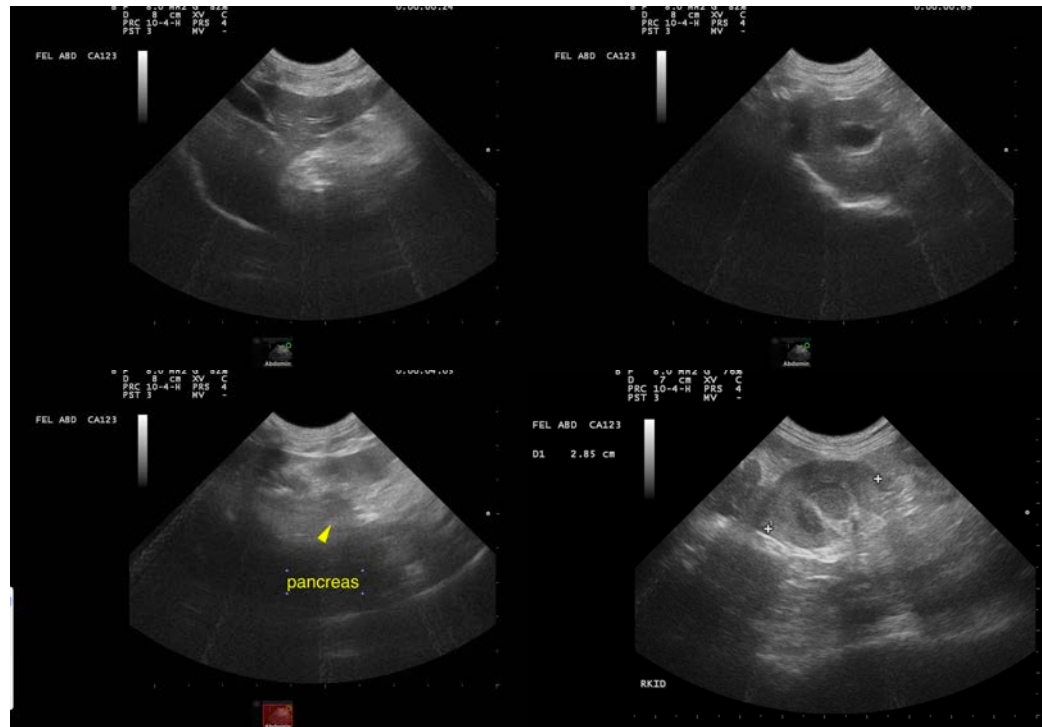
Dr. Jenny Parrish

INVOICE

43838

DATE

12/29/22





PATIENT

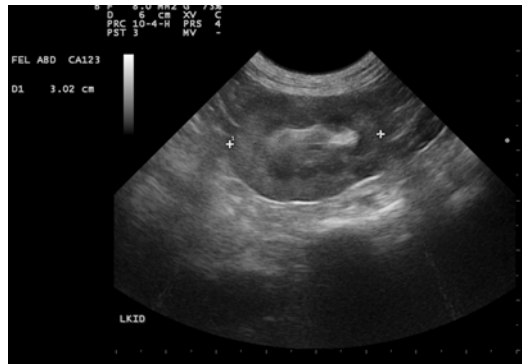
Jitters Porter

SPECIES

Feline

BREED

DSH



SEX

Spayed Female

AGE

14 Years

WEIGHT

7.1 Pounds

INTERPRETED BY

Eric Lindquist, DMV

DABVP, Cert. IVUSS

IMAGING PERFORMED BY

Dr. Jenny Parrish

HOSPITAL NAME

Local Mobile Vet

REFERRING VET

Dr. Jenny Parrish

INVOICE

43838

DATE

12/29/22

The information and recommendations provided are based on the images presented by the referring veterinarian/sonographer. No evaluation can be communicated regarding pathology that was not visible in the image/video clips provided.

Thank you for this referral. If the clinical or image interpretation does not parallel your findings or if I can be of any further assistance please contact me.

Eric Lindquist, DMV, DABVP, Cert. IVUSS, CEO of SonoPath.com

info@SonoPath.com